This is a digital copy of a book that was preserved for generations on library shelves before it was carefully scanned by Google as part of a project to make the world's books discoverable online.

It has survived long enough for the copyright to expire and the book to enter the public domain. A public domain book is one that was never subject to copyright or whose legal copyright term has expired. Whether a book is in the public domain may vary country to country. Public domain books are our gateways to the past, representing a wealth of history, culture and knowledge that's often difficult to discover.

Marks, notations and other marginalia present in the original volume will appear in this file - a reminder of this book's long journey from the publisher to a library and finally to you.

Usage guidelines

Google is proud to partner with libraries to digitize public domain materials and make them widely accessible. Public domain books belong to the public and we are merely their custodians. Nevertheless, this work is expensive, so in order to keep providing this resource, we have taken steps to prevent abuse by commercial parties, including placing technical restrictions on automated querying.

We also ask that you:

+ *Make non-commercial use of the files* We designed Google Book Search for use by individuals, and we request that you use these files for personal, non-commercial purposes.
+ *Refrain from automated querying* Do not send automated queries of any sort to Google's system: If you are conducting research on machine translation, optical character recognition or other areas where access to a large amount of text is helpful, please contact us. We encourage the use of public domain materials for these purposes and may be able to help.
+ *Maintain attribution* The Google "watermark" you see on each file is essential for informing people about this project and helping them find additional materials through Google Book Search. Please do not remove it.
+ *Keep it legal* Whatever your use, remember that you are responsible for ensuring that what you are doing is legal. Do not assume that just because we believe a book is in the public domain for users in the United States, that the work is also in the public domain for users in other countries. Whether a book is still in copyright varies from country to country, and we can't offer guidance on whether any specific use of any specific book is allowed. Please do not assume that a book's appearance in Google Book Search means it can be used in any manner anywhere in the world. Copyright infringement liability can be quite severe.

About Google Book Search

Google's mission is to organize the world's information and to make it universally accessible and useful. Google Book Search helps readers discover the world's books while helping authors and publishers reach new audiences. You can search through the full text of this book on the web at `http://books.google.com/`

EXCHANGE

SIGILLVM · VNIVERSITATIS · CALIFORNIENSIS
FIAT LVX
MDCCCLXVIII

EX LIBRIS

BIOLOGY LIBRARY

UNIVERSITY OF TORONTO STUDIES

Anatomical Series: edited by
Professor A. PRIMROSE

No. 1. THE ANATOMY OF THE ORANG OUTANG,

By A. PRIMROSE

UNIV. OF
CALIFORNIA

THE UNIVERSITY LIBRARY: PUBLISHED BY
THE LIBRARIAN, 1900

QL701
T6
no. 1-8
BIOLOGY
LIBRARY

COMMITTEE OF MANAGEMENT

Chairman: JAMES LOUDON, M.A., LL.D., President of the University.

PROFESSOR W. J. ALEXANDER, M.A., Ph.D.

PRINCIPAL J. GALBRAITH, M.A.

PROFESSOR A. H. REYNAR, M.A., LL.D.

PROFESSOR R. RAMSAY WRIGHT, M.A., B.Sc.

PROFESSOR GEORGE M. WRONG, M.A.

General Editor: H. H. LANGTON, B.A., Librarian of the University.

THE ANATOMY OF THE ORANG OUTANG

By A. Primrose, M.B., C.M., Edin.

(Professor of Anatomy in the University of Toronto)

BIOLOGY LIBRARY

EXCHANGE

LIBRARY OF THE UNIVERSITY OF CALIFORNIA

THE ANATOMY OF THE ORANG OUTANG
(SIMIA SATYRUS).

AN ACCOUNT OF SOME OF ITS EXTERNAL CHARACTERISTICS: AND THE MYOLOGY OF THE EXTREMITIES.

(Reprinted by permission from the Transactions of the Canadian Institute, 1898-99).

A brief note concerning the external features of the Orang Outang was read by me before the Canadian Institute on December 18th, 1897. Since that time I have had an opportunity of dissecting the animal, and of consulting the literature on the subject. I propose, in this paper, to give a detailed account of some of its external features, and then to deal at some length with the anatomy of the muscles of the extremities. The musculature in the anthropoid apes is of great interest when studied from the comparative standpoint, and in the Orang, which I have been fortunate in securing, some unusual conditions present themselves which make the enquiry of special interest.

The anatomy of the anthropoid apes has excited the interest of scientists for very many years. The old anatomist Tyson[1] described the Chimpanzee two centuries ago. Whilst his paper is entitled "The Orang Outang, or the Anatomy of a Pygmie," it would appear that the creature which he dissected was in reality a Chimpanzee. Many anatomists since the time of Tyson have been interested in the anatomy of the anthropoid apes, and the reason the subject possesses so much fascination for the scientific enquirer was well expressed by Owen[2] more than half a century ago, when he wrote: "In tracing the successive stages by which the lower animals approximate the structure of man, the interest increases as we advance, and becomes most exciting when we arrive at the highest term of the brute creation. At this point every deviation from the human structure indicates with precision its real

1 Edward Tyson, M.D., "Orang-Outang, sive Homo Sylvestris, or the Anatomy of a Pygmie compared with that of a Monkey, an Ape, and a Man." London, 1699.

2 Richard Owen, "On the Osteology of the Chimpanzee and Orang Utan." Transactions of the Zoological Society of London, Vol. I, 1835, p. 343.

M211330

UNIV. OF CALIFORNIA

peculiarities, and we then possess the true means of appreciating those modifications by which a material organism is especially adapted to become the seat and instrument of a rational and responsible soul."

Owen states that "the Orangs, or tailless apes of Africa and Asia, have long been recognized as the mammalia which make the closest approach to man; and their organization has therefore been studied with more or less care and detail by many distinguished physiologists and comparative anatomists." This statement indicates the interest which had been manifested in the study of the anthropoid apes, more than half a century ago.

In addition to the Orang Outang, the group of anthropoid apes includes the Gorilla and the Chimpanzee, which inhabit chiefly the west coast of Africa, and the Gibbon, which is found in the Indian Archipelago and some parts of the adjoining mainland.

The Orang Outang is found in the islands of Borneo and Sumatra. It would appear that the creature never attains a great size. Huxley remarks that there is no evidence that they exceed 4 feet 4 inches in height. On the other hand, Rudolf Fick states that Clark Abel is reported to have found a species of Orang in Sumatra which reached the height of two metres; this, however, Fick considers a gross exaggeration.

The specimen which I am about to describe was that of a young male animal (reproductions from photographs of the animal are published herewith). It measured 57 cm. in height. No history of its previous life and habits could be obtained. The shape of the cranium approaches, in many particulars, the human type. As has been pointed out by Hartmann[1] and others, the young apes approach more closely to the human type of skeleton than do the aged apes. Thus the great bony crests which are so characteristic of the skull of an aged male Gorilla are absent in young specimens. In all the smaller and middle-sized monkeys the general surface of the calvaria is oval and smooth, and remains so throughout life, whilst in the larger Baboons and Orangs there are well-marked supraorbital, sagittal, and occipital ridges.[2] These are said to attain their greatest development in the aged male Gorilla, where, as Flower asserts, they completely mask the original form of the cranium. In my specimen (a young animal) the surface of the cranium was perfectly smooth, and in this respect resembled the skull of a man, as there were no indications of crests.

It would appear, however, that the bony crests develop in connection

1 Robert Hartmann, "Anthropoid Apes." New York, 1886, p. 107.

2 W. H. Flower, "An Introduction to the Osteology of the Mammalia." London, 1885, p. 162.

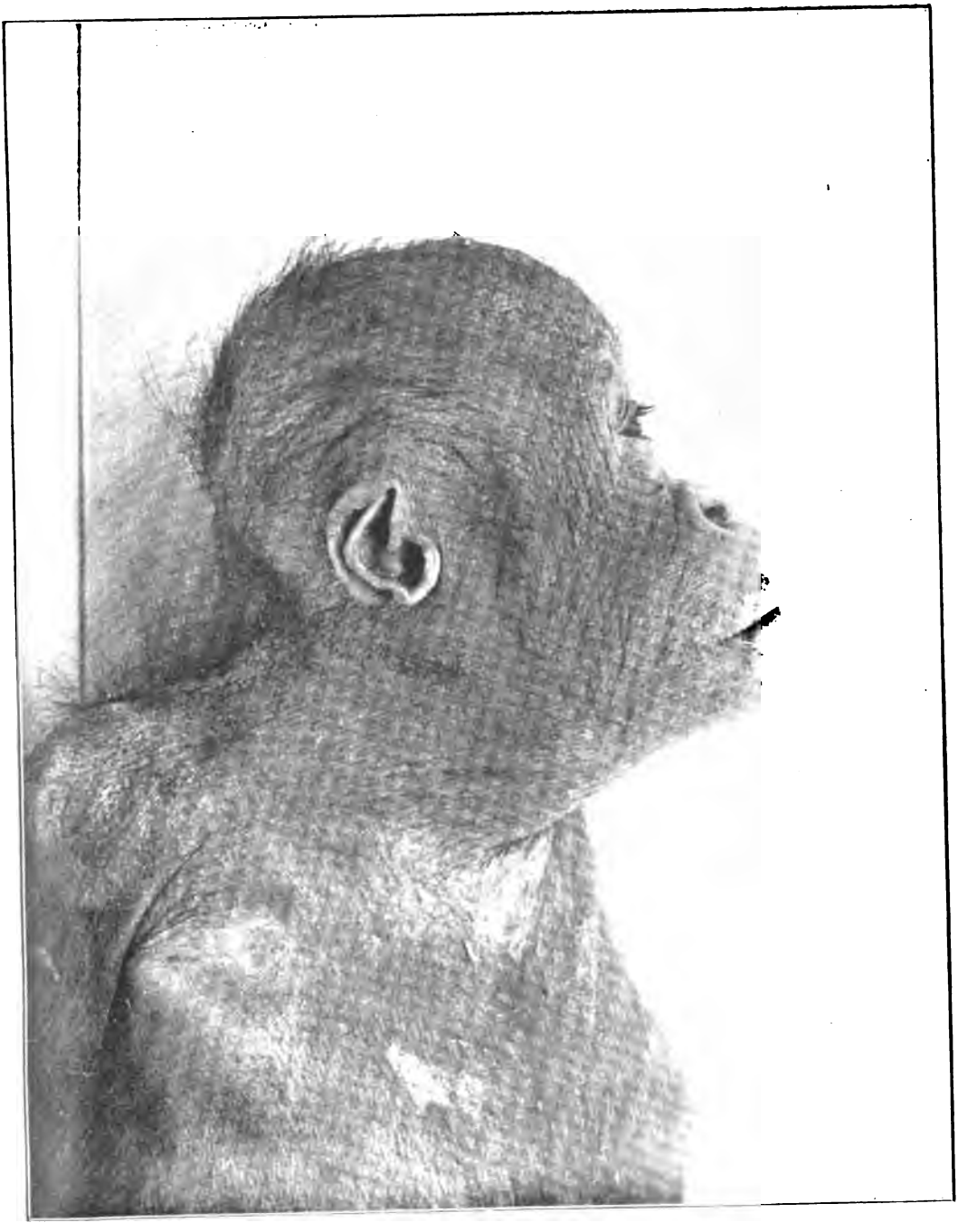

From a photograph of the Orang Outang, taken after death.

LIBRARY
OF THE
UNIVERSITY
OF CALIFORNIA

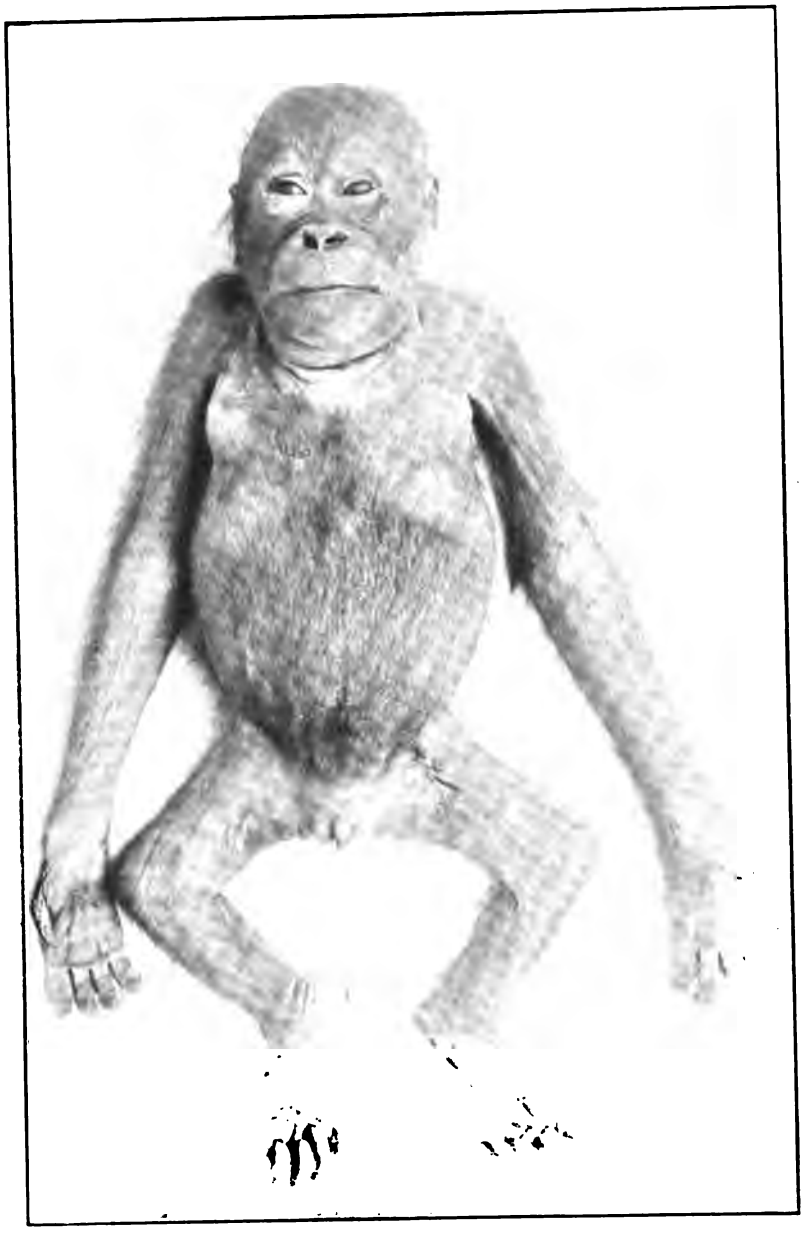

From a photograph of the Orang Outang, taken after death.

LIBRARY
OF THE
UNIVERSITY
OF CALIFORNIA

with the skull fairly early. Thus Delisle[1] observes that many crania exhibit well-developed sagittal crests, whilst as yet osseous union has failed to occur between the basioccipital and the basisphenoid. In man this union occurs about the twentieth year. Delisle describes the skull of an Orang, which exhibited this and other signs of youth, in which the crests were apparently in an early stage of development; the frontal crests, instead of uniting at the bregma to form the sagittal crest, passed backwards close to the superior border of the parietal bones, on each side of the sagittal suture, quite independently of each other, being separated by an interval of 2 cm. until they reached the occipital crest. This interparietal ridge may rise, according to Owen,[2] in the adult animal, to the height of one-third to two-thirds of an inch above the general surface. These crests give a massive appearance to the skull, but as Owen[3] long ago showed in his description of the skull of a Gorilla, the skull may be actually lighter than it is in man. This unexpected result is due to the greater size and extent of the air cells. Owen found that these extended in the Gorilla backwards from the tympanum, along the base of the occipital crests, as far as their junction with the parietal crest, and forwards also to the sphenoidal sinuses ; the frontal sinuses, and the antrum, were also developed to an unusual extent.

The dental formula in the Orang is similar to that of man. In my specimen none of the permanent teeth had as yet erupted, and the formula was as follows :—

$$\text{Milk teeth.....} \left\{ \; 1 \frac{2-2}{2-2} \; C \frac{1-1}{1-1} \; M \frac{2-2}{2-2} = 20 \right.$$

One finds that the dental formula in all the anthropoid apes is the same as that of man, and, in fact, such is the case in all the old world apes, with the exception of the Lemurs ; whilst, on the other hand, among the American apes there is considerable variation.

The lips are very wide and possess a wonderful degree of mobility. The mouth, in the living Orang, is said to be closed as a rule ; but, when the animal is taking food, the lips are used in a very curious

1 Delisle, "Sur l'ostéologie des Orang-Outans." Comptes Rendus de l'Académie des Sciences. Paris, 1894, Vol. CXIX, p. 241.

2 Loc. cit., p. 356.

3 R. Owen, "Osteological Contributions to the Natural History of the Chimpanzees, etc." Transactions of the Zoological Society of London, Vol. III, 1848, p. 412.

fashion. Thus, Fick[1] states that the lower lip may be protruded so as to form a kind of natural cup, so that if, for example, milk be given to the creature, he can fill this cup formed by the protruded lip, and then proceed to sip or lap the milk out of it. Darwin[2] refers to the protrusion of the lips in discussing the expression of the emotions in animals. He states that the lips of young Orangs and Chimpanzees may be protruded to an extraordinary degree; they thus act, not only when angered, sulky, or disappointed, but when alarmed at anything and likewise when pleased.

The eyelids are wrinkled, so that a series of grooves, parallel to the free margin, exists both in the upper and the lower lid. From the palpebral margin project well developed eyelashes. The eyes are never widely open in the Orang. They are placed very close together; Fick found, in the adult Orang that the pupils were only separated 5.7 cm., whilst in the emmetropic human eye they were separated 5.9 cm.

One of the most characteristic forms of expression in man is produced by the wrinkling of the forehead. Apparently the Orang does not possess this power to the slightest degree, although several observers have found the corrugator supercilii muscles present—muscles which produce the wrinkling of the forehead in man. It would appear, therefore, that the Orang has lost the power of using these muscles much in the same manner as man has lost the power of moving the ears. This lack of power of moving the auricle may be commonly noted in man, although the muscles in connection with it are developed. The facial muscles of expression in general in the ape are poorly developed in comparison with the same group in man. Bischoff is no doubt correct when he states that man differs from all animals, and from the highest apes very essentially, in the strong development and isolation of the facial muscles of expression. He concedes that the apes are excellent face-makers, but their emotions are expressed by distorting the whole face. The nose of the Orang is extremely short and depressed. There is no bridge and no point. The anterior nares look upwards and forwards. The shape of the ear in the Orang is remarkably like that in man. It possessed, in my specimen, the Darwinian pointed tip. This point, to which Darwin directed attention, consists of a small blunt process which projects inwards from the in-folded margin (the helix). In many monkeys the upper portion of the ear is slightly pointed, and the margin is not

1 Rudolf Fick, "Vergleichend anatomische Studien an einen erwachsenen Orang-Utang." Archiv für Anat. und Phys. Anat. Abth., 1895, p. 1.

2 Charles Darwin, "The Expression of the Emotions in Man and Animals." London, 1872, p. 140

3 Charles Darwin, "The Descent of Man." London, 1871, Vol. I, p. 22.

at all folded inwards. This condition, according to Darwin, occurs in monkeys which do not stand high in the order, as Baboons and some species of Macacus. When, however, the whole ear is pressed permanently backwards, and the margin is infolded, as in the higher apes, the point persists as the process mentioned. Darwin's point is found very frequently in the human ear, and whilst it is often absent in man, it is also not infrequently absent in the anthropoid apes.

In my specimen, the lobule of the ear was entirely absent. This peculiarity, too, is often found in man. The ears projected in a fairly well-marked fashion from the side of the head, although not more so than is the case in many human ears.

There was no prominence in the region of the chin in my Orang, and in this particular, it agrees with other anthropoid apes; in fact, the forward projecting chin may be looked upon as a fairly distinctive human characteristic; although Huxley states that in certain of the Gibbons (the Siamang) he found something approaching to a chin. He says, however, that this "is the only ape which has anything like a mental prominence." Again, Huxley remarks that whilst the chin in the European is either straight or projects beyond the level of the incisor teeth, in the lower races it retreats somewhat, although this recession appears greater than it really is, because of the prominence of the teeth.[2] In my Orang the recession of the lower jaw was such that a continuous curve was formed, which extended, without interruption, from the margin of the lower lip above to merge below in the outline of the neck.

The short thick neck of my Orang is a characteristic common to all anthropoids. The shortness of the neck is developed to a remarkable extent—to an extent seldom approached in man. It is due, not to shortness of the cervical spine, but, as Langer[3] has pointed out, to the shortness of the fibres of the levator scapulæ, and of the descending part of the trapezius muscles. The result is that the shoulders of the Orang are raised considerably above the level of the sternum, and the head seems to be sunken literally between the shoulders. This brings about an oblique position of the scapulæ, and a peculiarity of shape of these bones as compared with man.

---

1 Huxley, "The Structure and Classification of the Mammalia." The Medical Times and Gazette, Vol. I and Vol. II, 1864, p. 618.

2 Ibid. Vol. I, p. 309.

3 C. Langer, "Die Musculatur der Extremitäten des Orang als Grundlage einer vergleichend-myologischen Untersuchung." Sitz. der math-natur. Classe der kais. Acad. der Wissenschaften, Vol. LXIX, Wien, 1879, p. 178-9.

In the cheek of man there exists what is called the buccal fat pad. This is a circumscribed mass of lobulated fat lying upon the buccinator muscle and the anterior margin of the masseter muscle, closely surrounding the duct of the parotid gland. It is particularly well developed in the cheek of the infant, and has been called the "sucking pad" on account of its supposed function in connection with the act of sucking. Symington[1] has demonstrated the relations of this pad of fat in the cheek of the child, and has figured the pads as they appear in coronal section through the cheek. Ranke[2] states that the existence of this pad was first described by Heister in 1732, who, however, mistook it for a gland, and called it the "glandula molaris;" and later anatomists followed this erroneous view. Ranke showed that it was surrounded by a connective tissue envelope, through which it was connected to the underlying buccinator muscle, and that a deep process of the mass passed backwards and upwards into the spheno-maxillary fossa under the ramus of the jaw and the lower part of the temporal muscle. It was found well developed in a four months' old fœtus, and, while it persists throughout life, it is more noticeable as a well-defined structure in the infant. A peculiarity of this cheek pad is that, according to Ranke, it withstands the destructive processes which destroy the subcutaneous fat in many wasting diseases. Macalister[3] is apparently in error in making a statement to the contrary. These pads become unduly prominent when the neighbouring subcutaneous fat of the cheek wastes away. This sucking pad in my Orang was remarkably well developed. It formed an isolated mass completely separated from the subcutaneous fat, and presented all the features described as characteristic of it in the human infant.

In the Orang, as age advances, enormous masses of fat develop in the cheeks and in the neck. It is not certain whether or not these cheek pads are developed from the sucking pad already described—probably they are rather developed from the subcutaneous fat. At all events, in the old Orang, these later developments of fat attain great dimensions. They are fully described and figured by Fick.[4] According to his statement, they had not been previously described, but we find that Huxley[5] mentions them as occurring in an adult male Orang. The extreme

1 Johnson Symington, "The Topographical Anatomy of the Child." Edinburgh, 1887, p. 14.

2 H. Ranke, "Ein Saugpolster in der menschlichen Backe." Virchow's Archiv für path. Anat. und Phys., Vol. XCVII, 1884, p. 527.

3 A. Macalister, "A Text book of Human Anatomy." London, 1889, p. 566.

4 Loc. cit., p. 2.

5 Loc. cit., Vol. I, p. 564.

ugliness of the old Orang is largely due to the existence of these cheek and neck pads. They form on each cheek semi-lunar appendages covered by the skin. In the dead Orang, Fick described them as triangular in shape. The free apex of the triangle was at the level of the malar bone, whilst the attached base of the triangle extended from the top of the frontal bone downwards to the lower margin of the lower jaw and face. Fick suggests that it occurs only in old age and in the male sex. These masses of fat are, to some degree, mobile; and Fick figures an Orang lying asleep, in which the cheek pad having fallen forwards, forms a cushion for the creature to rest its head upon. A similar development of fat occurs in the neck of the old Orang. Deniker and Boulart[1] describe similar voluminous pads of fat in the Orang—one 6 cm. thick, extended under the occiput and the nape of the neck; two others, in the form of semilunar crests 18 cm. long and 11 cm. wide existed on the side of the face and upon the jaws, and gave the animal a most singular appearance. This development of fat in the Orang appears to be connected with the age of the animal, and Fick suggests that it is comparable to the accumulation of fat which is apt to occur in man after a certain age is reached.

In my Orang there were no such free appendages of fat, but a mass of fat existed beneath the jaw, extending down over the hyoid bone and the larynx. Embedded in this were two thin walled sacs which were found to communicate with the air passages. They were in fact diverticula from the larynx, and were pyriform or egg shaped, attached above in the neighbourhood of the thyro-hyoid membrane; they diverged from one another, passing out under the sterno-hyoid muscles and after appearing in the neck on either side at the posterior border of this muscle, they came forwards towards the middle line. The sac upon the left side measured 5 cm. in its long axis and 2.3 cm. in its greatest width. The right sac measured 2.5 cm. long and 1.5 cm. wide. The sacs were very readily separated from the mass of fat in which they were embedded. It would appear that these sacs occupied an unusual position in my Orang in their relations to the muscles. In the descriptions which I have been able to consult they are figured as appearing in the middle line of the neck between the infra-hyoid muscles, whilst in my Orang they passed out behind these muscles and appeared at the posterior border of the muscles in the manner described. It is in the median position that Vrolik[2] describes and figures them in the Chimpanzee, as do also Deniker and

1 J. Deniker and R. Boulart, "Sur divers points de l'Anatomie de l'Orang-Outan." Comptes Rendus de l'Academie des Sciences. Vol. CXIX, 1894, p. 236.

2 W. Vrolik, "Recherches d'Anatomie comparée sur le Chimpansé," Amsterdam, 1841, p. 44 and plate 2.

Boulart[1] in the Orang. In former descriptions it has been assumed that these sacs are found only in the older animals; the great development of them in my young specimen disproves this statement. It would seem that they are seldom developed symmetrically, but one sac is always larger than the other. This disparity in size may be great; thus Deniker and Boulart found in one Orang the left sac measured 11 cm. long, whilst the right sac in the same animal was only 41 mm. The larger sac also often overlaps the smaller, and may completely conceal it lying in the middle line of the neck; this probably accounts for the circumstance that some anatomists have been led to describe the sac as a single azygos structure. Careful search in cases where the sac appeared single has led to the discovery that both sacs were present, one being of very diminutive proportions. Huxley[2] describes the great development of these sacs in a Gorilla in the following terms:—"The larynx in its general characters resembles that of man and the Chimpanzee; connected with it in the adult Gorilla is a system of great cavities, developments of the two laryngeal sacculi, each of which is equally dilated, and produced into large caecal sacculated pouches, extending all over the sides of the neck in the interspaces between the muscles, from the rami of the lower jaw to the axillae. As age advances the sacs of the two sides coalesce in the middle line over the trachea, and form an elongated bag, the upper end of which fits into the hollow of the body of the hyoid bone. The use of this immense and complex apparatus" Prof. Huxley adds "is not known."

The most extensive development of the laryngeal pouches is found in Duvernoy's description of the Gorilla.[3] In an adult male Gorilla a large median portion situated in the middle line of the neck was found, from which three pairs of lateral prolongations passed. Two superior ones, one on either side, passed upwards behind the angle of the lower jaw, passing back beneath the sterno-hyoid, the omo-hyoid and the sterno-mastoid muscles; these superior branches of the median sac had the most direct communication with the ventricles of the larynx into which they opened, immediately between the hyoid bone and the thyroid cartilage. These two superior branches also communicated each by a large aperture with the great median sac which descended anteriorly over the thorax and gave off a second and a third pair of lateral branches, with each of which its cavity freely communicated. The second pair (median)

1 Deniker and Boulart. "Les Sacs Laryngiens des Singes anthropoides," Journal de l'Anatomie et de la Physiologie, Paris, 1886, p. 51.

2 Loc. cit., Vol. I, p. 538.

3 M. Duvernoy, "Des caractères anatomiques des grands singes pseudo-anthropomorphes," Archives du Museum d'Histoire Naturelle, Paris, 1855-56, pp. 201, 202, 203.

descended to meet the clavicle, lying over its upper border as it passed outwards beneath the sterno-mastoid muscle to the upper part of the shoulder. The third (inferior) pair were by far the largest. They appeared to be derived as a bifurcation of the great median sac at its lower extremity. They extended downwards among the muscles of the anterior wall of the chest, each branch passing out laterally under the clavicular portion of the deltoid and downwards under the tendon of the great pectoral muscle and, whilst under this, insinuating itself between the two portions of the small pectoral muscle (superior and inferior) into which that muscle divided in the animal, passing even to the axilla, and lying there upon the lateral wall of the chest.

Huxley[1] in his description of the Orang states that the laryngeal saccules attain still more enormous dimensions in the adult than in the Gorilla; he describes them as constituting a great median bag covered by a strong layer of muscular fibres from the platysma and sending caecal prolongations backwards beneath the trapezius muscle as far as the occiput, beneath the scapula and into the axilla. The cavity communicated by two distinct canals with the ventricles of the larynx. Huxley tells us that among the Gibbons there is only one species—the Siamang—in which a laryngeal pouch at all similar to that found in the other anthropoids exists. One finds a description of laryngeal sacs in the Chimpanzee by Gratiolet and Alix[2] in which the left pouch extended down between the sterno-mastoid muscles a centimetre beyond the upper margin of the sternum. Cunningham determined the relations of the laryngeal sac in a Chimpanzee and in an Orang by means of frozen sections. In the Chimpanzee it extended downwards in front of the sternum to the lower border of the manubrium; it stretched in an upward direction until it reached the hollow posterior surface of the hyoid bone. In the Orang the laryngeal pouch, although it was prolonged down to the top of the sternum, was not continued on to the anterior aspect of that bone.

The occurrence of these sacs in the lower apes has been mentioned by Huxley, who found that among monkeys and baboons of the old world the sacs exist in many species; they are not a development of the laryngeal ventricle in these animals, however, but grow out from the thyro-hyoid membrane, and have only a single aperture of communi-

1 Loc. cit., Vol. I, p. 596.

2 Gratiolet and Alix, "Recherches sur l'Anatomie du Troglodytes Aubryi," Nouvelles archives du Museum d'Histoire Naturelle, Paris, Vol. II, 1866, p. 232.

3 D. J. Cunningham, "The Topographical Anatomy of the Chimpanzee, Orang-utan and Gibbon," Cunningham Memoirs, Royal Irish Academy, 1886, p. 138.

cation with the laryngeal cavity. In the apes of the new world some extraordinary variations occur in the development of these air sacs. In the spider monkey (Ateles) Huxley describes a single median sac which is developed at the back of the trachea, opening into the air passages between the upper ring and the cricoid cartilage. Then, again, in the howling monkey (Mycetes), according to the same authority, the hyoid and the laryngeal apparatus is exceedingly developed and modified. "The body of the hyoid bone is expanded into a great rounded drum with thin osseous walls, the larger cornua projecting backwards from it, though the lesser pair are quite obsolete. The thyroid cartilage is also exceedingly large, and the epiglottis undergoes an extraordinary development and changes in form. The cavity of the glottis presents several prolongations; one long and narrow tube in front communicates with the chamber in the body of the hyoid bone, the two lateral sacculi are prolonged upwards on each side, and are only separated from each other above the larynx by a thin membranous septum, and in some species there is, in addition, a small inferior pair of sacs."[1] The howling monkey, as its name implies, is capable of uttering loud and discordant sounds, and no doubt the complicated apparatus just described has something to do with the production of these sounds. It is difficult to understand how the mechanism acts, and I am not aware that anyone has succeeded in solving the problem.

I have thus given an account of the laryngeal sacs as they are found in the anthropoid apes and in apes lower in the scale. They are undoubtedly developed in connection with the laryngeal ventricles, structures which are present in the human larynx. These ventricles—the "ventricles of Morgagni"—lie in the lateral walls of the larynx, one on each side. The ventricle may be described as a recess which exists between the false cords above and the true cords below; it there forms a diverticulum from the lateral wall of the larynx, presenting an elliptical opening, the length of which is a little shorter than the true cords. The ventricle is about 5 mm. in depth, and, in man, from the anterior part a secondary diverticulum proceeds, the so-called "laryngeal pouch" which extends upwards for about 12 mm. towards the upper border of the thyroid cartilage; it is apparently this laryngeal pouch which assumes such enormous proportions in the Orang. According to Testut[2] this pouch is sometimes found considerably enlarged in man; whilst it usually terminates at the upper border of the thyroid cartilage, it may proceed upwards as high as the hyoid bone, or even sufficiently high to appear under the mucous membrane of the base of the tongue.

1 Loc. cit. Vol. II, p. 123.

2 L. Testut. "Traité d'Anatomie humaine," Troisième édition, Paris, 1895. Vol. III, p. 259.

The function served by the laryngeal sac, as I have said, is a problem not yet solved. Fick observed a slight bellowing of the sac in the Orang when the animal was howling, and he also noticed a slight blowing up of the sac in the second or expiratory act of yawning. In coughing, on the other hand, no effect was noticed upon the sac. Sandifort long ago suggested that the sac permitted the storing up of air which was brought into use in prolonging the loud roar of the animal, but, as Huxley pointed out, the position of the sac above and not below the vocal cords is inconsistent with this theory.

The great length of the arms in the Orang is a striking feature in comparing the animal with man. The lower extremities in man exceed the upper in length; the reverse is true of the Orang. The measurements in my orang were as follows:

Upper extremity	46 cm.
Lower extremity	24 cm.

The measurements were taken in the case of the upper extremity from the tip of the shoulder to the end of the middle finger, and in the lower extremity from the perineum to the heel, thus following, for the sake of comparison, the method adopted by Fick. We find, therefore, that the upper extremity measured 80.7 per cent. of the total length of the body, whilst the lower extremity measured 42.1 per cent. of the height. The following table will give the percentages in a comprehensive manner, the figures indicating percentages of the total length of the body from the head to the heel:

	Upper Extremity.	Lower Extremity.
The present specimen of the Orang	80.7%	42.1%
Fick's Orang "Jumbo"	75.2%	38.3%
Fick's Orang "Anton"	73.6%	37.9%
Man	45 %	47.5%

Fick's measurements were taken from adult animals, whilst my Orang was quite young.

The remarkable elongation of the upper extremities in proportion to the body length is not characteristic of the Orang only, but of all the anthropoid apes. In the Gibbon this feature is even more marked than in the Orang or than in all other apes. It is interesting to note in this connection that the arms of negroes are proportionately longer than in the white races, this being, however, chiefly due to the increased length of the hand and forearm. Huxley tells us that the native Australians and other low races resemble the negro in this respect. One must note also that in this peculiarity anthropoid apes differ in a marked degree from

the lower apes. Thus, in the lower apes, with very few exceptions, one finds that the lower extremities exceed in length the upper. In the Lemurs the hind limbs exceed the fore limbs to a very marked degree.

The hind limbs of the Orang are always bent; it is impossible to straighten them completely. This is mainly due to the arrangement of the muscles at the hip and the knee. On the other hand, the fore limbs may be straightened out perfectly. I leave for consideration in another part of this paper the question as to whether the Orang is four handed or not, but in the meantime I shall speak of the "hand" of the fore limb, and the "foot" of the hind limb. The hand of the Orang is very much longer and narrower than the human hand. This is largely due to the great elongation of the metacarpal bones, but, in addition, the phalanges too are proportionately longer than they are in man. Fick states that the Orang grasps things by preference with the right hand, and that in all other manipulations they are decidedly right handed, as is common in most apes. The thumb is very short and rudimentary; it does not project as far as the head of the metacarpal bone of the index finger, and the ball of the thumb can hardly be said to exist. Much more remarkable, however, is the foot of the Orang. Like the hand, it is very long and narrow, but it has a well developed opposable hallux and is evidently modified as a grasping organ. The four outer toes are greatly elongated and remain separate, so that they resemble the fingers of a hand rather than the toes of a foot. It would appear that the Orang never stands erect without some support from the arms. Thus it may stand upright whilst it supports itself by grasping the limb of a tree overhead, or it may rest the fore limbs on the ground. Mayer[1] and others have observed that whilst resting on the fore limbs the Orang, like other quadrumana, does not place the palm of the hand on the ground when walking, but rests upon the outer margin and the back of the wrist and fingers. Whilst standing the foot is supinated and the toes bent, the foot resting upon its outer margin. This differs from the Gorilla, which is able to stand erect without the support of the arms, and is capable also of bringing the sole of the foot to the ground.

The lines upon the integument of the palm of the hand and of the sole of the foot in the Orang may be compared with the markings which exist upon the integument of the human sole and palm. If the palm of the hand in man be examined (see photograph) one may readily observe that the markings upon the palmar aspect of the fingers themselves are

1 Mayer. . . "Zur Anatomie des Orang-Utang und des Chimpanse." Archiv für Naturgeschichte, Berlin, 1856, p. 285.

MICROFILMED

From a photograph of the palm of the hand of an adult man, showing the markings on the palm of the human hand.

From a photograph of the palm of the hand of the Orang Outang, showing the markings on the integument of the palm.

UNIV. OF CALIF.

UNIV. OF
CALIFORNI

obviously associated with the flexion or bending of the digits, the grooves existing opposite the joints at which the movement in question takes place. These grooves are converted into deep clefts when the fingers are fully bent. In the palm proper, similar markings on the skin are observed. Two very noticeable ones run almost parallel to one another from near the base of the index finger inwards towards the inner border of the palm. These grooves are about 1 cm. distant from each other. They do not run transversely across the palm, but their course is very oblique, the inner extremity of each line being much nearer the wrist than the outer extremity. These markings are associated with the flexion of the fingers upon the palm, and are converted into deep fissures when the fingers are folded in upon the palm. Certain markings run in a more longitudinal direction. These begin near the wrist. One is clearly associated with the movements of the thumb towards the palm; it curves forwards from the mid-point of the wrist, around the base of the ball of the thumb, to terminate on the outer border of the palm, sometimes joining the nearer of the two oblique lines already described. This curved line is converted into a cleft when the thumb is opposed to the palm or to the other digits; it is therefore clearly associated with the movement of opposition of the thumb to the palm or the other digits. Other longitudinal markings are associated with the adduction or abduction of the fingers. Occasionally the ball of the little finger is also marked off by a more or less distinct curved line.

Now, if we compare the foregoing with the markings which are observable in the photograph of the palm of the hand of our Orang (see reproduction of photograph) we find a corresponding series of markings. We notice, however, that the ball of the very rudimentary thumb in the Orang is not developed to anything like the proportions attained in man. The curved line at the base of the thenar eminence is present, but what is more marked is the cleft which indicates *adduction* of the thumb rather than *opposition*. Then one observes a very marked difference in the markings running across the palm. These are remarkable in being transverse rather than oblique in direction. We observe also certain less clearly marked longitudinal lines associated with adduction and abduction of the fingers. Let us now consider the significance of the difference in the markings in the human hand compared with those of the Orang. Professor Goodsir, of Edinburgh, long ago[1] well indicated a distinctive difference between the hand of man and that of the ape when he stated that the hand of man could grasp a sphere whilst the hand of the ape could grasp a cylinder.

1 "Goodsir's Anatomical Memoirs." Edited by Prof. Wm. Turner, Edinburgh, 1868, Vol. I, p. 239.

Clearly the oblique grooves in man indicate that the fingers are not bent in a perfectly straight direction into the palm, but are directed somewhat obliquely towards the thumb, hence the line associated with that movement of flexion is oblique, in other words it is at right angles to the line of movement—the fingers are opposed to the thumb. In the Orang, on the other hand, the fingers are flexed directly into the palm, and the animal is thus better able to grasp a cylindrical object, such as the branch of a tree, whilst it is not so well adapted to grasp a sphere, as the hand of man. The development of the ball of the thumb in man is due to the presence of a well-developed group of muscles which have to do with adduction and opposition of the thumb. These muscles are by no means so well developed in the hand of the Orang. It must be noted, however, that the groove of opposition is present in the Orang, and that the feeble thumb can be opposed. In the Orang, too, there is a marking off of the ball of the little finger; this is sometimes, but not always, present in the hand of man.

One would readily suppose that the lines in the palm of the hand were produced after birth when the muscles of the hand had brought about the various movements, but such is not the case. Professor Sir William Turner[1] makes an interesting observation regarding this when he says: "These grooves are present in the infant's hands at the time of birth; and I have seen them in an embryo, the spine and head of which were not more than 90 mm. (three and a-half inches) long. They appear in the palm months before the infant can put its hand to any use; though it is possible that the muscles of the thumb and fingers do, even in the embryo, exercise some degree of action, especially in the direction of flexion. These grooves are not, therefore, acquired after birth. It is a question how far the intra-uterine purposeless movements of the digits are sufficient to produce them; but even, should this be the case, it is clear that they are to be regarded as hereditary characters transmitted from one generation of human beings to another. They are correlated with the movements of the digits, which give the functional power and range of movement to the hand of man."

It may be remarked here that the grooves on the palm differ somewhat in the different anthropoid apes; thus Hepburn[2] shows that the lines across the palm in the Gorilla are decidedly oblique, and the hand

1 W. Turner, "Some Distinctive Characters of Human Structure," Report of the British Association for the Advancement of Science, 1897, p. 768.

2 David Hepburn, "The Integumentary Grooves on the Palm of the Hand and the Sole of the Foot of Man and the Anthropoid Apes," Journ. of Anat. and Phys., Vol. XXVII, 1892-93, p. 112.

of the Gorilla in this respect more closely resembles the hand of man than does the hand of the Orang.

The great length and narrowness of the hand has been referred to; it is quite obvious, however, that the fingers of the Orang are disproportionately short as compared with the greatly elongated palm. The cause of this is demonstrated by Langer[1] in his dissection of an interdigital membrane which spreads out over the upper fourth of the proximal phalanx of the four inner digits. This membrane is not present in man, and in the Orang, therefore, more of the proximal phalanx is sunken into the palm than is the case in man. The result is that the fingers of the Orang appear proportionately short. Another effect will be observed by reference to the photographs here reproduced, namely, that the integumentary grooves are further separated from the interdigital clefts in the Orang than they are in man.

Dr. Blake,[2] in his observations on the study of the hand for indications of disease, has noted the remarks made by Dr. Harry Campbell regarding the curious resemblance between the acquired bone and skin changes in the acromegalous subject, and the condition normal in the hand of the Gorilla. It would appear that many of the morbid changes in this disease bring about conditions of the character referred to, and Blake would view such as examples apparently of reversion to a primitive arboreal type. Whilst I am not prepared to seriously entertain this idea, there is no doubt of the fact, at all events, that in this disease the hand of man comes to present a curiously close resemblance, in appearance, to the hand of the Gorilla.

Turning now our attention to the markings in the sole of the foot, we find that in the human foot these are largely obliterated after the individual has walked about, and pressure has been brought to bear upon the sole, the skin becoming as a result thick and indurated. Some interesting observations on these integumentary markings, as they appear in the foot of the infant, have been made by Dr. Louis Robinson[3] in the "Nineteenth Century." He looks upon the markings on the infant's foot as giving some evidence of the evolution of the human foot from a structure which at one time was able to grasp an object after the manner of the human hand or the foot of an anthropoid ape. Robinson states that these lines are scarcely visible at fourteen months and are only present in a few cases after two years of age,

1 Loc. cit., pp. 182 and 185.

2 Edward Blake, M.D., "On the Study of the Hand for Indications of Local and General Disease," London, 1889, p. 36.

3 Louis Robinson, M.D., "The Meaning of a Baby's Footprint." The Nineteenth Century, Vol. XXXI, 1892, p. 795.

whilst in the adult they disappear. I have, however, photographed the sole of a child's foot aged nine years (see reproduction of photograph), and find well marked all the lines described and figured by Robinson in the foot of the infant. I shall proceed to describe these lines and to enquire into their significance. In the child of nine years one is able to distinguish the lines which correspond to the oblique lines across the palm. In comparing the foot with the hand, however, one must bear in mind that the great toe (unlike the thumb) is parallel in position to the other digits, and that its metatarsal bone is closely united to the other digits by an extension of the transverse metatarsal ligament, whilst in the hand there is no such connection of the metacarpal bone of the thumb to the index finger. The hallux is therefore not free to move about in the manner characteristic of the thumb. Moreover the hallux cannot be opposed to the sole or to the other digits, and if we examine the musculature in man we find there is no opponens hallucis. On examining the markings in the sole of the foot of the child (see photograph) we find a line strongly curved starting at the inner border of the foot at the base of the first digit, and passing outwards and forwards to terminate immediately external to the cleft between the first and second digits, its point of termination separated 1.5 cm. from that cleft. This line marks off what is commonly called the ball of the great toe, but observe that the so-called ball of the great toe does not correspond with the ball of the thumb, in that the soft structures forming the ball of the great toe are related to the plantar aspect of the proximal phalanx of that digit; whilst the ball of the thumb is formed by structures related to the palmar aspect of its metacarpal bone. This curved marking in the sole is therefore opposite the metatarso-phalangeal joint, and corresponds to the marking on the palmar aspect of the thumb opposite the metacarpo-phalangeal joint of that digit, and not to the curved marking at the base of the thenar eminence. This curved line in the sole therefore is produced by flexion of the hallux at the metatarso-phalangeal joint. If we look for any marking in the sole produced by opposition or adduction of the great toe in man we look in vain. There is no such marking, and therefore the characteristic mark found in the palm bounding the thenar eminence is wanting in the sole. We find, however, a curved line across the sole beginning at the base of the second digit and running at first somewhat longitudinally for a short distance and then curving outwards to end at the outer border of the foot. This curved line is often interrupted in the sole, but can always be readily distinguished. It is frequently spoken of as limiting the ball of the little toe, but it too is opposite the metatarso-phalangeal joint and is therefore merely an indication of the flexion of the smaller toes at that

From a photograph of the sole of the foot of a girl nine years of age, showing the markings on the sole of the human foot.

From a photograph of the sole of the foot of the Orang Outang, showing the markings on the integument of the sole.

UNIV. OF
CALIFORNI

point. It frequently joins the curve described at the base of the great toe. The great obliquity of this groove in the human foot is due not to the fact that the toes flex towards the great toe (compare the description of the hand) but to the fact that the metatarsal bones of the toes become progressively shorter as we proceed to the fifth digit, the groove in question lying over the heads of the metatarsal bones.

Let us now compare the foot of the Orang with that of man. The markings in the sole of the foot in the Orang are more distinct than in man because the animal does not obliterate them in walking, during which the outer margin of the foot alone comes to the ground; the outer margin is in consequence smoother than the remaining portion of the sole. We are at once struck by the great length of the four outer toes, they are long, and are separated from one another so as to resemble fingers rather than toes. The great toe in the Orang's foot, however, presents a remarkable difference from the hallux in man. Thus in the Orang it is very much shorter than the other toes, and its long axis forms a marked angle with the long axis of the remaining part of the foot. It is capable in fact of being placed at right angles to the long axis of the sole. The metatarsal bone of the great toe is not connected by a transverse metatarsal ligament to the second digit, and in this respect also differs from the human foot. The ball of the great toe in the Orang (as observed in the photograph) is marked off by a well marked groove, but this groove is not opposite the metatarso-phalangeal joint but opposite the tarso-metatarsal joint and marks off the mass of muscular tissue which lies in relation to the plantar aspect of the metatarsal bone. In other words the line is associated with adduction and opposition, and in this respect entirely corresponds to the line described in connection with that movement in the human hand or in the hand of the Orang itself. The lines running across the sole at the bases of the other digits are oblique and very similar in their position and characteristics to those observed in the palm of the hand. The obliquity here may partly be accounted for by the gradual diminution in length of the digits as we proceed from the second to the fifth digits, but is also accounted for by the fact that the Orang flexes its toes not directly into the sole, but somewhat towards the hallux, the mark being at right angles to the line of movement in flexion. The lines corresponding to the flexion of the digits themselves are well marked opposite the metatarso-phalangeal and the interphalangeal joints. Note that in the Orang the line indicating flexion of the hallux at the metatarso-phalangeal joint is well marked, but is separated from the sole proper and lies upon the plantar aspect of the hallux itself, differing thus in its position and

relation to the sole as compared with the condition on the human foot but nevertheless corresponding to the curved line at the base of the so-called ball of the great toe in man. A few longitudinal grooves are observable on the sole of the Orang; these are due to adduction of the digits towards one another.

It will thus be observed that in studying the foot of the Orang it bears more resemblance to a hand than a foot. In fact as an instrument for grasping objects it is much more serviceable than the hand of the same animal. The hallux is more strongly developed than the pollex, and the movements of opposition and adduction are much more strongly carried out by the foot than by the hand. The Orang could grasp a sphere with the foot much more readily than with the hand. If, therefore, we were to restrict our considerations to the markings in the integument, as indicating the use to which the member is put, we might be led to conclude that the posterior extremity of the ape ended in a hand and not in a foot. On the other hand, as we shall observe later, when we proceed to describe the dissection of the creature we shall be forced to admit that morphologically the structure in question is a foot and in no sense a hand. We shall take an opportunity of referring again to this subject after the anatomy of the soft parts has been described.

Concerning the manner in which the Orang uses its hands and feet in progression one may quote Huxley's remarks. He says: "it very unwillingly assumes the erect posture, perhaps never in its native haunts. When it walks upon the ground it swings itself along by its very long arms as with crutches, not resting exactly on the knuckles, as the great African apes, but with the inner edge of the index finger on the ground and the thumb spread out. The hind foot does not come flat to the ground, but rests upon its outer edge with the toes close together and curved. Even when passing from bough to bough of the trees among which its life is chiefly spent, it observes a remarkable slowness and caution in its movements."[1]

THE MYOLOGY OF THE EXTREMITIES.

The *Trapezius* arose from all the dorsal spines, from the ligamentum nuchae and, by an origin 2 cm. wide from the occipital bone. It was inserted into the outer third of the clavicle, the acromion process and

1 Loc. cit. Vol. I, p. 564.

2 My colleague, R. D. Rudolf. M.D., Edin., dissected the right side of the Orang, and noted in detail the connections and relations of the muscles of the fore and the hind limbs. I have noted throughout my paper those points in which Dr. Rudolf's account differed from the results obtained by me in the dissection of the left side of the animal.

the spine of the scapula. A branch of the spinal accessory nerve was traced to the muscle. The shortness of the fibres of the trapezius muscle in that part of it which extended from the spine of the scapula to the occiput, and also of the fibres of the levator anguli scapulæ, has already been noted as accounting to some extent for the shortness of the neck in the Orang.

The *Latissimus dorsi* arose from the spines of the lower four dorsal vertebræ and the supra-spinous ligament, also from the lumbar aponeurosis and from the iliac crest extending as far forwards as the anterior superior iliac spinous process. There was thus no "triangle of Petit" as the latissimus dorsi overlapped the external oblique muscle of the abdominal wall at its insertion into the iliac crest. The muscle was inserted into the humerus in front of the teres major, but at a somewhat higher level than that muscle. From the latissimus dorsi, near its insertion, there arose from its tendon a strap-like muscle band (1.5 cm. wide), which proceeded down the arm to be inserted into the fascia attached to the internal condyle and the supra-condyloid ridge of the humerus. This has been called by Bischoff the *Latissimo-condyloideus*. Another muscular slip derived from the latissimus dorsi passes on a plane posterior to the main part of the muscle, and also behind the slip passing to the internal condyle, to be inserted along with the lower part of the teres major muscle into the humerus. This slip to the teres major muscle was found by Hepburn[1] in both the Chimpanzee and the Orang. The latissimo-condyloideus or *Dorso-epitrochlearis*, as it has been designated by some authors, occurs in all apes, not only in anthropoid apes, but in all apes lower in the scale. It is therefore a characteristic muscle of the ape and is always present in these creatures, whilst in man it is absent, or only occurs occasionally in a very rudimentary form. Thus in man one finds that a muscular slip is occasionally given off from the latissimus dorsi and passes downwards to the long head of the triceps, to the fascia, or to the internal intermuscular septum of the arm (Quain[2]); this, it is claimed, corresponds to the latissimo-condyloideus of the ape.

The *Rhomboideus* muscle in the Orang formed a continuous sheet arising from the dorsal spine as low as the sixth vertebra, and from the ligamentum nuchae, also receiving a very definite slip of origin from the occipital bone—the occipital attachment was 2.5 cm. wide. This occipital portion, although showing a continuous line of origin with the part

1 David Hepburn, "The Comparative Anatomy of the Muscles and Nerves of the Superior and Inferior Extremities of the Anthropoid Apes," Journ. of Anat. and Phys., Vol. XXVI, 1892, p. 152.

2 "Quain's Elements of Anatomy," edited by Schäfer and Thane, Vol. II, part 2, 1892, p. 205.

arising in the middle line of the back, was somewhat separated from the latter by a narrow interval, which is indicated in the drawing (plate III, fig. I, *rhom*). The two portions, occipital and spinal, united to form a continuous insertion into the whole of the vertebral border of the scapula, the upper part lying on the dorsal aspect of the levator anguli scapulæ where the latter muscle was inserted into the scapula. The occipital origin is not constant in the Orang, as Fick[1] found that in his specimen the muscle did not arise higher than in man. On the other hand, Bischoff, Owen and others have described an occipital origin in the Orang, and it appears to occur also in the lower apes. Macalister failed to find it in a young female Gorilla dissected by him. There was no occipital attachment described by Duvernoy in the Gorilla.[2] In man one finds that the occipital attachment occurs as an occasional variety.

The *Levator anguli scapulæ* (plate III, fig. I, *l.a.s.*), arose by three slips from the transverse processes of the upper three cervical vertebræ, and was inserted into the upper angle of the scapula and into its vertebral border, lying there in the deep aspect of the rhomboid muscle. At its insertion it was closely incorporated with the serratus magnus muscle. In an Orang dissected by Fick[3] the origin of the muscle extended as low down as the transverse process of the seventh cervical vertebra.

The *Serratus Magnus* arose by eleven digitations from the upper eleven ribs, taking its origin from the anterior extremities of the osseous ribs, and in its lower portion interdigitating with the external oblique muscle of the abdomen. It passed backwards to be inserted into the whole of the vertebral border of the scapula, blending there with the levator anguli scapulæ as already described.

The two muscles last described are closely related to one another; it will be observed that when the levator anguli scapulæ arises from the complete series of cervical vertebræ (as in Fick's Orang), the muscle becomes necessarily almost continuous at its origin with the serratus magnus, and as we have already observed they are united at their insertion. Thus an almost continuous sheet of muscle is formed. In man the muscles are wholly separate, the one in the neck and the other in the thorax. These observations led Bischoff[4] to conclude that in the

1 Loc. cit., p. 19.

2 Loc. cit., p. 76.

3 Rudolf Fick, 2. "Beobachtungen an einem zweiten erwachsenen Orang-Utang und einem Schimpansen." Archiv für Anat. und Phys., Anat. Abt., 1895, p. 297.

4 Bischoff, "Beiträge zur anatomie des Hylobates leucisus und zu einer vergleichenden Anatomie der Muskeln der Affen und des Menschen." Abhandl. der math.-phys. Classe der könig. bayer. Akad. der Wissenschaften, Vol. X, 1870, p, 207.

ape we had definite proof that the two muscles belong to one another and form one single great muscle going from the ribs in the chest and from the cervical vertebræ in the neck to be inserted into the whole length of the vertebral border of the scapula. Bischoff states that in Macacus and other lower apes, this continuity of the two muscles is even more complete than in anthropoids; in these a bundle arises from the first rib, which unites immediately with that arising from the seventh cervical vertebra, whilst in anthropoids a space exists between the two portions as a rule. One must remember, however, that the extensive origin described from the cervical vertebræ does not always exist in the Orang, as in my specimen there were only three slips of origin from the three upper cervical vertebræ. Hepburn[1] describes four slips in the Orang dissected by him. In man there occasionally occurs partial union between the two muscles in question (Quain), whilst the origin of the levator may be extensive, receiving aponeurotic fibres even from the first and second ribs (Testut).

It would therefore appear that, as a rule, the two muscles are distinct in man; they are continuous in the lower apes, and the higher (anthropoid) apes occupy an intermediate position where there is a partial continuity.

The *Omo-cervicalis* (plate III, fig. I, *m.o*), is an interesting muscle which Bischoff asserts is not found in man,[2] at all events of similar character to that occurring in apes. It arose in my Orang from the anterior aspect of the arch of the atlas vertebra and from its transverse process; it was inserted into the clavicle on its posterior aspect at the junction of the middle and outer thirds of the bone, the attachment to the clavicle being 1.5 cm. wide. The muscle has been described in the anthropoid apes and in the lower apes by Huxley,[3] whilst in the various anthropoids it has been found by Cuvier,[4] Vrolik,[5] Owen,[6] Chapman,[7] Macalister,[8] and others. Its attachment to the shoulder girdle varies in apes and

1 Loc. cit., p. 153.

2 Loc. cit., p. 207.

3 Loc. cit., Vol. I, pp, 428, 456, 528, 596, 647, and Vol. II, p. 40.

4 Georges Cuvier, "Anatomie comparée; recueil de planches de myologie," Paris, 1849.

5 Loc. cit., p. 18.

6 R. Owen. "Myology of Simia Satyrus," Proceedings of the Zoological Society of London, Part I, 1830-31, p. 29.

7 H. C. Chapman, "On the Structure of the Orang-Outang," Proceedings of the Academy of Natural Science of Philadelphia, 1880, p. 161.

8 Alex. Macalister. "The Muscular Anatomy of the Gorilla," Proceedings of the Royal Irish Academy, Sr. 2. Vol. I, 1870-74, p. 501.

hence Bischoff suggested the name of "omo-cervicalis" and abandoned the old names of "cleido-cervicalis" and "acromio-trachealis" which had been applied to it. Tyson called it "levator claviculæ." Bischoff asserts that in all four anthropoids it always arises from the clavicle, whilst in Cynocephalus it has been found arising from the acromion process and in Macacus from the spine of the scapula. Deniker[1] demonstrated the muscle in a foetal Gorilla of the fifth or sixth month of gestation, and in a foetal Gibbon of the seventh or eighth month; in both instances passing from the atlas vertebra to the clavicle. It would appear that the atlantal attachment of this muscle is very constant in anthropoid apes, although Champneys[2] described the dissection of a Chimpanzee in which the muscle arose "from the occipital bone in a line with the occipital condyles and was inserted into the acromial or external half of the clavicle anterior to the insertion of the trapezius." Huxley states that in man[3] a separate muscle has been seen to pass from the mastoid process to the extremity of the acromion, detached from the trapezius, and representing, to a certain extent, in man the trachelo-acromial. Testut[4] mentions a muscle described by Gruber under the name of "trachelo-clavicularis imus" arising from the transverse process of the sixth cervical vertebra, and inserted into the clavicle. This Testut considers a variety of the omo-cervicalis. In Quain's Anatomy[5] is mentioned a detached bundle of the levator anguli scapulæ passing from the transverse process of the upper one or two cervical transverse processes to the outer end of the clavicle; this would apparently represent a true omo-cervicalis in man.

We may conclude, therefore, that the muscle in question is found invariably in the ape, whilst in man it occurs as a very rare variety.

The *Omo-hyoid* muscle was present and possessed similar attachments and relations to those in man. The supra-scapular artery and nerve passed over the superior border of the scapula anterior to the omo-hyoid insertion. There was no indication of a transverse ligament which exists over the supra-scapular notch in man. In Fick's[6] Orang the omo-hyoid was weak and there was no intermediate tendon.

---

1 J. Deniker, "Recherches anatomiques et embryologiques sur les singes anthropoïdes jeunes et adultes," Archives de Zoologie expérimentale, Sr. 2, Vol. III, 1885, pp. 125, 131.

2 F. Champneys, "On the Muscles and Nerves of the Chimpanzee (Troglodytes niger) and a Cynocephalus anubis," Journ. of Anat. and Phys., Vol. VI, 1872.

3 Loc. cit., Vol. I, pp. 428, 456.

4 Loc. cit., Vol. I, Part 2, p. 697.

5 Loc. cit., Vol. II, Part 2, p. 208.

6 Loc. cit., I, p. 15.

Bischoff[1] also remarks upon the fact that the intermediate tendon often fails to develop in the ape; in Bischoff's Orang, however, the whole muscle failed. This authority also refers to an Orang dissected by Alix in which the omo-hyoid arose from the clavicle as well as from the scapula; this variation in the Orang is of interest, because a similar variation sometimes occurs in man. The total absence of the omo-hyoid is not rare in man; of this Testut[2] has recorded nine cases. Again the absence of either the anterior or posterior belly may occur, and the bony attachment more particularly of its posterior belly is subject to great variation in man. Gegenbaur,[3] after a critical study of the varieties of the omo-hyoid as it occurs in man, and the conditions of its development met with in the lower animals, concludes that it belongs to a muscle group including in man the sterno-hyoid and sterno-thyroid muscles. These muscles in some animals (reptiles) form a continuous attachment from the sternum, along the clavicle to the scapula. Referring the omo-hyoid to such a group of muscles we can readily explain the occurrence of the intermediate tendon and the variation in the bony attachments, sometimes to the clavicle, sometimes to the scapula, or it may be to both bones.

The *Sterno-mastoid* had an extensive origin from the mastoid process and the occipital bone, and was inserted by two heads, one into the manubrium sterni on its anterior aspect, and the other into the inner fourth of the clavicle. Cuvier[4] figures the sterno-mastoid in the Orang as two very distinct muscles, the clavicular portion arising from the skull below the sternal portion and proceeding to its insertion into the clavicle. In the Gorilla it is usually in two distinct portions, as indeed it is also in the other anthropoids. The two portions of the sterno-mastoid in man are separated from one another by a varying interval at their insertion.

The *Pectoralis major*, consisted of three very distinct portions :—(1) *Pars costo-abdominalis* (plate IV, fig. 2, *p.m. 1*), which arose from the osseous part of the fifth rib near its sternal extremity, and by an origin 4 cm. wide from the aponeurosis of the external oblique muscle of the abdomen. The fibres passed very obliquely upwards and outwards and lay on a plane posterior to the other two portions of the muscle. The insertion was into the strong fascia over the biceps tendon, and

1 Loc. cit., I, p. 205.

2 Loc. cit., Vol. I, Pt. 2, p. 677.

3 C. Gegenbaur, "Ueber den Musculus Omohyoïdeus und seine Schlüsselbeinverbindung." Morphologisches Jahrbuch, Vol. I, 1876, p. 264.

4 Loc. cit., plate 15.

extended up to the greater tuberosity of the humerus and the capsule of the joint—the insertion extended further up on the humerus than the other two portions of the muscle. (2) *Pars sterno-costalis* (plate IV fig. 2, *p.m. 2*), arose from the cartilages of the third, fourth, fifth and sixth ribs, and from the adjacent portion of the anterior aspect of the sternum. It was inserted by means of the strong fascia over the biceps tendon into the humerus. The fibres of this portion of the muscle passed almost horizontally from origin to insertion. It lay intermediate in position between the pars costo-abdominalis and the pars sternalis. (3) The *Pars sternalis* (plate IV, fig. 2, *p.m. 3*), arose from the anterior surface of the manubrium sterni near its upper margin. There was no attachment to the clavicle. The fibres passed very obliquely from above downwards and outwards in front of the other portions of the muscle. The muscle was inserted into the humerus on the anterior aspect of the bone in front of the biceps by an insertion 2 cm. wide, extending further down on the bone than the other portions of the muscle. The three portions of the pectoralis major were very definitely separated from one another, the intervals being filled in by a large amount of fat.

The other three anthropoid apes, according to Bischoff, possess a fourth division of the pectoralis major, viz., a "pars clavicularis" arising from the sternal end of the clavicle, whilst in an Orang dissected by Bischoff[1] the clavicular portion was, as in my specimen, absent. On the other hand Fick[2] describes a clavicular portion in both Orangs dissected by him, and Bischoff[3] found in a second Orang examined by him, a portion of the pectoralis major arising from the ligaments of the sterno-clavicular joint. Chapman and Owen both failed to find a clavicular portion in the Orang. Bischoff, it may be added, is authority for the statement that the pars clavicularis fails in the lower apes.

It would therefore appear that the pectoralis major muscle is composed of four portions; this fact is recognized by Testut in describing the muscle in man as consisting of: 1st, portion claviculaire; 2nd, portion sternale; 3rd, portion abdominale; 4th, portion chondro-costale. The clavicular portion, which is, as a rule, well developed in man, is

---

1 Loc. cit., I, p. 208.

2 Loc. cit., I, p. 15 and 2 p. 298.

3 Bischoff, "Beiträge zur Anatomie des Gorilla," Abhand. der math.-physik. Classe der königl. bayer. Akad. der Wissenschaften, Vol. XIII, Abth. 3. München, 1880, p. 9.

4 Loc. cit., p. 161.

5 Loc. cit., p. 29.

6 Loc. cit., Vol. I, pt. 2, p. 722.

present only occasionally in the Orang, and is absent in the lower apes. On the other hand, the Gorilla, Chimpanzee, and Gibbon resemble man in the well-developed clavicular portion of this muscle; in the Gorilla, in fact it is more strikingly developed than in man. One notices in man considerable variation in the width of the interval separating the clavicular portion of the muscle from the remaining part; according to Testut this may be several centimetres. One is inclined to believe that the portion in the Orang which I have described as the "pars sternalis" in reality corresponds to the "pars clavicularis" of man (see plate IV, Fig 2, *p.m. 3*). My reason for coming to this conclusion is that we have in the anterior part of the "pars sterno-costalis" in my Orang a portion corresponding to the "pars sternalis" of man, whilst the wide interval existing in my Orang between the middle and upper portions of the muscle would correspond to the varying interval observed in man between the sternal and clavicular portions of the muscle. It would appear, therefore, that the upper portion of the great pectoral has gradually extended its width of attachment, and has also travelled outwards. At first purely sternal (as in the lower apes) then having a varying degree of clavicular attachment. In the case of Bischoff's Orang, quoted above, the attachment was intermediate in position, namely to the sterno-clavicular joint. One may note that in man the muscle may extend along the clavicle and become incorporated with the deltoid or, on the other hand, in rare cases, the clavicular portion may be absent (Quain). In my Orang a large triangular interval existed between the anterior border of the deltoid and the superior border of the pectoralis major and the clavicle; this space was crossed by the pectoralis minor.

In connection with the pectoralis major in man, various anomalous muscles have been described. In a female subject Bryce[1] has recently reported the following anomalous development of the pectoral sheet. The upper part of the pectoralis major muscle was ill-developed, being represented by a narrow band resembling in fact, very much, the pars sternalis which I have described in my Orang. He found present also a "sterno-clavicularis" which arose from the side of the manubrium sterni and the second costal cartilage, and was inserted into the clavicle along the inner two-thirds of the bone. A "sternalis" attached partly to the second cartilage and the tendon of the sterno-clavicularis above, and below to the aponeurosis of the external oblique opposite the seventh cartilage, and a "chondro-epitrochlearis" which arose from the outer end

1 T. H. Bryce, "Note on a Group of Varieties of the Pectoral Sheet of Muscle." Journ. of Anat. and Phys., Vol. XXXIV, 1899, p. 75.

of the sixth costal cartilage running under the lower border of the pectoralis major, it passed down the arm and was inserted into the intermuscular septum two inches above the internal condyle.

The *Pectoralis minor* (plate IV, fig. 2, *p. min*), arose from the bone of the fourth rib by an origin 2 cm. wide. immediately external to the cartilage and from the bone and cartilage of the third rib by an origin of similar width. The muscle was inserted into the superior and inner part of the coracoid process of the scapula. Certain fibres of the tendon of insertion were carried on beyond the coracoid and were definitely traced as two ligamentous structures which diverged from one another, one of which was attached to the outer end of the clavicle, and the other into the acromion process of the scapula (see plate IV, fig. 2, and fig. 3, *lig. 1*, *lig. 2*), the insertion here described has not hitherto been demonstrated, and it would appear to be an observation of some interest. Duvernoy[1] states that in the Chimpanzee the pectoralis minor became attached to the coraco-clavicular ligament; again whilst I found no description of an acromial attachment among the anthropoid apes I find that in Cynocephalus, according to Bischoff[2] the pectoralis minor is inserted into the coracoid process and the coraco-clavicular ligament. In the Chimpanzee we find that Huxley, Fick, Bischoff, Hepburn and others have described an insertion into the capsule of the shoulder joint. It is not unusual to find this capsular attachment in man. This relation of the pectoralis minor to the capsule, in certain cases occurring in man and monkeys, induces Bland Sutton to believe that the coraco-humeral ligament of the shoulder joint is the tendon of the pectoralis minor muscle transformed into a fibrous band. But as the insertion varies so greatly in apes it would seem that Bland Sutton is not warranted in coming to the conclusion he does. Hepburn found that in the Gibbon in addition to a coracoid and a clavicular attachment, the muscle was inserted into the common tendon of the coraco-brachialis and biceps a short distance below the tip of the coracoid process. Whilst in the Chimpanzee both Huxley[5] and Hepburn describe the muscle as uniting with the supra-spinatus. Judging from the attachments described in my Orang, and from the relations found in some other apes and the variations in man, it may be that the trapezoid portion of the coraco-clavicular ligament and the coraco-acromial ligament are in part derived

1 Loc cit., p. 76.

2 Loc. cit., I, p. 209.

3 J. Bland Sutton, "Ligaments, their Nature and Morphology." London, 1887, p. 71.

4 Loc. cit., p. 154.

5 Loc. cit., Vol. I, p. 456.

from the tendon of the pectoralis minor. Wood[1] has described in man a case in which the muscle joined the coraco-acromial ligament and another in which it was inserted into the clavicle and the costo-coracoid membrane.

The *Serratus magnus* arose from the upper eleven ribs, interdigitating below with the external oblique muscle of the abdomen and was inserted into the whole length of the vertebral border of the scapula, blending above with the levator anguli scapulæ at its insertion. Fick describes an origin in the Orang from twelve ribs. In man the muscle rarely extends beyond an attachment to the upper nine ribs.

The *Deltoid* arose from the outer third of the anterior surface of the clavicle, from the acromion process and from the spine of the scapula also from the fascia over the infra-spinatus muscle. It was inserted into the outer aspect of the humerus as in man; some additional slips pass to the humerus for about 2 cm. above the main point of insertion, and some superficial fibres pass to the fascia, which extends down to the external condyle. Fick speaks of this muscle as similarly well developed in his Orang.

The *Teres major* arose from the lower fourth of the axillary border of the scapula and from the dorsal surface of the inferior angle; its insertion 3cm. wide found attachment to the humerus behind the latissimus dorsi. The lower part of the muscle near its insertion was joined by the slip from the latissimus dorsi already described (p. 21).

The *Teres minor*, the *Supra-spinatus* and the *Infra-spinatus* muscles had similar attachments to those found in man; it was noted, however, that the aponeuroses of insertion of the last two muscles were directly continuous with one another and blended with the capsule of the shoulder joint.

The *Subscapularis* resembled that found in man. Fick described a slip of origin of this muscle from the teres major.

The *Subclavius* was not strongly developed, measuring only 0.3 cm. in width; it arose from the cartilage of the first rib, and had an insertion 2 cm. wide into the clavicle at the junction of the middle and the outer thirds of that bone on its under aspect; it here extended to the point of attachment of the coraco-clavicular ligament, but was in no manner continuous with that structure. The subclavius is poorly developed in

---

1 J. Wood, "Variations in Human Myology." Proceedings of the Royal Society of London, Vol. XV, 1867, p. 231.

the anthropoid apes; in Huxley's Gorilla[1] it was only represented by a ligament.

The *Triceps* muscle had the following origin:—1. The long head arose from the upper two-thirds of the axillary border of the scapula to the extent of 4 cm.. The upper part of its origin being in front of the teres minor and the lower part behind the teres major. 2. The inner head arose from the posterior aspect of the humerus a short distance above and behind the lowest point of attachment of the teres major. The musculo-spiral nerve crosses this head obliquely about 2.5 cm. below its upper limit; the nerve is thus separated from the bone by the muscle. 3. The external head arose from the posterior aspect of the humerus as high up as the insertion of the teres minor. The musculo-spiral nerve proceeds outwards between the lower part of this muscle and the bone. The triceps possesses a very wide fascial insertion in the region of the elbow, and is inserted also into the olecranon process. Fick remarks upon the striking weakness of the inner head in his Orang.

The *Coraco-brachialis* arose from the anterior portion of the coracoid process, and from the fascia over the subscapularis muscle; two portions of the muscle were defined, one found insertion by an attachment 2.5 cm. wide into the middle of the inner portion of the humerus, whilst a more feebly developed upper portion found an attachment by an insertion 0.5 cm. wide immediately above the other portion. The two parts are separated by the passage of the musculo-cutaneous nerve, which sends a branch of nerve supply to each. Some fibres from the upper portion pass down in front of the tendinous insertion of the lower part, and there find independent insertion into the humerus. Wood by a comparative study of this muscle in the mammalia concludes that the coraco-brachialis is made up of three component parts: 1. The *coraco-brachialis brevis*, which passes from the outer side of the coracoid process near its root, to the capsule of the shoulder-joint near the anatomical neck of the humerus; 2. The *Coraco-brachialis medius* obtaining its insertion into the inner border of the humerus near its middle; 3. The *Coraco-brachialis longus*, which extends down the inner side of the arm to be attached to the internal condyle. The coraco-brachialis medius is the portion of the muscle which is characteristically of human type; in man also, both brevis and longus occur as varieties, the latter being the

---

1 Loc. cit.. Vol. I, p. 538.

2 John Wood, "On Human Muscular Variations, and their Relation to Comparative Anatomy. Journ. of Anat. and Phys., Vol. I, 1867, p. 45.

more common. Vrolik[1] describes the medius and longus as existing in the Chimpanzee, a condition which also existed in Hepburn's Orang. The degree of development of this muscle is, however, by no means constant, but, according to Bischoff, numerous variations occur both among the anthropoid apes and among the lower apes. In certain of the mammalia, according to Wood, the brevis alone is developed as in the dog and cat, also in bats and moles. Bland Sutton[2] compares the arrangement of the coraco brachialis in its three parts in the arm to the arrangement of the three adductor muscles in the thigh.

The *Biceps* resembled, in its two heads of origin, the condition found in man; it was inserted into the radius by an aponeurosis of insertion 1.5 cm. wide, very thin and ribbon-like as it passed back into its insertion, which lay wrapped around the neck of the radius when the forearm was pronated. A well-developed bicipital fascia passed off to blend with the fascia on the inner border of the forearm. This fascia was absent in Fick's Orang. Bischoff[3] states that in all apes (anthropoids and others) the biceps arises as in man, with the exception of the Gibbon, where he found that the short head arose from the lesser tuberosity of the humerus instead of from the coracoid process; Huxley[4] found in his Gibbon, the short head arising from the tendon of the pectoralis major. The muscle is subject to great variation in man chiefly in the multiplication of additional heads of origin: the long head has occasionally been absent, as described by Lubosch[5] and others in man, but such a defect is extremely rare.

The *Brachialis anticus* arose from the anterior portion of the humerus as high up as the insertion of the deltoid, the origin of the muscle being wholly external to the insertion of the coraco brachialis. It was inserted into the coronoid process of the ulna. A narrow slip from the outer aspect of this muscle crossed in front of the musculo spiral nerve and joined the supinator longus. This connection with the supinator longus has been observed in man (Testut).

The *Pronator radii teres* arose by two heads, one from the internal condyle and the intermuscular septum, and the other from the coronoid process of the ulna on its inner aspect. The median nerve passed into

---

1 Loc. cit., p. 30.

2 Loc. cit., p. 13.

3 Loc. cit. 1, p. 210.

4 Loc. cit., Vol. I, p. 648.

5 W. Lubosch. "Ein M. Coraco—Antibrachialis beim Menschen Beiträge zur Morphologie des M. Biceps Brachii." Morphologisches Jahrbuch, Bd. XXVII, Heft 2, 1899, p. 309.

the forearm between its two heads, the deep head separating the nerve from the ulnar artery. It was inserted into the radial border of the radius by an insertion 2 cm. wide immediately below the upper third of the bone. The high insertion of the pronator radii teres corresponds to that found by Langer[1] in his Orang. This, he points out, differs from the condition found in man, where the muscle in question is inserted below the middle of the bone. It also implies a shorter extent of attachment of the supinator brevis, which is attached above the pronator. This circumstance led Langer to assert that it is only the lower part of the radius which is so enormously elongated in the Orang compared with the condition found in man. Langer's Orang was young, but in the adult animal dissected by Fick[2] he found the position of the insertion of the pronator similar to that occurring in man; he therefore concludes that either the high insertion is characteristic of the young Orang thus differing from the old animal, or that Langer's case was abnormal—my specimen would go to prove the truth of the former hypothesis. In Bischoff's Gorilla the coronoid head of the muscle was absent, but Macalister[3] found it in his specimen. Chapman[4] found both heads in the Orang. The coronoid head is frequently absent in man (Testut).

The *Flexor carpi radialis* arose from the common origin of the flexors from the internal condyle and the intermuscular septum, also from an oblique line on the outer border of the radius in common with the flexor sublimis digitorum; it was inserted into the base of the second metacarpal bone, after passing through the groove in the trapezium. Fick and Langer both describe a radial origin in the Orang. The radial head occurs as an occasional variation in man.

The *Palmaris longus* arose in common with the other flexors from the internal condyle and from the fascia over it. It lay immediately subjacent to the fascia of the forearm until it reached a point 3 cm. above the wrist joint, where it perforated the fascia and continued down upon its superficial aspect. Crossing the anterior annular ligament it proceeded to its insertion into the palmar fascia. There is a very definite slip to the base of the thumb, and from this the abductor pollicis arises in part. In both Orangs dissected by Fick there was a slip to the abductor pollicis and he describes, in addition, another slip to the flexor minimi digiti. Bischoff states that the palmaris longus was absent in the

1 Loc. cit., p. 179.
2 Loc. cit. 1, p. 22.
3 Loc. cit., p. 502.
4 Loc. cit., p. 162.

Gorilla, and the result of Hepburn's investigations was that he found this muscle present in the Chimpanzee, Orang and Gibbon, but absent in the Gorilla.

The palmaris longus, both in man and apes, would appear to be a rudimentary structure; in many animals it is a well developed muscle and sends tendons to all the digits. From a comparative study of this muscle Bland Sutton[1] and others have arrived at the conclusion that the palmar fascia of the human hand arises from the degeneration of the distal end of the palmaris longus muscle. According to Grapow[2] the palmar fascia was first described as an expansion of the palmaris longus by Dupuytren in 1832. The view which Grapow holds concerning it is, that the main part of the palmar fascia is derived as a prolongation of the anterior annular ligament of the wrist, whilst the superficial, longitudinally coursing fibres are derived from the palmaris longus muscle. The muscle in man is very variable in its development, it is entirely absent in ten per cent. of all cases, and it presents great variety, not only in its points of insertion but also in the development of its fleshy and tendinous fibres.

The *Flexor carpi ulnaris* arose in common with the flexors from the internal condyle, also from the inner side of the olecranon process of the ulna. The ulnar nerve passed into the forearm between the two heads. It was inserted into the pisiform bone. The muscle thus resembles that found in man.

The *Flexor sublimis digitorum* vel *Perforatus* arose from the common origin from the internal condyle and intermuscular septum, also from the coronoid process and the olecranon process and in common with the flexor carpi radialis from the oblique line of the radius. Passing beneath the annular ligament it there passed into the palm in four tendons. The tendon for the index finger and that for the little finger were derived mainly from fibres arising from the internal condyle. The tendon for the middle finger was derived mainly from fibres arising from the radius. The tendon for the ring finger was derived mainly from fibres having an origin from both the radius and the internal condyle. The fleshy mass from which the tendon for the index finger arose formed a very definite fasciculus which passed down on the deep aspect of the main part of the muscle along its ulnar border, and

---

1 Loc. cit., p. 16.

2 Max-Grapow, "Die Anatomie und Physiologische Bedeutung der Palmaraponeurose. Archiv für Anatomie und Entwickelungsgeschichte, 1887, p. 145.

then crossed obliquely behind the other tendons to reach the index finger. The fasciculus is joined at an acute angle by a few fibres from the radial origin; this radial fasciculus represented not more than one-twentieth part of the main fasciculus, being a very slender, though definite contribution. In Bischoff's Gorilla there were four almost completely separated muscles having an arrangement similar to that found in my Orang. This differs from the muscle dissected by Fick in his Orang, in which there was a superficial fasciculus passing to the fourth and fifth digits, and a deep fasciculus to the second and third digits. The muscle in man is developed in two layers, more or less separable from one another, the superficial passing to the third and fourth, and the deep to the second and fifth digits.

The *Flexor profundus digitorum* vel *Perforans* arose by three distinct fasciculi.

1. From the anterior and inner aspects of the ulna extending back to the posterior border and upwards as high as the posterior portion of the olecranon process, and downwards on the ulna to about its middle. (The nerve supply was from the ulnar.)

2. From the anterior aspect of the ulna up to and including the lower part of the coronoid process ; from the anterior and inner border of the ulna below the fasciculus I. and from the interosseous membrane. (The nerve supply was the median.)

3. From the anterior aspect of the radius, and from the interosseous membrane ; this radial attachment extends two-thirds of the way down the bone. In the middle third, well over to the radial border, its attachment is limited by the origin of the flexor sublimis digitorum. (The nerve supply was from the median.)

The tendons passed under the annular ligament, and fasciculus No. 1 supplied tendons to the minimus and the ring fingers ; fasciculus No. 2 to the middle finger, and fasciculus No. 3 to the index finger. A *lumbrical* muscle was developed on the radial side of each tendon in the palm. Rudolf traced the nerve supply of the lumbricals, and found the outer two were supplied by the median and the inner two by the ulnar nerve.

There was no trace of a long flexor for the thumb. In this particular man differs very markedly from the Orang. In man the *flexor longus pollicis* is a separate well developed muscle, and nothing approaching it

is found in the ape. Langer,[1] Fick,[2] Bischoff,[3] Huxley,[4] Chapman,[5] and others have failed to find a trace of the flexor longus pollicis in the Orang. Duvernoy, in the Gorilla, describes the flexor as going to the index finger and from this a slender tendon is detached for the thumb, which takes the place of the flexor longus pollicis.[6] Brooks[7] in dissecting an Orang found that the two heads of the flexor brevis pollicis were separated at their insertion by a slender tendon which, he considered, represented the flexor longus pollicis; this tendon was inserted into the ungual phalanx, and it could be followed up the forearm, but about two inches above the wrist it expanded into areolar tissue. Among the anthropoids one finds a rudimentary tendon going to the thumb, this is derived from the flexor tendon which is distributed to the index finger. Thus in the Chimpanzee, Huxley and Macalister both describe a very slender tendon to the thumb from the flexor longus digitorum tendon for the index finger. A similar condition is found by Bischoff and others in the Gorilla and the Gibbon. Among the lower apes of the old world (Cynopithecini) Huxley found a rudimentary slender tendon to the pollex derived from the flexor tendon to the index, a condition similar to that in the anthropoids named. Among the Lemurs (Stenops tardigradus) the same authority states,[8] that a true and distinct flexor longus pollicis of separate origin and insertion exists. Similar observations have been made by Bischoff regarding the lower apes and the rudimentary condition in them of the flexor longus pollicis. The anthropoid apes and the lower apes therefore resemble one another in respect to this muscle, whilst they all differ from man where the flexor longus pollicis is developed as a strong muscle completely separated from the flexor profundus digitorum, a condition never yet found in the ape. It is not common to find much variation in the development of the flexor longus pollicis in man, but such does occur occasionally. Turner[9] placed on record several cases in which the flexor longus pollicis contributed a tendon of communication

---

1 Loc. cit., p. 180.

2 Loc. cit. I, p. 23.

3 Loc. cit. I, p. 214.

4 Loc. cit., Vol. I, p. 596.

5 Loc. cit., p. 162

6 Loc. cit., p. 106.

7 H. St. John Brooks, "On the Short Muscles of the Pollex and the Hallux of the Anthropoid Apes with Special Reference to the Opponens Hallucis." Journ. of Anat. and Phys., Vol. XXII, 1887-8, p. 82.

8 Loc. cit., Vol. II, p. 145.

9 W. Turner, "On Variability in Human Structure, with illustrations from the Flexor Muscles of the Fingers and Toes." Transactions of the Royal Society of Edinburgh, Vol. XXIV, 1867, p. 179.

with the flexor profundus digitorum. Schulze[1] has described a similar condition. Turner records one case in which the bond of union passed in the opposite direction from the flexor profundus to the flexor longus pollicis. Wagstaffe[2] has described a case in which a muscle arose like the flexor longus pollicis, but was inserted into the deep flexor tendon to the index finger and was connected also with the fibrous structures about the wrist; there was also a tendon on the palmar aspect of the first and second phalanges of the thumb, which, however, was attached above to the head of the metacarpal bone. Gegenbaur[3] has recorded a case in which the flexor longus pollicis was absent from the thumb of man—the muscle had evidently fused with the flexor for the index finger; the thumb itself was very rudimentary, and presented an appearance very similar to that found in the apes. The abnormality was found on the left side of the body, the right flexor longus pollicis being normally developed. The importance of these facts concerning the absence of the flexor longus pollicis in the ape and its existence as a strongly developed structure in man is emphasized by Testut[4] when he says, "De toutes les dispositions anatomiques qui différencient actuellement l'homme des autres Primates, l'une des plus importantes est, sans conteste, la présence chez l'homme, l'absence chez les Singes d'un long fléchisseur propre du pouce, complètement distinct des autre fléchisseurs." Testut holds that the flexor longus pollicis is present in the apes, arising as it does in man, but the peculiarity in apes is that it fuses with the flexor profundus and loses the characteristic individuality which is found in man where it passes as a distinct and separate muscle to the thumb. Testut himself, after examination of a large number of subjects, had never found the flexor longus completely absent from the thumb of man.

Gratiolet and Alix[5] describe a rudimentary muscle in the Chimpanzee arising from the ligaments over the anterior aspect of the carpus and inserted into the last phalanx of the thumb.

The *Pronator quadratus* consisted of a number of muscle fibres passing transversely from the radius to the ulna; in the upper part of

1 F. Eilhard Schulze, "Die Sehnenverbindung in der Planta des Menschen und der Säugethiere." Zeitschrift für Wissenschaftliche Zoologie, Bd. 17, 1867, p. 1.

2 W. W. Wagstaffe, "Partial Deficiency of the Tendon of the Long Flexor of the Thumb," Journ. of Anat. and Phys., Vol. VI, 1872, p. 212.

3 C. Gegenbaur, "Ein Fall von mehrfachen Muskelanomalien an der oberen Extremität," Virchow's Archiv für Pathol. Anat. und Phys., Vol. XXI, 1861, p. 382.

4 L. Testut, "Le Long Fléchisseur Propre du pouce chez l'homme et chez les Singes," Bulletin de la Soc. Zool. de France, Vol. VIII, 1883, p. 164.

5 Loc. cit., p. 172.

the muscle the fibres were very oblique, arising from the ulna as high up as the upper portion of the lower fourth, and passing obliquely downwards and outwards to the radius. The obliquity of the fibres was also noted by Fick.

The *Supinator longus* arose from the supracondyloid ridge of the humerus as high as the middle of the bone, and extended down to within 2.5 cm. of the external condyle. It was inserted into the outer aspect of the lower extremity of the radius, including the styloid process, the whole insertion being 2.5 cm. wide. In Fick's Orang the insertion began 7 cm. above the styloid process. In the Gibbon, Bischoff found it short, not reaching to the styloid process but inserted into the middle of the bone. A similar condition was found in the Gibbon by Huxley.[1] In man the muscle has been found inserted as high up as the middle third of the radius.

The *Supinator brevis* and *Anconeus* were well developed, and resembled in their connections and relations the condition found in man, in other anthropoids and in the lower apes.

The *Extensor carpi radialis longior* arose below the supinator longus from the supra condyloid ridge of the humerus as low as the external condyle. It passed under the annular ligament in company with the short radial extensor and was inserted into the dorso-radial aspect of the base of the second metacarpal bone.

The *Extensor carpi radialis brevior* arose from the common extensor origin from the external condyle, and was inserted into the dorsal aspect of the base of the third metacarpal bone. The two radial extensors were crossed obliquely by the short and long extensors of the thumb and the extensor ossis metacarpi pollicis; they resembled in their relations and connections the condition found in man and in the lower and the anthropoid apes.

The *Extensor communis digitorum* arose from the common extensor origin, and passed under the annular ligament in company with the extensor indicis; it divided into four tendons for insertion into the four inner digits as in man.

The *Extensor minimi digiti* was a very small fasciculus arising in common with the extensor communis; it was inserted into the extensor expansion over the proximal phalanx of the ring and the little fingers. One finds that the slip to the ring finger occurs as a variety in man,

1 Loc. cit., Vol. I, p. 648.

whilst it would appear to be the usual condition in the Orang, as described by Fick, Bischoff, Huxley, Hepburn and Chapman. On the other hand, according to Bischoff,[1] in the Gorilla, Chimpanzee and Gibbon, and in the lower apes (excluding Cynocephalus, where it exists as in the Orang), the tendon is restricted to the little finger as it is in man.

The *Extensor carpi ulnaris* arose from the common extensor origin, from the olecranon process and the posterior portion of the ulna and from the intermuscular septum ; it was inserted into the ulnar border of the fifth metacarpal bone.

The *Extensor Indicis* arose from the middle of the ulna by an origin 1.5 cm. wide, and from the interosseous membrane, passing beneath the common extensor, it was inserted into the extensor expansion over the dorsal aspect of the proximal phalanx of the second and third digits. In man the extensor indicis is inserted into the index finger only, although, as a variation, it is not very uncommon to find a slip to the middle, or even the ring fingers, whilst occasionally there is a slip to the thumb. It is sometimes altogether absent in man, and Testut[2] states that he has seen it tendinous throughout its whole extent, According to Bischoff[3] in the Gorilla alone among anthropoids do we find the extensor indicis restricted to the index finger and thus resembling man. In the Orang and Chimpanzee it passes to the second and third digits, whilst in the Gibbon it passes to the second, third and fourth digits. In the lower apes also it would appear to be distributed, as a rule, to the second and third digits. Pithecia being an exception (Bischoff), where it is restricted to the index finger only. Huxley,[4] in discussing this muscle in the Orang along with the extensor minimi digiti, calls attention to the fact that the normal arrangement in many of the lower mammalia is to have a superficial and a deep extensor supplied to every digit. This arrangement is approached when as in my Orang the extensor minimi digiti is supplied to the fourth and fifth toes, and the extensor indicis to the second and third toes. These two muscles, as they occur in man, are therefore but fragments of a more extensive muscle group occurring in lower animals.

The *Extensor longus pollicis* arose from the dorsal aspect of the ulna above the origin of the extensor indicis, and passed to its insertion in a

1 Loc. cit. I, p. 212.

2 Loc. cit. I, Vol. I, pt. 2, p. 813.

3 Loc. cit. I, p. 212.

4 Loc. cit., Vol. I, p. 596.

separate compartment of the annular ligament; it was inserted into the second phalanx of the thumb.

The *Extensor brevis pollicis* arose from the interosseous membrane and from the dorsal aspect of the radius and the ulna, it was inserted into the radial aspect of the base of the first metacarpal bone well to the anterior surface. This muscle is absent in most apes. Langer, Fick, Bischoff, Huxley and Chapman failed to find it in the Orang, whilst Hepburn[1] describes the muscle as being inserted, as in my example, into the metacarpal bone. Bischoff states that the muscle is absent in all apes, with the exception of the Gorilla. The muscle in my Orang was quite separate from the extensor ossis metacarpi pollicis, and had a distinct and separate insertion into the metacarpal bone. It represents a condition intermediate between that normal in man and that which Testut says is[2] constant in most apes where, according to this authority, the short extensor is blended with the extensor ossis metacarpi pollicis.

The *Extensor ossis metacarpi pollicis* arose from the radius and ulna, the more extensive attachment being to the radius, and was inserted by two tendons, one of which passed to the trapezium and the other to the fascia, from which the abductor pollicis and opponens arose. On the right side Rudolf found this tendon passing to the metacarpal bone of the thumb. On close examination of the slip to the trapezium one found, close to the point of insertion, a small irregularly oval sesamoid bone about 4 mm. in length. This bone was embedded in fibrous tissue which extended from the styloid process of the radius above to the base of the first metacarpal bone, and was there closely applied to the trapezium immediately below the tubercle of the scaphoid; the fibres of the tendon of the muscle appeared to be inserted into this bone. The sesamoid bone is described by Fick[3] and by Hepburn[4] in connection with the tendon of the extensor ossis metacarpi pollicis in the Orang. Fick describes the muscle as inserted into the trapezium and the first metacarpal on the left side, whilst it had an additional insertion into the scaphoid on the right side of his Orang. Bischoff[5] states that in the Orang, Cynocephalus, Pithecia and Hapale, the muscle is inserted as in man, into the metacarpal bone, whilst in the Gorilla,

1 Loc. cit., p. 167.

2 Loc. cit. 1, Vol. I, pt. 2, p. 811.

3 Loc. cit. 1, p. —,

4 Loc. cit., p. 167.

5 Loc. cit. 1, p. 213.

Chimpanzee, Hylobates, Circopithecus and Macacus it parts into two tendons—one for the trapezium, and the other for the middle phalanx of the thumb. Huxley describes the two divisions of the extensor ossis metacarpi pollicis in all four anthropoids, although he says the division is not so definite in the Orang as in the others.[1] Brooks[2] states that the sesamoid bone is apparently developed in all anthropoids in the tendon of the extensor ossis metacarpi pollicis. The double insertion of this muscle into the trapezium and the first metacarpal bone is frequently found as a variation in man, whilst the occurrence of the sesamoid bone in the tendon of the muscle in question in man has been reported by Zuckerkandl.[3]

The occurrence of the sesamoid bone in the tendon of the extensor ossis metacarpi pollicis has considerable interest attached to it, as Fick has suggested,[4] that it represents a præpollex rudiment. The probability is that the ossicle occurs very constantly in the Orang, although it may be of very small dimensions as Fick[5] found in a second Orang dissected by him, where it was scarcely the size of a grain of rice. Thus it may be very easily overlooked, and requires to be searched for with considerable care. The occurrence of this bone in the tendon of the muscle in question is no new discovery, as it is mentioned and figured by Vrolik[6] in the Orang, and the same writer states that it had been described by Camper in that animal. Camper looked upon it as a ninth carpal bone. Fick is inclined to believe that it does represent a supernumerary carpal bone. He has found it appearing as such in the skeleton of an old female Orang in the Leipzig Zoological Institute, where, on both sides it is attached to the carpus, on the one side being attached by some connective tissue, still unmacerated, to the trapezium, and on the other side lying between the trapezium and the scaphoid. There has been a great deal of discussion concerning the occurrence of marginal structures in connection with the hand, held by some to represent additional digits, and designated in the hand the præpollex and the postminimus. Similar observations are made concerning the foot. The question is, whether or not we have evidence that the pentadactyle type of hand was derived from the heptadactyle type. The difficulty in determining the significance

1 Loc. cit., Vol. I, p. 596.

2 Loc. cit., p. 81.

3 Zuckerkandl. Discussion on Pfitzner's Paper, "Bemerkungen zum Aufbau des Menschlichen Carpus." Verhandlungen der Anatomischen Gesellschaft. Göttingen, 1893, p. 193.

4 Loc. cit. 1, p. 25.

5 Loc. cit. 2, p. 298.

6 Loc. cit., p. 13, (and Plate VI, Fig. 2).

of these marginal structures is increased, because we recognize a large number of supernumerary carpals occurring in different parts of the carpus. Thus the os centrale is a structure apparently always represented in the human embryo, but it soon blends with one of the neighbouring bones and loses thus its individuality. We find this bone in the Orang remaining separate throughout life. In my specimen it lay between the scaphoid, the trapezium and the os magnum. Vrolik[1] claims to have been the first to describe this bone in the carpus of the Orang. Later investigation has proved that in the human embryo a large number of carpal elements are often present. Thus Thilenius[2] in the human carpus in embryos, from the second to the fourth month, found such supernumerary bones, all appearing as hyaline cartilage, their structure differing in no manner from the normal eight carpals. Thilenius describes some thirteen of such. They unite with the neighbouring carpals or metacarpals, so that normally in man eight carpals finally result. The os centrale may join the scaphoid, the third metacarpal, the trapezoid, or the os magnum. Thilenius found the "prætrapezium" in four cases of 113 hands examined, whilst the os centrale was present in all cases without exception; the other supernumerary carpals were present only occasionally. Pfitzner,[3] in a paper upon the human carpus, attempts to group all these supernumerary carpals in the human hand, and reconstructs the carpus so as to shew in a diagrammatic fashion the position occupied by all these additional carpal bones, and their relation to one another. It is in connection with the marginal bones, however, that the greatest interest has been aroused, and some anatomists look upon the bone described as the prætrapezium (or the os radiale externum) as representing a præpollex rudiment. Born[4] has examined similar structures in the tarsus of amphibians. In rana esculenta he figures a tarsus in which a supernumerary digit is added on the tibial side of the foot. This consisted of three catilaginous elements separated by joints and united with a tarsal element which it shared with the first metatarsal; a somewhat similar condition was found in Bufo variabilis. Emery[5] traces various carpal elements in the larvæ of amphibia, and describes in the anura what he considers to represent the præpollex, and the præhallux; he also demonstrated similar structures in rodents.

---

1 Loc. cit., p. 13.

2 G. Thilenius, "Die 'Uberzähligen' Carpuselemente menschlicher Embryonen." Anatomischer Anzeiger. ix., 1894, p. 665.

3 Pfitzner, "Bermerkungen zum Aufbau des menschlichen Carpus." Verhandlungen der Anatomischen Gesellschaft. Göttingen, 1893, p. 186.

4 G. Born, "Die Sechste Zehe der Anuren." Morphologisches Jahrbuch, Vol. I, 1876, p. 436.

5 C. Emery, "Zur Morphologie des Hand und Fussskeletts." Anatomischer Anzeiger, 1890, p. 287.

Baur,[1] as the result of his investigations of the reptilian carpus, concluded that the præpollex element was one of the true carpals (radiale displaced, being pressed out whilst the radiale centrale had taken its place and appeared as the representative of the true radiale. He considers that a similar view may be held regarding the amphibian carpus. Baur thus questions the validity of the præpollex theory. On the other hand, Bardeleben[2] is one of the strongest exponents of the theory. After studying the subject from the embryological standpoint and examining more than a thousand skeletons in the comparative anatomy collections of Berlin, Leyden, and London, he concludes that we must relinquish the old doctrine of five digits for the mammalia. The argument of Bardeleben is very interesting and ingenious. He finds in one of the Cape rodents (Pedetes capensis) in two skeletons a præpollex possessing a nail, and a postminimus in which were two bones. He also conducted his investigations among fossil forms and in the oldest fossil mammal in which the hand skeleton has been preserved he describes a præpollex rudiment. This fossil animal *Theriodesmus phylarchus*, comes also from South Africa (Nicholson[3]). The præpollex rudiment in the carpus of Theriodesmus has also been described by Thilenius.[4] The elements of the præpollex rudiment here, according to this authority, lie on the radial side of the hand, between the scaphoid, centrale and trapezium. Bardeleben, in his paper, attempts to trace the muscles of the præpollex and the post minimus, or rather their representatives, in the pentadactyle type. Thus the palmaris longus in the hand, and the plantaris in the foot, are looked upon as giving evidence of the existence of those supernumerary digits. Among lower animals (as has already been stated for the palmaris longus) these muscles give a varying number of tendons, numbering from three or four to seven, in some animals. Thus Bardeleben states that we have seven tendons representing the termination of the muscle in *Centetes* (one of the hedge-hog family of Madagascar). One of these tendons went to the præpollex and the other to the postminimus. Similar conditions were found in the plantaris. To the four groups of interossei present in the mammalian hand or foot Bardeleben would add the abductor muscles

---

1 G. Baur, "Der Carpus der Schildkröten." Anatomischer Anzeiger, 1892, p. 206.

2 K. Bardeleben, "Ueber die Hand-und Fuss-Muskeln der Säugetiere, besonders die des Præpollex (Præhallux) und Postminimus." Anatomischer Anzeiger, 1890, p. 435.

3 A. Nicholson, "A Manual of Palæontology." Edin. and Lond., 1889. Vol. II, p. 1269. Nicholson's description of this mammal is as follows:—"In the Karoo system of South Africa, in a horizon which is probably of lower mesozoic age, has been obtained a slab showing the impression of a pectoral limb, apparently referable to a small mammal, which has been described under the name of *Theriodesmus*."

4 G. Thilenius, "Ueber Sesambeine fossiler Säugetiere." Anatomischer Anzeiger, 1894–95, p. 42.

of the first and last digits. The abductor pollicis, and the abductor hallucis, arising from what he considers to be the rudiments of the præpollex or præhallux, and the abductor minimi digiti in both hand and foot arising from the postminimus. These abductor muscles together with the so-called "interossei," Bardeleben would designate the "flexores breves profundi." In addition, Bardeleben claims certain of the marginal long muscles as contributing to the præpollex, etc.; among others, the extensor ossis metacarpi pollicis, and flexor carpi radialis acting on the præpollex, and the flexor carpi ulnaris acting on the post minimus rudiment. He traces similarly corresponding muscles in the foot. Fick[1] discovered in man what he believed to be a flexor præpollicis. It arose from the outer margin of the radius near the insertion of the pronator, and as a continuation of the flexor longus pollicis, a portion was inserted into the transverse carpal ligament, but the chief tendon of insertion was attached to the volar projections of the trapezium and the scaphoid, processes which were considered by Pfitzner to represent the prætrapezium, and therefore the præpollex rudiment. Fick places considerable importance upon the fact that this præpollex rudiment was still a "rudiment" in the oldest known mammal, and concludes that it is highly improbable, therefore, that the primitive mammal possessed a true præpollex. This fact would also go to disprove the other theory that the præpollex, etc., are secondary new formations. These digits, if they exist, do not appear to have made any progress in development in the mammal.

Gratiolet and Alix[2] found the extensor ossis metacarpi pollicis inserted in the Chimpanzee by two tendons—one into the trapezium and the other into the base of the first metacarpal. In a foot note these authors refer to the fact that no sesamoid bone was present in the slip to the trapezium, and its absence they attribute to the fact that the animal was young. The explanation is not valid, as the bone was present in my Orang, although it was a young specimen.

The *Abductor pollicis* (plate V, fig. 5 *ab.p.*) muscle was well developed; it arose from the trapezium and the annular ligament, and was inserted into the radial border of the proximal phalanx of the thumb. The muscle would appear to present very few variations in the ape from the condition found in man. In Hepburn's Orang it arose from the annular ligament and had no direct attachment to the carpal bones.

The *Opponens pollicis* arose from the trapezium and the annular

1 Loc. cit. 1. p. 27.

2 Loc. cit., p. 163.

ligament, and from the tendon of the extensor ossis metacarpi pollicis and was inserted into the radial border of the first metacarpal bone. Brooks[1] also described the origin from the extensor ossis metacarpi pollicis. The opponens is well developed in apes and resembles in attachment and development the same muscle in the human hand.

The *Adductor obliquus pollicis* arose from the bases of the second and third metacarpal bones and the ligaments over the anterior surface of the carpus. A portion of the adductor obliquus pollicis (indicated in plate V, fig. *5 a.ob.p.*) exists as a separate slip passing over the anterior surface of the metacarpal bone. This apparently corresponds to the muscle and tendon fasciculus which Langer[2] describes and figures, and which he believes to represent the flexor longus pollicis of man; it is in consequence of the existence of this muscular slip that the Orang is capable of bending the terminal phalanx of the thumb.

The *Adductor transversus pollicis* arose from the base of the third metacarpal bone and the distal extremity of the second metacarpal bone, and from the fascia over the interossei muscles between the two bony points named. The adductor muscles of the thumb in the Orang thus correspond very closely to the muscles of the same group in the human hand.

The *Flexor brevis pollicis.* The inner head of the muscle (the "interosseus primus volaris" of Henle, plate V, fig. *5 f.b.p.2*) arose from the base of the first metacarpal bone, and was inserted into the base of the first phalanx with the adductor obliquus pollicis. The outer head of the flexor brevis pollicis (plate V, fig. *5 f.b.p. 1*), arose from the anterior annular ligament and was inserted into the radial portion of the base of the proximal phalanx. Flemming[3] looked upon the flexor brevis pollicis as a single headed muscle. This view has been proved to be incorrect by Cunningham[4] who holds that in the foot as in the hand the flexor brevis of the first digit is always a double headed muscle, and man is no exception to the rule. In man the ulnar head has suffered diminution and has been suppressed by the great development of the adductor. The inner head is the muscle which Henle called the "interosseus primus volaris." It was Bischoff who first enunciated the view that such was the case in demonstrating the true significance of the interosseus

1 Loc. cit., p. 82.

2 Loc. cit., p. 183.

3 W. Flemming, "Ueber den Flexor brevis pollicis und hallucis des Menschen." Anatomischer Anzeiger, 1887, pp. 68, 269.

4 D. J. Cunningham, "The flexor brevis pollicis and the flexor brevis hallucis in man." Anatomischer Anzeiger, 1892, p. 206.

primus volaris of Henle, and Cunningham confirms him in every particular. In the case of the foot Flemming advanced an argument based upon the nerve supply, but his argument fails, because Cunningham has shown that Flemming followed Henle and Schwalbe in describing the nerve supply of the fibular head to be from the external plantar nerve, whilst throughout the entire class of the mammalia Cunningham has only once found this head thus supplied (*i.e.*, in the fox-bat), with this exception it is always supplied by the internal plantar, as is the tibial head. Even if Flemming were right regarding the nerve supply Cunningham holds that the point would not afford sufficient proof, as it has been shown that where two nerves approach one another, a tendency to variation in the supply to muscles occurs when they reach the confines of their distribution. Cunningham states that in only one instance was he able to trace the nerve supply of the interosseus primus volaris in the hand, and in that instance it appeared to come from the deep branch of the ulnar.

The *Abductor minimi digiti* (plate V, fig. *5 ab.m.d.*), arose from the pisiform bone and the annular ligament, and was inserted into the base of the first phalanx of the little finger on its ulnar side.

The *Flexor brevis minimi digiti* (plate V, fig. *5 fl.b.m.d.*) arose from the unciform bone and the annular ligament, and was inserted into the base of the first phalanx of the fifth digit on its ulnar side. In Fick's Orang a second head arose from the palmaris longus tendon.

The *Opponens minimi digiti* (plate V, fig. *5 op.m.d.*) arose from the unciform bone and the annular ligament, and was inserted into the whole length of the metacarpal bone of the little finger.

The short muscles of the thenar and hypothenar eminences have a greater or less extension of their fibres of insertion beyond the bony points already described, and blend with the extensor aponeurosis on the dorsal aspect of the digits. In this respect they resemble the interossei, and Langer would, from this circumstance, argue in favour of the theory that these muscles are modified interossei.

The Orang would appear to have a greater development of thumb muscles than obtains in the hand of man as far as the development of those muscles which act upon the metacarpal bone is concerned, but the movements of the terminal phalanx are obviously very weak, the flexor longus pollicis being absent or extremely rudimentary. Further, it would appear that adduction to the index is the most powerful movement attainable, as judged from the development of the muscles. The

1 Loc. cit., p. 184.

flexor brevis pollicis is also well developed, probably better than in man, and thus flexion of the first phalanx can be well accomplished. The inner head of the flexor brevis resembles that in man in being very feebly developed, and in being completely pressed into the deeper parts and covered over by the adductor obliquus, and according to Bischoff[1] a similar condition is found in the Gibbon. In the Gorilla, Bischoff[2] was unable to separate the outer head of the flexor brevis from the opponens, or the inner head from the adductor obliquus. It would appear from reference to the records of various authorities, that whilst great variations exist among apes in the degree of development of the short muscles of the thumb, they are nevertheless all represented in the different species. Even in the spider monkey (Ateles) according to Huxley, in which the thumb is functionless, being wholly rudimentary and buried under the skin, all the muscles, abductors, adductors, short flexors and opponens are present, the long flexor alone of the muscles usually found in this situation being absent. A variation sometimes occurs according to Fick[3] and others, in the insertion of certain fibres of the adductor into the shaft of the metacarpal bone of the thumb, thus constituting a second opponens.

The *Interossei* (plate V, figs. 6 and 7). The first dorsal interosseous muscle arose from the ulnar side of the base of the first metacarpal by one head, whilst the other head arose from the dorsal, radial and palmar surfaces of the second metacarpal bone. The second dorsal interosseous arose from the ulnar half of the dorsal surface of the second metacarpal bone, and from the dorsal, radial and palmar aspects of the third metacarpal. The third dorsal interosseous arose from the radial half of the dorsal surface of the fourth metacarpal, and from the dorsal, ulnar and palmar aspects of the third metacarpal. The fourth dorsal interosseous arose from the radial half of the dorsal surface of the fifth metacarpal, and from the dorsal ulnar, and palmar aspects of the fourth metacarpal bone.

The palmar origins of the dorsal interossei, above described, were in all instances particularly well developed, forming in fact larger fasciculi than those arising from the dorsal region. On the palmar aspect of the third metacarpal bone the palmar origins of the second and third interossei meet together over the proximal half of the bone. The muscles were inserted as in man.

---

1 Loc. cit. 1, p. 215.

2 Loc. cit. 2, p. 16.

3 Loc. cit. 2, p. 302.

The palmar interossei arose each by a single head from the metacarpal bone of the digit upon which it acts. The first palmar interosseous muscle arose from the palmar and ulnar surfaces of the second metacarpal, whilst the second and third palmar interossei arose from the palmar and radial surfaces of the fourth and fifth metacarpal bones respectively. They were inserted as in man.

The drawings (plate V) are faithful representations of the relations which existed, and one has reproduced in a diagrammatic fashion in fig. 4, plate IV, the relations of the interossei to the metacarpal bones as they appear in transverse section. The second, third and fourth metacarpal bones were thus completely surrounded by the interossei in the proximal two-thirds of their length.

Bischoff described[1] the interossei very fully in a large number of the lower apes and the anthropoid apes. He recognized the fact that there existed a palmar set of interossei as distinct and independent muscles. They vary in the number present in the different apes, but never exceed three, and were always developed in connection with the second, fourth and fifth digits. The double insertion of the various interossei, both palmar and dorsal, whereby they are on the one hand attached to the base of the proximal phalanx and on the other into the extensor aponeurotic expansion on the back of the phalanx, was first pointed out by Huxley[2] in anthropoid apes. The interossei and their attachments were fully described by Huxley in all four anthropoids. Bischoff found the interossei in the Gorilla developed as in man.[3]

The palmar portions of the dorsal interossei formed such very definite structures in my Orang that they attracted special attention. This segment of the dorsal interosseous muscle in fact resembles a palmar interosseous muscle, but this ventral segment is blended very intimately with the dorsal in the tendon of insertion of the muscle. The palmar interossei on the other hand remain independent structures throughout. This condition is very similar to that found in man, and, obviously, the description in most text books of human anatomy regarding these muscles is faulty. Gegenbaur,[4] however, describes and figures them in their correct relations. Hepburn[5] apparently found these ventral segments of the dorsal interossei, and, if I read his description aright, looked

1 Loc. cit. I, pp. 216, 224.

2 Loc. cit., Vol. I, p. 456.

3 Loc. cit. 2, p. 17.

4 C. Gegenbaur, "Lehrbuch der Anatomie des Menschen." Leipzig. Vol. I, p. 431. fig. 303.

5 Loc. cit., p. 174.

upon them as additional palmar interossei, and thus described six palmar interossei in the Chimpanzee instead of three. From one point of view Hepburn would appear to be justified in classing these ventral segments of the dorsal interossei with the palmar interossei, and this whole group of six muscles, as represented in my Orang, (plate V, figs. 6 and 7) might be referred to the intermediate layer of Cunningham which that author describes as constituting the "flexores breves." We shall return to the discussion of the interossei after describing the muscles of the foot.

In the dissection of the muscles of the lower extremity one found the fascia lata poorly developed, as compared with the similar structure in man.

The *Gracilis* arose from the body of the pubis by an origin 3.5 cm. wide, immediately external to the symphysis and corresponding in width of attachment to the depth of the symphysis. It did not extend to the descending ramus of the pubis; it was inserted into the inner aspect of the tibia by an expanded aponeurosis of insertion 3 cm. wide. The upper limit of the insertion is 3 cm. below the articular surface of the tibia. It forms a flat ribbon-like muscle varying in width from 2 cm. near its origin to 1 cm. near its insertion, and was supplied by the obturator nerve. Fick remarks on the strong development of this muscle in the Orang, and also observed the absence of any origin from the pubic ramus.

The *Sartorius*, a very poorly developed muscle, arose from the ilium below the anterior superior spine, and was inserted into the inner surface of the tibia, above and anterior to the insertion of the gracilis. This muscle was only about one-fifth the size of the gracilis, and was supplied by the anterior crural nerve. On the right side Rudolf found that the muscle divided into two tendons of insertion, the anterior being inserted into the inner aspect of the tibia in the position indicated above for the left side, the posterior joined with the fascia around the knee joint. Between these two portions passed an artery of considerable size, which was found to arise from the femoral one inch above the knee, and run down the inner side of the leg to the cleft between the first and second toes, where it disappeared between the heads of the first dorsal interosseous muscle; a vein accompanied the artery and entered the femoral vein one inch above the knee. Fick[1] described an artery, the *arteria genus suprema*, in the Orang as a large vessel as thick as the profunda arising above the knee and extending with the saphenous nerve

1 Loc. cit. 1, p. 35.

to the dorsum of the foot. The sartorius muscle is usually very feebly developed in the anthropoid apes as compared with man. Gegenbaur states[1] that the sartorius is as well developed in the anthropoid apes as it is in man, but this is by no means invariably the case—in my Orang it was very rudimentary, and Fick found it so also in the same animal. Bischoff, too, and Duvernoy[2] state that the muscle is weak in the Gorilla, whilst Gratiolet and Alix[3] found it weakly developed in the Chimpanzee. The attachment of the sartorius to the inner side of the knee joint, similar to that found by Rudolf, has been described in man (Testut).

The *Adductor longus* arose from the inner portion of Poupart's ligament and from Gimbernat's ligament and from the pubis extending 1 cm. along the bone on the superior part of the horizontal ramus immediately external to the pubic spine; it was inserted into the inner aspect of the femur, the line of insertion being 1.5 cm. long, the lower limit of this line being only 2 cm. above the internal condyle.

The *Pectineus*, lying in the same plane as the adductor longus at its origin, arose from the horizontal ramus of the pubis, the origin being 1 cm. wide, continuous there with the adductor longus as it passes backwards and downwards, wrapping itself around the shaft of the femur, and was inserted into the posterior aspect of the femur at the junction of the middle and upper thirds, the insertion being 2.5 cm. wide.

The *Adductor brevis* arose from the pubis immediately beneath the adductor longus, by an origin 1.5 cm. wide; it was inserted into the posterior aspect of the femur on a plane posterior to that of the pectineus. The muscle was supplied by the obturator nerve.

The *Adductor magnus*, a large bulky muscle, arose from the pubic bone opposite the whole extent of the symphysis immediately subjacent to the gracilis, and on the same plane as the adductor brevis at its origin. The attachment of origin extends back along the descending ramus of the pubis and the ascending ramus of the ischium to within 1 cm. of the tuberosity of the ischium. The lower, or inner border was thick and rounded, whilst the upper (or outer) was thin and attenuated. The lower part of the muscle was inserted by a rounded tendon into the internal condyle of the femur, the lowest fibres passing to the internal lateral ligament of the knee joint. The muscle above this point is inserted into the posterior aspect of the femur in a plane posterior to the

1 Loc. cit., (Lehrbuch) Vol. I, p. 439.

2 Loc. cit., p. 90.

3 Loc. cit., p. 186.

adductor brevis, longus and pectineus, extending as high up on the shaft as the lower limit of the upper fifth of the bone. The muscle is supplied by the obturator nerve. The femoral vessels crossed over the anterior surface of the adductor longus near its insertion, and passed through the adductor magnus.

The *Adductores femoris* are, according to Bischoff, particularly strongly developed in all apes. In the Orang he was only able to distinguish the adductors longus and magnus; in all other apes investigated by him, including the Gorilla, Chimpanzee and Gibbon, he found the adductor group in five muscles, not only the pectineus, adductor magnus, longus and brevis, but an additional muscle arising from the crest of the pubis. This additional muscle from the crest Duvernoy[1] described in the Gorilla as a part of the pectineus.

The *floor of Scarpa's triangle.* From without inwards, the floor was formed by the iliacus, psoas, pectineus and adductor longus. The adductor brevis was entirely hidden from view, and there was a triangular interval between the psoas and pectineus (with the base uppermost), the floor of which was formed by the anterior ligaments of the hip joint covering the head of the femur. Passing down in the inner portion of the triangle was the femoral vein, lying in direct contact with the ramus of the pubis, and the anterior capsule of the hip joint and the femoral artery lying upon the inner edge of the psoas. The anterior crural nerve was separated from the femoral vessels by an interval of 2 cm. at the base of Scarpa's triangle, and lay upon the iliacus muscle.

The *Psoas* arose from the bodies of the lumbar vertebrae, and from the transverse processes. A well-developed *Psoas parvus* lay on the anterior aspect of the psoas. It arose from the body of the first lumbar vertebra and was inserted into the pubis. Hepburn found a psoas parvus in each of the four anthropoids. Fick also found it in the Orang and Bischoff in the Gorilla. The *Iliacus* arose from the concavity of the ilium. These two muscles (constituting the ilio-psoas) were inserted into the lesser trochanter of the femur. They lay in the same plane at the base of Scarpa's triangle, but afterwards the psoas came to lie in front of the iliacus and was inserted into the upper part of the lesser trochanter; the iliacus on the other hand, fully four times as wide as the psoas, was inserted into the lesser trochanter and into the shaft of the femur for 1 cm. below.

The *Rectus femoris* (Plate VI, fig. 8, rect.) arose by a single head from

1 Loc. cit., p. 85.

the anterior margin of the ilium at a point 3 cm. below the anterior superior spine, the width of origin being 2 cm., lying behind the iliacus and in front of the gluteus minimus; it passed into the thigh to join the quadriceps extensor muscle in the usual way. There was no reflected head of origin. Hepburn[1] found the double origin in the Orang, Chimpanzee and Gorilla, but not in the Gibbon. In establishing homologies between the muscles of the thigh and of the arm Humphrey[2] considered the rectus in the thigh to represent the scapular part of the triceps in the arm; and the shorter deeper portion, extending more laterally, formed by the vasti and crureus in the thigh, as representing the humeral head of the triceps in the arm.

The *Vastus externus* (Plate VI, fig. 8, v.i.) arose from the anterior inter-trochanteric line and from a line skirting the lower part of the great trochanter. Posteriorly a part arose from the trochanter itself. This part of the origin of the vastus externus embraces the insertion of the scansorius. Below this point the vastus externus arose from the postero-external aspect of the femur as low as the condyle, its origin here being immediately in front of the insertion of the gluteus maximus.

The *Vastus internus* arose from the antero-internal aspect of the femur as high as the root of the neck, its origin extending down to the internal condyle.

The *Crureus* arose from the anterior aspect of the femur as high as the neck, extending down between the lines of origin of the external and internal vasti as in man. These various muscles united as in man to form the *quadriceps extensor cruris*. This muscle is developed in apes as in man.

The *Gluteus maximus* (Plate VI., fig. 8, g. max.) arose from the posterior part of the iliac crest, the back of the sacrum, coccyx, and the sacrosciatic fascia by an origin 6 cm. wide, and was inserted, the lower (posterior) fibres, by a rounded cord which was traced down the external aspect of the femur to the external condyle, being intimately attached to the fascia lata throughout its whole extent. Most of the superficial fibres converged to this rounded tendon and have thus a fascial insertion, whilst the deep fibres were inserted into the femur by an attachment 1.5 cm. wide immediately external to the vastus externus, behind that muscle; the biceps lying posteriorly. The gluteus maximus was thus a very well developed muscle, and the proverbial

1 Loc. cit., p. 329.

2 Humphrey, "On the Disposition and Homologies of the Extensor and Flexor Muscles of the Leg and Forearm." Journ. of Anatomy and Physiology, Vol. III, 1869, p. 320.

diminutive size of the nates in apes, which is usually ascribed to the ill-developed glutei muscles, was not demonstrated in my specimen. Fick also[1] observed that the gluteus maximus, though relatively weak, was still a strong muscle in his Orang, its weight being 432 grms. whilst the gluteus maximus in a lean man was found by Langer to be 366 grms.

The *Gluteus medius* (Plate VI., fig. 8) was a large well developed muscle, which arose from the dorsal surface of the ilium as far forwards as the anterior superior spine, and backwards over the whole extent of the iliac crest, and from the dorsal surface of the ilium below this, some fibres coming from the posterior sacro-iliac ligament. Along its posterior border it is joined by the pyriformis muscle.

The *Pyriformis* is a narrow ribbon-like muscle arising from the anterior surface of the sacrum. It joins the gluteus medius on its deep aspect and proceeds to its insertion into the upper part of the great trochanter, as in man. It was intimately connected with the gluteus medius, but it was possible to separate them entirely from one another. It is customary, according to Bischoff, to find these two muscles closely connected in apes. Hepburn found them blended in all four anthropoids. The muscle is present in all apes.

The *Gluteus minimus* (Plate VI., fig. 8, g.min.) arose from the margin of the great sacro-sciatic foramen, and slightly from the dorsal surface of the ilium below this by an origin 2.5 cm. wide; it passed outwards beneath the pyriformis and the gluteus medius and was inserted into the anterior margin of the great trochanter.

The *Scansorius* (Plate VI., fig. 8, scan.) arose from the anterior margin of the ilium below the anterior superior spine by a broad base of origin 3.5 cm. wide, the muscle being triangular in shape. It was inserted by its apex into the anterior border of the great trochanter by an insertion 1.5 cm. wide immediately in front of the gluteus medius and is embraced at its insertion by the vastus externus. This well-developed muscle lay at its origin between the gluteus medius behind and the iliacus in front. The narrow ill-developed sartorius separates the iliacus from the scansorius, whilst the rectus also separates these two muscles along the inner border of the scansorius. The muscle was very distinct and separate from both the gluteus medius and the gluteus minimus.

The scansorius is described by Fick as a typical Orang muscle. It is certainly best developed as a separate muscle in the Orang, whilst in the other apes (both anthropoid and lower apes) it is more or less

1 Loc. cit. 1, p. 36.

blended with other muscles. Fick[1] described it as a muscle wholly separate and distinct in his first Orang, whilst in the second Orang dissected by him[2] the muscle was superficially united with the gluteus medius. Bischoff[3] also describes the scansorius in the Orang as a separate muscle, and so too do Huxley,[4] Owen,[5] Hepburn,[6] and Langer,[7] whilst Chapman[8] figures the muscle, but looks upon it as a portion of the gluteus minimus. Gratiolet and Alix[9] in their description of the Chimpanzee describe the gluteus medius and the gluteus minimus together as forming a single muscular mass, and the anterior portion of the muscle sheet thus described would correspond to the scansorius, although not so designated by them, and certainly not existing as a muscle completely separate in their specimen. Hepburn[6] however describes it as a separate muscle in the Chimpanzee, as do also Huxley[10] and Owen,[5] whilst Bischoff[3] and Champneys[11] describe it in the Chimpanzee as closely connected with the gluteus minimus. Macalister[12] found it attached to the gluteus medius in one Chimpanzee and to the minimus in another. In the other anthropoids, namely the Gibbon and the Gorilla, it has not been described as a separate muscle save in the fœtal Gibbon where Deniker[13] found it well marked, whilst in the fœtal Gorilla it was not completely separated from the gluteus minimus. Bischoff[14] and Hepburn[15] both found it united with the gluteus minimus in the Gibbon, whilst Huxley[16] states that it is not very distinctly represented in that animal. In the Gorilla it has not been described as a separate muscle. Duvernoy in his description of this region in the Gorilla[17] makes no mention of the scansorius, Bischoff[18] says it fails in the Gorilla, but the gluteus minimus arises

1 Loc. cit., p. 36.
2 Loc. cit. 2, p. 303.
3 Loc. cit. 1, p. 224.
4 Loc. cit., Vol. I, p. 506.
5 Loc. cit., p. 68.
6 Loc. cit., p. 325.
7 Loc. cit., p. 186.
8 Loc. cit., p. 163.
9 Loc. cit., p. 179.
10 Loc. cit., Vol. I, p. 428.
11 Loc. cit., p. 193.
12 Loc. cit., p. 504.
13 Loc. cit., p. 168.
14 Loc. cit. 1, p. 224.
15 Loc. cit., p. 325.
16 Loc. cit., Vol. I, p. 647.
17 Loc. cit., pp. 84, 85.
18 Loc. cit. 2, p. 19.

from the anterior iliac margin, and similarly Hepburn[1] describes it as blended with the gluteus minimus. On the other hand Macalister[2] describes it as uniting with the gluteus medius (not minimus) in the Gorilla. Concerning the occurrence of the muscle among the lower apes, Huxley[3] tells us that in Cynopithecinæ the scansorius is found, but that it is sometimes blended with the gluteus minimus. Bischoff,[4] whilst he states that it fails in the lower apes generally, mentions that it is represented by a weak bundle in Cynocephalus, Cercopithecus and Macacus.

Thus we find that the scansorius is best developed as a separate muscle in the Orang and the Chimpanzee among anthropoid apes, and in all other apes it varies very considerably in its development, and is usually blended with the gluteus minimus or the gluteus medius, commonly the former.

The scansorius would thus appear to have more or less intimate connection with the gluteus medius and minimus. Fick combats the suggestion of Henke that it is developed from the iliacus, on the ground that the sartorius muscle intervenes between these two muscles; in my specimen I not only found the sartorius intervening but also the rectus. Bischoff, too, refers to the rectus intervening between the ilio-psoas, and what he believes to be the representative of the scansorius in the Gibbon.

The function of the scansorius muscle was demonstrated by Owen,[5] who called it the "Invertor femoris," holding that it was a powerful rotator of the thigh and could have very little effect in drawing the thigh up. He states regarding the muscle "that it appears rather to have reference to that structure in the hip joint which, in the Orang especially, from the absence of the ligamentum teres, and in the Chimpanzee, from the yielding texture of that ligament, permits a greater extent of inward rotation than can be accomplished in man." Fick[6] questions the appropriateness of calling this muscle the climbing muscle. Flexion of the femur which is carried out to a limited extent by the scansorius, is a movement performed in climbing, but there are many other more powerful flexors of the femur. Then the scansorius rotates the thigh inwards in a forcible manner, and this is apparently its chief action. The ape, however, does not appear to rotate the thigh inwards in

1 Loc. cit., p. 325.
2 Loc. cit., p. 504.
3 Loc. cit., Vol. II, p. 40.
4 Loc. cit. 1, p. 224.
5 Loc. cit., p. 68.
6 Loc. cit. 1, p. 36.

climbing. If it did so it would necessarily throw the leg and foot outwards at the same time, in consequence of the fact that the knee is flexed and never straight in the Orang ; as a matter of fact, in climbing upwards the ape applies the sole of the foot to the tree, whilst the thigh is abducted and rotated out. The ape thus climbs in a different fashion from that in which a boy would climb a pole, with thighs adducted and rotated in and with the knees hard pressed inwards. Fick states, however, that man in climbing with naked feet, as for example, the child of a Malay negro, will climb as the ape does, with the soles of the feet applied to the trunk of the tree and with thighs rotated out. This action of flexion of the femur with rotation outwards is not the function of the scansorius but of the ilio-psoas. In this sense, therefore, the name scansorius is inapplicable. Fick admits that the scansorius may be brought into action when the ape is climbing from one branch to another, when, he observes, the animal very frequently performs this movement with flexed thigh rotated inwards.

The scansorius muscle was first described and named by Traill (quoted by Bischoff, from Memoirs of the Wernerian Nat. His. Soc., Vol. III., p. 29, 1821) in the Chimpanzee. According to Testut[1] there is frequently found in man a small fasciculus more or less differentiated from the gluteus minimus anteriorly, which passes to be inserted into the great trochanter ; this Testut considers the representative of the scansorius in man. This fasciculus, he adds, exists normally in a large number of mammals.

The weak development of the glutei muscles in general in man is to be ascribed to the erect attitude, whilst again the comparatively strong development of that part of the gluteus maximus in the ape which proceeds down the thigh—in my Orang as far as the external condyle—is associated with climbing, the thigh being carried back with considerable force by that part of the muscle.

The *Tensor fasciæ femoris* was entirely absent in my Orang. Bischoff states regarding it that the fascia lata is more weakly developed than in man, and the muscle is scarcely present as an independent muscle in any instance, but may be represented by a few fibres derived from the anterior part of the gluteus maximus. This agrees with the freer and more isolated action of the thigh muscles in apes, as is necessary in climbing, whilst in man these muscles are required to be more firmly bound together in the erect position and in walking.

---

1 Loc. cit., Vol. I. pt. 2. p. 837.

The *Obturator internus* arose as in man, and passed over the lesser sciatic notch, where it is joined by a well-developed *Gemellus inferior* and a less strongly developed *Gemellus superior*. The muscle was inserted into the upper part of the great trochanter behind the insertion of the pyriformis and in contact with the capsule of the hip joint. Fick likewise describes the superior gemellus as weak in the Orang, whilst Hepburn found them both well developed. Bischoff in the Gorilla found the obturator internus completely blended with the quadratus femoris.

The *Obturator externus* arose as in man and, appearing between the obturator internus and quadratus femoris, it found insertion into the inner part of the great trochanter just behind the obturator internus.

The *Quadratus femoris* was a well-developed muscle. It arose from the outer part of the ischial tuberosity by an origin 1.5 cm. wide and was inserted into the posterior part of the great trochanter and the shaft of the femur below this process. Langer[1] found the muscle closely connected with, and hardly separable from, the adductor magnus, and he therefore looked upon it as one of the adductor group. The muscle is sometimes blended with the great adductor in man.

The *Semitendinosus* arose from the tuberosity of the ischium and the bone immediately in front of this by an origin 1 cm. wide, and was inserted into the tibia, the tendon expanding to have a wide attachment (2 cm.) into the antero-internal surface of the tibia behind the insertion of the gracilis. Rudolf on the right side found a second head of origin coming from the ischial ramus and joining the muscle 1½ inches from its insertion.

The *Biceps* arose from the outer part of the tuberosity of the ischium, immediately posterior to and slightly in front of the semitendinosus. The two were closely associated at their origin. The muscle was inserted along the whole length of the lower two-thirds of the shaft of the femur, immediately behind the origin of the vastus externus, also into the external lateral ligament of the knee joint, the external tuberosity of the tibia, the head of the fibula and into the fascia on the outer surface of the upper part of the leg. Associated with this muscle is another (the femoral head of the Biceps in man) which arose from the shaft of the femur immediately behind (*i.e.*, internal to) the line of the femoral insertion of the biceps as described above. The line of origin was 4.5 cm. wide. The muscle passed to be inserted into the fascia of

1 Loc. cit., p. 187.

the leg extending downwards from the level of the knee joint; the fascia over the muscles of the leg being here very strongly developed. Fick[1] describes the ischio-femoral portion of the biceps as the direct antagonist of the scansorius, the action of the former muscle being to extend the hip and to rotate it outwards; both these muscles are absent in man. Langer[2] describes the long head of the biceps as in part going to be inserted into the patella, and he characterizes it as the great "sprungmuskel" which, in quadrupeds, is capable of extending all three joints, hip, knee and ankle. In Langer's Orang connection with the tendo Achillis alone was absent. The ischio-femoralis is sometimes joined with the gluteus maximus in the Orang, but more frequently is completely separate. In the Gorilla, Bischoff[3] describes the two heads of the biceps, but states that the long head is not inserted into the linea aspera as in the Orang, but passes to the head of the fibula and the fascia cruris. In the Chimpanzee and the Gibbon, according to the same authority, the Biceps is most human-like but extends also into the fascia cruris. In the lower apes the biceps has only one head—the long head—which is inserted, not into the fibula, but into the tibia; this fact is noted by Bischoff and by Huxley.[4] Hepburn found both heads present in the Orang, and, whilst one was inserted into the fibula and the other into the tibia, there was no femoral attachment. The biceps has been found in rare cases inserted in part into the tendo Achillis in man (Testut).

The *Semimembranosus* arose external to the point of attachment of the semitendinosus from the posterior part of the tuberosity of the ischium and the bone immediately in front of this (0.75 cm. wide); it was inserted into the inner aspect of the head of the tibia.

The absence of a ligamentum teres in the hip joint was noted. No vestige of this structure could be found; the head of the femur presenting an unbroken surface smooth throughout. One could not determine any definite ilio-femoral ligament, although the capsule of the hip-joint was thickened anteriorly in the line of its usual development.

The shortness of the hamstring muscles in the Orang and their low attachment, removed some distance below the knee, prevent complete extension of the leg at that joint, and this inability to extend at the knee is necessarily still further increased when the hip-joint is flexed.

---

1 Loc. cit. 1, p. 39.

2 Loc. cit., p. 187.

3 Loc. cit. 2, p. 21.

4 Loc. cit. Vol. II, p. 40.

A strong fascia covered the muscles of the calf. The anterior annular ligament of the ankle-joint was a well-developed structure consisting of two distinct bands, the upper passing from the internal malleolus outwards to be attached to the lower part of the fibula; the lower having a broad attachment to the external malleolus, becomes somewhat narrowed as it is attached to the fascia on the inner side of the foot below the internal malleolus. The external annular ligament too was well developed as it passed over the peronei muscles, as was also the internal annular ligament over the structures at the inner ankle.

The *Tibialis anticus* arose from the anterior aspect of the upper half of the tibia, from the external tuberosity and the interosseous membrane, and from the fascia over the muscle. The muscle became tendinous immediately above the ankle, where two tendons are readily distinguishable. The smaller one, which arose from the fleshy fasciculi of the anterior and outer part of the muscle, was inserted into the base of the first metatarsal bone at the junction of the inner and plantar surfaces. The larger tendon (three times the size of the former) was inserted into the internal cuneiform bone. The slip inserted into the first metatarsal bone acts as a strong abductor of the great toe, as does also the extensor longus hallucis.

The tibialis anticus in certain of the anthropoid apes is more or less completely divided into two muscles. In man we have a single muscle, and a single tendon which, however, divides at its extremity to be inserted into the internal cuneiform and the first metatarsal bone. This double insertion in man is an indication of the complete separation into two portions occurring in some apes. In the Orang and Chimpanzee Bischoff[1] found this division complete, and, in fact, in the Chimpanzee he found a third tibialis anticus arising in common with the extensor longus digitorum, but completely separated from it, and dividing into two tendons at the ankle to be inserted into the inner margin of the foot. In the Gibbon, Bischoff found a single muscle with a single tendon passing to the internal cuneiform bone. Huxley,[2] however, found a double insertion of the muscle in that animal. In the Gorilla, Bischoff[3] and Duvernoy[4] describe the muscle as in man, its tendon dividing for insertion into the first metatarsal and the internal cuneiform. In all other apes, Bischoff asserts, the tibialis anticus is double. It would appear, therefore, that in all apes the double insertion is almost

1 Loc. cit. 1, p. 227.

2 Loc. cit., Vol. I, p. 648.

3 Loc. cit. 2, p. 21.

4 Loc. cit., p. 94.

invariable; in this respect it may be compared to the extensor ossis metacarpi pollicis in the hand.

The *Extensor longus hallucis* arose from the upper fifth of the fibula and from the interosseous membrane, the line of origin being very short, and was inserted into the great toe, with similar relations to those in man. Fick[1] observed in an Orang a tendon given by this muscle to the second toe. Bischoff states that in all apes this muscle resembles that of man, but, except in the Gibbon, it does not extend along the dorsum of the foot as in man, but goes with the tibialis anticus to the inner side (the latter muscle being attached to the internal cuneiform), and runs along the inner margin of the foot to the first phalanx. The muscle must in its direction act on the great toe as an abductor as well as an extensor. In the Gibbon alone the tendon runs a course similar to that in man.

The *Extensor longus digitorum* arose from the internal tuberosity of the tibia and the intermuscular septum, also from the head of the fibula and the interosseous membrane, the origin being only 1.5 cm. wide. It was inserted into the four outer toes.

Extensor brevis digitorum arose from the outer and superior surfaces of the os calcis. It was closely associated at its origin on the outer side of the foot with the insertion of the peroneus brevis. It was inserted into the four inner toes, having a similar relationship to the extensor longus digitorum as in man; that for the great toe formed a separate and distinct muscle, running almost at right angles to the main part of the muscle, and passed to the great toe with the extensor longus hallucis. Duvernoy[2] describes this slip in the Gorilla as a separate muscle of the great toe. Langer[3] describes in the foot a similar interdigital membrane to that found in the hand, the toes being thus even more sunken in the foot than are the fingers in the hand.

The *Peroneus tertius* was absent, as is the case apparently with all apes, both the anthropoids and the lower apes. This muscle is peculiar to man among mammals, and there is some evidence that its development has to do with the erect attitude assumed by man. Ramsay Smith[4] believes that it serves an important function in preventing spasmodic extension of the ankle joint in ordinary walking. This, according to Smith, occurred in cases where the muscle was paralysed.

1 Loc. cit. 2, p. 303.

2 Loc. cit., p. 103.

3 Loc. cit., p. 190.

4 W. Ramsay Smith, "The Functions of the Peroneus Tertius Muscle," Edinburgh Medical Journal, 1882, p. 632.

The *Peroneus longus* arose from the head of the fibula on its outer aspect, and from the intermuscular septum, the line of origin being 2 cm. long. The musculo-cutaneous nerve passed between the upper part of the muscle and the fibula; the muscle became tendinous at the junction of the lower and middle thirds of the leg; the tendon grooved the cuboid bone, and passing inwards across the sole of the foot, it was inserted into the base of the first metatarsal bone at the junction of the plantar and outer margins. The peroneus longus had also a very definite slip of insertion into the fifth metatarsal bone. Fick[1] also describes this double insertion in the Orang.

The *Peroneus brevis* arose over 4.5 cm. of the outer side of the fibula, along an oblique line extending from above and in front, downwards and backwards to the posterior aspect of the bone immediately above the external malleolus. The upper limit of its origin was as high as the junction of the upper and the middle thirds of the bone. It was inserted into the base of the fifth metatarsal bone, and into a tendinous arch extending from the os calcis to the base of the fifth metatarsal bone ("abductor ossis metatarsi quinti" of Huxley). This extensive and strong insertion band of the muscle gives rise to certain fibres of the abductor minimi digiti. Some of the tendon fibres of the peroneus brevis were directly continuous with the peroneus longus tendon in the sole.

Bischoff,[2] in comparing the peroneus longus in man and apes, refers to the fact that on account of the saddle shape of the joint between the cuneiform and the first metatarsal, and of the more isolated position of the great toe in the ape as compared with man, the peroneus longus in the ape acts in bringing the great toe into opposition with the other toes, whilst in man it acts on the anterior part of the foot as a whole.

Bischoff describes another muscle in the ape, the *Peroneus parvus*.[3] This muscle, he says in lower apes exists as a fourth peroneus. It lies between the longus and brevis arising from the fibula. It becomes tendinous in the leg, and extending to the outer margin of the foot passes to the first phalanx of the little toe, where it unites with the tendon of the flexor digitorum communis longus. This muscle, Bischoff states, evidently corresponds with the well-known tendon which almost always in man goes from the tendon of the peroneus brevis and

1 Loc. cit. 1, p. 42.

2 Loc. cit. 1, p. 229.

3 Loc. cit. 1, p. 230.

joins the extensor tendon of the little toe, derived from the extensor digitorum communis longus. Huxley[1] describes this muscle in the lower apes ; he calls it the *Peroneus quinti digiti.* The muscle appears to be very uncommon in the anthropoid apes, although Bischoff thought that possibly a tendon coursing along the outer margin of the foot, which proceeds from the tendon of the peroneus brevis and is inserted with the extensor tendon of the little toe, might be looked upon as a rudiment of the peroneus parvus in the Gorilla. He found this tendon also in the Chimpanzee, as also did Gratiolet and Alix.[2] This tendon has apparently not been found in the Orang, but Huxley[3] describes in the Chimpanzee a muscular slip arising from the calcaneum apparently detached from the abductor minimi digiti, and ending in a tendon inserted into the base of the fifth metatarsal bone. This, Huxley suggests, might be called the "*abductor ossis metatarsi quinti.*" This corresponds precisely to the tendinous arch which I describe in the Orang in connection with the insertion of the peroneus brevis, and possibly represents a rudiment of the peroneus parvus.

Fick[4] has described a peroneous parvus in the Orang. Hitherto it was held that it did not exist in anthropoids, and apparently it is of rare occurrence among those apes, as this is the only instance in which I find its presence noted, although carefully sought for by various observers.

Ruge[5] makes some interesting observations on the peroneal group of muscles. He considers that the peroneus longus tendon in the mammalia wanders from the anterior to the lateral part of the limb. Thus in carnivora it originally lies on the anterior surface of the fibula, in rodents the tendon at one time lies upon the lateral aspect of the external malleolus and at another time behind it. In the ape the tendon lies in a special synovial sheath separated from the brevis, whilst in man they lie both together in the same synovial sheath. Ruge evidently considers the extensor brevis digitorum to be derived from the peroneal group, and represents it as wandering toward the dorsum of the foot, as would appear by studying its relation in different mammals. In marsupials, only two bellies pass over for insertion into the first and second toes. In rodents and insectivora three bellies exist for the first, second and third toes; and in carnivora, apes, and man, there

1 Loc. cit., Vol. II, pp. 40, 94, 124.

2 Loc. cit., p. 198.

3 Loc. cit., Vol. I, p. 429.

4 Loc. cit. 1, p. 42.

5 Dr. George Ruge, "Untersuchung über die Extensorengruppe am Unterschenkel und Fusse der Säugethiere." Morphologisches Jahrbuch, Vol. IV, 1878, p. 592.

are muscle bellies for four toes, viz.: the first, second, third and fourth, whilst that for the fifth toe still retains its original position among the peronei.

The *Gastrocnemius*. The outer head arose from the posterior aspect of the external condyle, and by a few fibres from the posterior ligament of the knee joint. The fibres of origin were closely associated with the flexor digitorum fibularis, the latter having a femoral origin behind the external condyle immediately internal to and above the place of attachment of the gastrocnemius. The inner head arose from the femur immediately above the internal condyle and from the posterior ligament of the knee joint. Langer and Fick both observed the connection of the outer head with the flexor digitorum fibularis. The muscle is not nearly so well developed as in man.

The *Soleus* arose by a narrow attachment (1 cm. wide) from the posterior part of the head of fibula; this was joined by a delicate, thread-like, distinctly tendinous structure which descends from the outer and posterior surface of the tibia. Macalister[1] found a trace of a tibial head in the Chimpanzee, but all other observers (Huxley, Fick, Langer, Bischoff, etc.,) state that the tibial head of the soleus is absent in all apes. The soleus and gastrocnemius unite in a tendo Achillis which is wholly tendinous at a point 3 cm. above the heel. In Fick's[2] Orang the fleshy fibres of the muscle extended down to its insertion into the os calcis, and this condition is held by him to be characteristic of anthropoids as compared with that found in the lower apes and in man. Bischoff agrees with this statement excepting in the case of the Gibbon, in which the tendo Achillis, according to him, is developed as in man.

The *Popliteus* arose from the outer condyle of the femur within the knee joint passing through the posterior ligament of the knee. The muscle was overlaid at its origin by the outer head of the gastrocnemius and the femoral head of the flexor longus hallucis. It was crossed about its middle by the inner head of the gastrocnemius. Rudolf found on the right side that its nerve entered the superficial surface. It was inserted into the posterior surface of the tibia in its upper fifth and along the inner border of that bone extending down from the internal tibial condyle for one-fourth of the length of the bone. Langer and Fick both describe sesamoid bones in connection with the tendons of origin of the popliteus in the Orang. Humphrey[4] looks upon the popliteus

1 Loc. cit., p. 205.

2 Loc. cit. 1, p. 40.

3 Loc. cit. 1, p. 228.

4 Loc. cit., p. 328.

in the leg as the homologue of the pronator radii teres in the forearm. The occasional second head of origin of the muscle from the fibula in man may correspond to the ulnar origin of the pronator. Bischoff[1] admits that pronation is possible to some degree in the knee of the ape, whilst in man of course the popliteus acts only as a flexor. Melzer[2] considers the homologies to be as follows:

Supinator longus.....	.....Gastrocnemius	inner head.
Pronator teres (humeral head)		outer head.
Pronator teres (ulnar head).	.....Popliteus.	

Macalister[3] looks upon the inner head of the gastrocnemius as the homologue of the pronator radii teres. It is superficial and not deep like the popliteus, and this fact he considers to be in favour of his hypothesis.

The *Plantaris* was absent and it would appear that the muscle is very rarely present in anthropoid apes. The only instance in which it was found in the Orang was in that dissected by Sandifort, who is stated by Fick[4] to have found it in that animal. It is frequently absent in man. Whilst the plantaris is almost invariably absent in anthropoid apes, it is well-developed, according to Bischoff,[5] in the lower apes (Cynocephalus, Cercopithecus, Macacus and Pithecia), forming a strong tendon passing under the posterior part of the os calcis, and it may be followed into the sole where it joins the plantar fascia. Bischoff,[6] however, found a slightly developed plantaris arise on both sides in the Chimpanzee, and in this animal, too, it has been described by Macalister[7] as present on the right side in one Chimpanzee and absent on both sides in another Chimpanzee. It is, however, frequently absent in this animal, and with the exception of the one instance recorded by Sandifort in the Orang, it has not been found in any of the other anthropoid apes, although carefully sought for, and its absence recorded by various authors. The plantaris in the leg doubtless corresponds to the palmaris longus in the forearm and has the same relation to the plantar fascia that the latter muscle has to the palmar fascia (see page 33). Thus Sutton[8] holds that the plantar fascia is derived from the degeneration of the distal end of

1 Loc. cit. 2, p. 23.

2 W. Melzer, "Zur Homologie der menschlichen Extremitäten." Internationale Monatsschrift fü Anatomie und Physiologie, Vol. XI, 1894, p. 209.

3 A. Macalister, "On the Arrangement of the Pronator Muscles in the Limbs of Vertebrate Animals." Journ. of Anat. and Phys., Vol. III, 1869, p. 340.

4 Loc. cit. 1, p. 41.

5 Loc. cit. 1, p. 229.

6 Loc. cit. 2, p. 22.

7 Loc. cit., p. 505.

8 Loc. cit., p. 16.

the plantaris muscle. We find the muscle in a more fully developed condition in the lower mammalia. Cunningham[1] described it in the marsupials. In Thylacinus this muscle arises in common with the outer head of the gastrocnemius and remains fused with its under surface for a considerable distance. It ends in a strong tendon which proceeds downwards along the inner side of the tendo Achillis to the heel, where it expands and, passing superficially to the tendo Achillis, enters the sole. Here it spreads out in the form of a plantar fascia which divides into three slips for the index, medius and annularis. The plantar fascia is not attached to the subjacent muscles, and each of its terminal slips bifurcates to embrace the metatarso-phalangeal joint and is attached to the ligamentous structures around that articulation. Sutton describes a somewhat similar arrangement in the Armadillo. In higher mammalia it would appear that, owing to the backward growth of the os calcis the plantaris is shut off from its direct connection with the plantar fascia, and terminates by being inserted into the os calcis itself.

The *Flexor digitorum fibularis* (the flexor longus hallucis of human anatomy), was a very large bulky muscle of extensive origin from the posterior aspect of the external femoral condyle where it embraced the origin of the outer head of the gastrocnemius, also from the posterior and external lateral ligaments of the knee joint, the posterior aspect of the fibula as low as the junction between the middle and lower thirds, also from the fascia between it and the peronei muscles.

The *Flexor digitorum tibialis* (the flexor longus digitorum of human anatomy), was also a very bulky muscle and arose from the posterior aspect of the tibia immediately external to the attachment of the popliteus muscle as high up as the head of the tibia; it was attached along a line running downwards and inwards to the inner margin of the tibia at the junction of its upper and middle thirds. This portion of the muscle is joined by a well developed band of fibres descending from the fascia over the lower part of the popliteus muscle. These fibres may be traced upwards, and are found attached to the inner tuberosity of the tibia. Another very distinct head of origin of this muscle arose from the fascia over the tibialis posticus muscle, and extended as far as the inner margin of the fibula.

The two muscles just described, viz., the flexor digitorum fibularis

1 D. J. Cunningham, "Report on the Marsupialia, with an Account of the Comparative Anatomy of the intrinsic Muscles and Nerves of the Mammalian Pes." Report of the Voyage of H. M. S. "Challenger," Vol. V, 1882, Part XVI, p. 41.

and the flexor digitorum tibialis, both became tendinous immediately above the inner ankle, and proceeded towards the sole of the foot. They passed behind the inner ankle, where they lay in separate osteo-fibrous canals, separated from one another by a well-defined fibrous partition, the nerves and vessels which pass into the sole lying on a more superficial plane immediately over the fibrous septum between the muscles. The flexor digitorum fibularis was confined in a groove in the posterior part of the astragalus and passed immediately subjacent to and in contact with the sustentaculum tali of the os calcis, the flexor digitorum tibialis occupying a position anterior to this. In the sole of the foot the two muscles crossed one another, the tendon of the flexor longus tibialis occupying the more superficial position. From the flexor longus tibialis a considerable contribution was given to the flexor brevis digitorum to be presently described, and from the same source the deep flexor tendons were supplied for the second and fifth toes, whilst the deep flexor tendons for the third and fourth digits passed from the flexor digitorum fibularis. Four *lumbricales* existed in connection with these deep flexors. The first lumbrical was attached solely to the tibial side of the tendon of the flexor digitorum tibialis for the second toe. The second and third lumbricals were connected with the tibial side of the tendon of the flexor digitorum fibularis for the third aud fourth toes. The fourth lumbrical arose by two heads, one from the tibial side of the flexor digitorum tibialis of the fifth toe, and the other head from the fibular side of the tendon of the flexor digitorum fibularis of the fourth toe.

The *Flexor brevis digitorum* was closely associated in the sole with the tibial and fibular flexors. It was a well-developed muscle, and arose from the inferior and inner aspects of the os calcis by an origin 2 cm. wide. It was inserted into the four outer toes. The tendon for the third toe was the strongest, and received the bulk of the fleshy fibres of the muscle. This tendon split into two portions, which passed to be inserted into the ventral aspect of the middle phalanx at its base, allowing the tendon of the flexor digitorum fibularis to perforate and pass beneath in the usual fashion. The division to the second toe was similar in its relations, but was not as strongly developed. The division for the fourth toe was very delicate, its tendon being very fine and thread-like. This delicate tendon was joined by a well-developed tendon, which was derived from a bundle of fleshy fibres in the sole, having their origin from the flexor digitorum tibialis opposite the inner ankle. The tendon for the fourth toe, being so constituted by fibres derived from the two muscles named, passed on and split to allow the perforating tendon (flexor digitorum fibularis) to pass beneath, and had

similar attachments in the fourth toe to those described for the short flexor in the third toe. The tendinous slip for the fifth toe was extremely delicate, and was joined by a slip (which seemed to be wholly tendinous) from the flexor digitorum tibialis of similar character and connections as that described for the fourth toe. It will be observed that the flexor digitorum fibularis gave no tendon for the hallux.

It would appear that the distribution of the flexor digitorum fibularis to the third and fourth toes is very constant, occurring, according to Bischoff, in all apes,[1] and further in all apes save the Orang, according to the same authority, a tendon is given by this muscle to the great toe, but this tendon is extremely weak, excepting in the Gorilla, where Bischoff states that a very strong tendon to the hallux is found.[2] Duvernoy[3] describes and figures the flexor longus hallucis in the Gorilla as giving a very powerful tendon to the great toe, and also supplying the third and fourth toes. The tendon to the hallux fails utterly in the Orang. In Huxley's Gibbon,[4] the flexor digitorum fibularis was distributed to the first, second, third and fourth digits, and the flexor digitorum tibialis was supplied to the fifth digit only.

There can be no doubt that the flexor longus fibularis represents the flexor longus hallucis in man, and the flexor longus tibialis the flexor longus digitorum in man. Dobson[5] has traced the homologies of the long flexor muscles of the foot throughout the mammalia. In the human subject Turner[6] has shown that there is frequent communication in man of the flexor longus hallucis with the flexor tendons of the four outer toes. Thus, in fifty specimens dissected, he found that in eleven cases such a communication existed with the second toe only; in twenty cases, with the second and third toes, and in eighteen, with the second, third and fourth toes, whilst, in one specimen, there was a communication with the four outer toes. Schulze[7] gives somewhat similar results, but has not observed a communication with the fifth toe.

Huxley[8] observed a contribution to the flexor brevis digitorum from the flexor digitorum tibialis in the Gorilla, and in the Orang he also

---

1 Loc. cit. 1, p. 232.

2 Loc. cit. 2, p. 30.

3 Loc. cit. p. 112.

4 Loc. cit., Vol. I, p. 648.

5 G. E. Dobson, "On the Homologies of the Long Flexor Muscles of the Feet of Mammalia, with Remarks on the Value of their Leading Modifications in Classification." Journ. of Anat. and Phys., Vol. XVII, 1883, p. 142.

6 Loc. cit., p. 181.

7 Loc. cit., p. 1.

8 Loc. cit., Vol. I, pp. 538, 596.

noted a contribution similar to that I have described above in my Orang. He observed a remarkable deviation from the human type in Cynopithecinæ where the flexor brevis pedis arose partly from the tendon of the plantaris (where this passes over the pulley-like hinder extremity of the calcaneum, to end in the plantar fascia) and partly from the long flexor tendons, so that it completely lost its connection with the os calcis.[1] Again, Turner[2] observed in man that the tendon of the short flexor for the little toe in one case arose from the common flexor tendon previous to the sub-division of that structure. Similar communications between the short and long flexors have been recorded in the apes by Bischoff.[3] Regarding variations in origin in man it may be noted that the flexor brevis sometimes arises from the cuboid bone, the cuneiform bones, or the bases of the metatarsal bones (Testut).

The *Flexor accessorius* (The "*Caro quadrata*" of Sylvius). On the left side of my Orang there was not a vestige of this muscle, whilst on the right side Rudolf found a very thin muscle possessing two heads of origin from the os calcis, and inserted into the tendon of the flexor digitorum tibialis.

Bischoff[4] states that he has never found the accessorius in any anthropoid ape. But Langer,[5] Fick,[6] and Chapman[7] have found it weakly developed in the Orang. Hepburn[8] and Gratiolet and Alix[9] have found it in the Chimpanzee. Huxley[10] found it well developed in the Gorilla; it was also found in that animal by Hepburn and Macalister. As far as I am aware it has not been reported in the Gibbon. It would appear to be absent in most cases in the Gorilla. On the other hand according to Bischoff and Huxley it is present in the lower apes.

It has been suggested that the accessorius is present in young anthropoids but disappears in the old; this view is however not tenable as it has been described as absent in many young animals. Fick points out that in the foot of the Orang an accessorius muscle is not necessary, as the foot is always strongly supinated and the flexor tendons pull in a straight direction and not, as in the foot of man, obliquely. The

1 Loc. cit., Vol. II, p. 40.
2 Loc. cit., p. 186.
3 Loc. cit. 1, 231, and 2, p. 30.
4 Loc. cit. 2, p. 31.
5 Loc. cit., p. 140.
6 Loc. cit. 2, p. 304.
7 Loc. cit., p. 164.
8 Loc. cit., p. 341.
9 Loc. cit., p. 203.
10 Loc. cit., Vol. I, p. 538.

muscle undergoes considerable variation in man. Turner[1] found in two instances that the flexor accessorius had an accessory muscle attached to it which arose from the deep fascia of the back of the leg in its lower third and joined below the inner margin of the flexor accessorius. In some instances this takes the place of the deep flexor tendon in one or other of the digits, the latter tendon for that toe being absent. The number of digits to which it is distributed in man is subject to considerable variation. According to Testut the muscle may be entirely absent in man, but this one would think a rare occurrence.

The *Tibialis posticus* arose from the fibula and the tibia and the interosseous membrane in the upper third of the leg; it was a very definite but ill-developed muscle. The muscle became tendinous at the level of the junction of the middle and lower thirds of the tibia. It then passed over the posterior aspect of the lower extremity of the tibia, lying there in a well-marked groove near the inner margin of the bone and held in place by a strong band of fibrous tissue. It was completely separated from the other tendons at the inner ankle by this band and passed under it into the sole of the foot. The muscle was inserted into the under aspect of the scaphoid bone, a slip passing to the internal, the middle, and the external cuneiform bones, and to the sheath of the peroneus longus tendon. It thus resembles the condition found in man.

The *Plantar fascia* was poorly developed, in fact hardly to be recognized as a definite structure, excepting in the posterior part of the foot. Fick also remarks on the weakness of its development. There was a very dense pad of fat and connective tissue over the heel.

The *Abductor hallucis* arose from the inner and under part of the os calcis, and was inserted into the tibial side of the base of the proximal phalanx. This muscle is well developed in anthropoids and apparently in all apes. In connection with it Langer[2] describes in the Orang a tendon which passes on to be inserted into the terminal phalanx of the great toe. This he compares to the condition found in the hand (see page 44) and considers it the representative of the flexor longus hallucis of man; in the Gorilla he finds this tendon derived from the flexor digitorum fibularis. The muscle as described in our Orang resembles that found in man. On the right side Rudolf found underneath the abductor hallucis a small but very distinct muscle which

1 Loc. cit., p. 184.

2 Loc. cit., p. 192.

arose from the annular ligament and was inserted into the under surface of the internal cuneiform.

The *Flexor brevis hallucis.* The inner head arose from the portion of the tendon of the tibialis posticus which was inserted into the external cuneiform bone and from the sheath of the peroneus longus. It formed a well developed muscle 1.5 cm. wide, and was inserted into the base of the proximal phalanx of the great toe on its under and fibular side.

The outer head (Interosseus primus volaris of Henle) was definitely demonstrated as a structure composed wholly of fleshy fibres .5 cm. wide arising from the base of the fibular portion of the first metatarsal bone and inserted into the outer aspect of the base of the proximal phalanx of the great toe, immediately under the insertion of the adductor obliquus. The outer head of the flexor brevis in anthropoids is weak and tends to unite with the adductor hallucis more or less intimately—thus Bischoff found it in the Gorilla.

The *Opponens hallucis* was well developed. It arose in common with the flexor brevis hallucis, but proceeded separately to its insertion into the whole length of the tibial border of the first metatarsal bone. Rudolf observed on the right foot that the opponens could naturally be split up into three more or less separate and distinct fasciculi or bundles. The opponens hallucis is very variable in its development in apes. Bischoff states[1] that he only found it as a separate muscle in the Orang among anthropoids and in Macacus among lower apes. Huxley[2] discovered it in the Orang, and speaks of it as "a most remarkable muscle." At the time he writes (1864), he remarks that "this has not been described by other authors nor indeed is there any trustworthy evidence of the existence of such a muscle in any of the mammalia." Macalister, however,[3] subsequently found an opponens hallucis in the Gorilla although others have failed to find it in any of the anthropoid apes save the Orang. Brooks[4] records that whilst it is absent in all anthropoids (with the exception of the Orang) some of the fibres of the adductor transversus (and sometimes also of the adductor obliquus) in anthropoids are inserted into the metatarsal bone of the hallux and constitute a "second opponens" corresponding to the "adductor opponens" described by Bischoff and Langer in the hand of the Orang. (See page 46.)

1 Loc. cit. 2, p. 235.
2 Loc. cit., Vol. I. p. 596.
3 Loc. cit., p. 506.
4 Loc. cit., p. 90.

The opponens hallucis is not always present in the Orang, and oftentimes it is extremely weak. Testut states that an opponens is sometimes found in man. "On trouve quelquefois, au-dessous de lui (*i.e.*, brevis hallucis), quelques fibres profondes, insérées sur le metatarsien et constituant un veritable *opposant du gros orteil*, homologue de l'opposant du pouce; mais ce muscle est rarement bien différencié."[1]

The *Adductor obliquus hallucis* and the *Adductor transversus hallucis* had a continuous origin from the bases of the third, fourth and fifth metatarsal bones, from the fascia over the interossei muscles, from the sheath of the peroneus longus and from a fibrous arch extending from the base of the fifth metatarsal to the middle of the second metatarsal bone. These muscles are inserted into the whole of the fibular and the greater part of the plantar aspect of the base of the proximal phalanx. The transverse and oblique muscles could be readily separated from one another, and a third portion was defined which had an insertion into the lower border of the first metatarsal bone. This, no doubt, represented the "second opponens" described by Brooks as derived from the adductor obliquus.

Fick[2] holds that the main function of the adductor hallucis in the Orang is opposition and not adduction. Brooks[3] describes in the Orang a portion of the adductor obliquus (inseparable at its origin from the rest of that muscle), which ended in a rounded tendon and which passed between the two heads of the flexor brevis, and running along in a well marked sheath in the middle line of the digit, was inserted into the base of the ungual phalanx. It took the place of the absent long flexor tendon. This may be compared with the description of similar conditions found in the hand of anthropoids and already noted (p. 44). A somewhat similar tendon is described by Gratiolet and Alix[4] in the Chimpanzee and the Orang; the muscle arose along with the adductor transversus, and, passing over the proximal phalanx, was inserted into the base of the last phalanx. It was looked upon by these authors as representing the long flexor. Bischoff found in the Frankfort Orang on the left side a small tendon which in course and insertion corresponded to the flexor longus hallucis, but it arose from the fascia over the ball of the great toe.[5]

The tendency for intimate connection of the adductor hallucis with

1 Loc. cit., Vol. I, Pt. 2, p. 882.

2 Loc. cit. 1, p. 47.

3 Loc. cit., p. 87.

4 Loc. cit., p. 102.

5 Loc. cit. 1, p. 234.

the outer head of the flexor brevis has already been alluded to. Regarding the development of the transverse and the oblique adductor. Bischoff states that in the Gorilla, the Orang, Cynocephalus and Cercopithecia, both muscles are strongly developed and are separate from one another, whilst in the Chimpanzee, Gibbon, Pithecia and Hapale they are both present but united. In Macacus they are both present but weak.

The *Abductor minimi digiti* arose from the under aspect of the os calcis by two heads, one from the inner and one from the outer aspect of the bone, the inner head passing on the deep aspect of the flexor brevis digitorum. The muscle is also intimately united to the tendon of the peroneus brevis in the sole, from which it may be said to have an additional origin. This muscle terminated in a long tendinous structure which was inserted with the dorsal extensor expansion over the base of the proximal phalanx, and was attached also to the outer aspect of the proximal phalanx.

The *Abductor ossis metacarpi quinti* referred to on page 10, is closely associated with the abductor minimi digiti. It arose from the under aspect of the os calcis in common with the outer part of the flexor brevis digitorum and immediately overlying the inner head of the abductor minimi digiti. This structure is almost wholly tendinous in character. It was inserted into the outer and under aspect of the base of the fifth metatarsal bone.

The *Flexor brevis minimi digiti* arose from the base of the fifth metatarsal bone, and was inserted into the outer aspect of the base of the proximal phalanx. Rudolf on the right side found a slip of origin from the cuboid.

The *Opponens minimi digiti* arose from the sheath of the peroneus longus, and was inserted into the whole length of the fifth metatarsal bone along its outer aspect. The muscle was not found by Fick in the Orang. Bischoff[1] found it in the Gorilla.

The *Interossei* correspond in their detailed description to those of the hand. The third digit possessed two dorsal interossei lying in the interosseous spaces between the second and third and the third and fourth metatarsal bones. They arose from the dorsal surface and lateral margins of the two adjacent metatarsals; but, in addition, each is joined by a fleshy belly arising from the plantar and lateral aspects of the third metatarsal bone, the fleshy bellies of the two muscles meeting in the plantar aspect of the bone. Thus the third metatarsal bone is com-

1 Loc. cit. 2, p. 32.

pletely surrounded by the second and third dorsal interossei, with the exception of a narrow strip in the middle line on the dorsal aspect of the bone which is free from muscular fibres.

The fourth dorsal interosseous muscle arose in a similar fashion from the fourth and fifth metatarsal bones, but the third plantar interosseous takes the place of the plantar part of the fourth dorsal interosseous on the inner and plantar surfaces of the fifth metatarsal bone. The plantar portion of the second dorsal interosseous muscle is, in like manner, replaced by the first plantar interosseous on the second digit. The plantar portion of the third dorsal interosseous muscle is in like manner replaced by the second plantar interosseous muscle in relation to the fourth digit.

The first dorsal interosseous muscle is very powerfully developed. Its origin from the first metatarsal bone, however, is confined to the base of the bone. Some slips of origin from the internal cuneiform also join this head. The outer head of this muscle has an extensive origin from the second metatarsal bone, completely covering that bone, in fact, on its inner surface, and extending to the middle line on its plantar and dorsal surfaces, meeting on the plantar surface with the first plantar interosseous. Between the two heads of this muscle the dorsal vessels pass to the dorsum of the foot.

Fick[1] describes the intereossei in the Orang as like those found in man. In both man and apes one finds that one digit in both hand and foot possesses an insertion of two dorsal interossei, whilst the remaining digits possess only one dorsal interosseous muscle. In man it is the third digit in the hand, and the second digit in the foot; whilst, in my Orang, it was the third digit in both hand and foot. In this respect, the foot of my Orang corresponded to the hand of either ape or man, and differed from the foot of man. Abduction or adduction in the foot of my Orang was from or to the third digit. Bischoff, in his first paper, asserts[2] that in all apes the arrangement of the interossei of the foot corresponds to the hand of man and apes; but, subsequently, he found in the Gorilla an arrangement corresponding to the foot of man. Hepburn[4] found that abduction of the digits of the foot was from a line drawn through the second digit in the Gorilla and Chimpanzee, whilst in the Orang and Gibbon it was from a line through the third digit, as in my Orang.

1 Loc. cit. 1, p. 47.
2 Loc. cit. 1, p. 235.
3 Loc. cit. 2, p. 32.
4 Loc. cit., p. 347.

Gratiolet and Alix[1] differed from Hepburn regarding the Chimpanzee, as they found abduction was from a line drawn through the third digit. Thus, there is apparently some variation among the anthropoid apes, but the most common arrangement is abduction from a line through the third digit, and this, as far as my observation has extended, has always been found to be the case in the Orang, excepting in Fick's example mentioned above.

Attention has already been directed to the fact that the foot of the Orang resembles, in outward appearance, the human hand rather than the human foot. This observation led naturalists to apply the term "quadrumanous" to those apes possessing such characteristics. The external characters of the foot of the Orang certainly suggest a hand rather than a foot. Further, the foot of the Orang differs very materially in its external characters from that of man (compare the photographs of the hand and foot of man with those of the Orang). In considering the question as to whether the posterior extremity of the Orang possesses a hand or a foot, we must constantly have in mind the characteristic features of the human hand and the human foot with which to institute comparisons. It is not necessary to discuss at length the correspondences which are found in comparing the hand with the foot, but certain of the more obvious of these may be alluded to, and one is greatly aided in thus establishing homologies in man by reference to the lower animals. In the hand we have five digits as in the foot, and we find that the bones of the fingers and toes, *i.e.*, the metatarsals and metacarpals, with the phalanges, correspond in number, and have sufficient individual resemblances to make it an easy task to recognize those bones of the hand which correspond to similar ones in the foot. The carpal and tarsal bones are not so readily distinguished, but by referring both series of bones to a less specialized type of carpus and tarsus, one is able to establish very readily a series of probable homologies. The carpus or tarsus of the water tortoise has been suggested by Gegenbaur and Oscar Schmidt[2] for this purpose, and by referring the bones of the foot and hand to this simple form, we can determine the corresponding structures. In the following table, taken from Quain's Anatomy,[3] an attempt is made to establish these homologies. The "typical names" here employed refer to the bones in the carpus or tarsus of such a generalized form as the water tortoise:—

---

1 Loc. cit., p. 190.

2 Oscar Schmidt. "The Mammalia in their Relation to Primeval Times." London, 1895, p 36.

3 Vol. II, Part I, p. 144.

TABLE OF THE HOMOLOGOUS BONES OF THE CARPUS AND TARSUS.

Carpus.	*Typical Names.*		*Tarsus.*
Pyramidal	Ulnare	Fibulare	Os calcis
Pisiform	Ulnare sesamoideum(?)	Fibulare sesamoideum(?)	
Lunar	Intermedium	Intermedium	Astragulus
Scaphoid	Radiale	Tibiale	
	Radiale sesamoideum (?)	Tibiale sesamoideum (?)	Navicular
	Centrale	Centrale	
Trapezium	Carpale 1	Tarsale 1	Internal cuneiform
Trapezoid	Carpale 2	Tarsale 2	Middle cuneiform
Magnum	Carpale 3	Tarsale 3	External cuneiform
Unciform	Carpale 4	Tarsale 4	Cuboid
	Carpale 5	Tarsale 5	

Thus it would appear that in the skeleton we have corresponding elements to deal with when we compare the hand with the foot. Again in connection with the soft parts it is quite obvious that many muscles in the foot are represented by corresponding structures in the hand. There is, however, room for considerable difference of opinion regarding homologies here, and whilst we are unable to go into this subject at length in this paper, we may consider it briefly.

Broadly speaking, the flexor group of muscles in the leg may be regarded as homologues of the flexor group in the forearm, and the extensors of the leg as homologues of the extensors of the forearm. Huxley[1] suggested, with apparently good reason, that the popliteus of the leg arising from the external condyle of the femur corresponded to the pronator radii teres arising from the internal humeral condyle; the fact that the external femoral condyle is the homologue of the internal humeral condyle being readily established by tracing the difference in direction of the rotation of the limbs in development. We find that pronation and supination are movements not possible in the leg, although Bischoff[2] considers the peroneus longus and brevis to be pronators of the foot by raising its outer margin. He is therefore inclined to regard these muscles as performing similar functions to the pronators of the forearm in their action upon the hand; similarly he would regard the tibialis anticus as a supinator in the foot. These muscles, however (peronei and tibialis anticus), have as homologues in the forearm, according to Bischoff, the extensor carpi ulnaris and the two radial extensors, but these fail to raise the inner or outer margin of the hand as this movement is accomplished by pronation and supination of the hand as a whole. Bischoff would have us believe that whilst it is possible to establish

1 Loc. cit., Vol. I, p. 203.

2 Loc. cit. 1, p. 236-7.

analogues and homologues for other muscles, the movements of pronation and supination in the forearm must be regarded as being performed by muscles which have no homologues in the leg. The suggestion of Melzer (see p. 63 of this paper), deserves mention in this connection. He regards the humeral head of the pronator radii teres as being represented by the external head of the gastrocnemius, whilst the ulnar head, he claims, is represented by the popliteus. I, however, accept Huxley's view as the correct one and look upon the pronator radii teres of the forearm as the homologue of the popliteus in the leg. Melzer's view is not tenable; there is good reason to look upon the gastrocnemius muscle as representing the flexor carpi radialis and the flexor carpi ulnaris of the forearm.

Huxley[1] asserts that the foot of man is distinguished from his hand by the following absolute anatomical differences:

1. By the arrangement of the tarsal bones.
2. By having a short flexor and a short extensor muscle of the digits.
3. By possessing the muscle termed peroneus longus.

Bischoff[2] questions the correctness of Huxley's assertion. He considers that both peronei muscles together form a muscle which has become doubled in the foot and represents, as we have stated, the single extensor carpi ulnaris in the hand. In similar fashion he considers that the single muscle which we describe as the tibialis anticus in the foot is doubled in the hand, being there represented by the extensores carpi radialis longior et brevior. Huxley, however, has shown conclusively that the tibialis anticus corresponds to the extensor ossis metacarpi pollicis (abductor longus pollicis). There can be no doubt of this; the former is inserted into the first metatarsal bone and the internal cuneiform, whilst the latter is inserted into the first metacarpal bone and the trapezium.

The distinctive difference which Huxley claims for the foot in possessing the short extensor and the short flexor is denied by Bischoff, who concludes that if we contrast these muscles with the tendons which we describe under the terms "perforans" and "perforatus" in the hand, we shall find homologous structures, but we may go further, and we find it easy to produce evidence to lead us to the

1 Huxley, "Evidences as to Man's Place in Nature." New York, 1890, p. 107.

2 Loc. cit. 1, p. 236-7.

conclusion that the flexor sublimis digitorum of the hand has as its homologue in the foot the flexor brevis digitorum and the soleus, the latter muscle having been separated from the former by the growth backwards of the os calcis. Again in the case of the extensor brevis digitorum pedis we have in the hand as homologous structures the extensor minimi digiti and the extensor indicis. Huxley himself[1] in discussing these two muscles in the Orang, called attention to the fact that in many of the lower mammalia the normal arrangement is to have a superficial and a deep extensor supplied to every digit. This arrangement is approached when we find, as in my Orang, the extensor minimi digiti passing to the fourth and fifth digits, and the extensor indicis passing to the second and third digits. In the dissecting room of the University of Toronto, I found, in the human subject, an extensor indicis for the second digit, and an extensor minimi digiti for the fifth digit, whilst a very well developed muscular slip (1 cm. wide), arose from the ligaments over the back of the carpus, and proceeding over the dorsum of the middle finger beneath the tendon of the common extensor, it split at the head of the metacarpal bone and blended with the extensor expansion on the dorsum of the proximal phalanx. This was a true extensor brevis occurring in the hand of man.

The supinators (longus and brevis) do not appear to have any representatives in the lower limbs, nor do the two radial extensors. So, too, we have structures in the foot not represented in the hand, of which the flexor accessorius is an example. One has observed the fact that the foot of the ape frequently differs from the foot of man in that the accessorius is often absent in the former. It is usually absent in anthropoids (although present on the right side of my Orang): it is present however in the lower apes. Bischoff[2] points out that in man it corrects the direction of the action of the flexor digitorum longus communis, otherwise the direction of the pull of the long flexor would be at an angle. In the foot of the ape this is of no importance, on the contrary the action of the flexor tendons in adducting the other toes to the great toe is of great service in seizing or grasping. The toes of the apes in their flexor arrangements would thus resemble fingers much more than toes.

Although difficulties arise in the attempt to establish homologies, yet on the whole it would appear that a remarkable correspondence is obvious when we compare the musculature of the forearm with that of the leg. This is further evidenced in a most remarkable manner if we

1 Loc. cit., Vol. I, p. 596.

2 Loc. cit. 1, p. 257.

direct our attention to the muscles which Cunningham has called the "intrinsic muscles of the foot" when compared with a similar group of muscles in the hand. We find that homologies are best established here by referring the muscles of the hand or foot in man to a more generalized type and through the arrangement there found we may institute comparisons and establish homologies. Cunningham has done this for us in his work upon the marsupials.

One is aided greatly in appreciating the morphological significance of these muscles by reference to the conditions obtaining in the foot and hand of apes and mammals lower in the scale. Reviewing briefly Cunningham's observations on the subject we may first of all state that Cunningham[1] excludes from the intrinsic group those muscles which in man, or as homologous structures in other animals, take origin beyond the limits of the foot, and in the human foot he gives the following list of intrinsic muscles :

a. The four short muscles of the Great Toe.	1. Flexor brevis hallucis. 2. Abductor hallucis. 3. Adductor hallucis (adductor obliquus.) 4. Transversalis pedis (adductor transversus.)
b. The short muscles of the little toe.....	1. Flexor brevis minimi digiti. 2. Abductor minimi digiti. 3. The occasional opponens minimi digiti. 4. The occasional abductor ossis metatarsi minimi digiti.
c. The Interossei..	1. Four dorsal. 2. Three plantar.

In establishing homologies here, we must not place too much importance upon nerve supply as an aid to correct conclusions. Thus Cunningham joins issue with Ruge of Heidelberg, who regarded a muscle as the end organ of a nerve, and that, therefore, when a muscle altered its position and connections, its origin and typical relations can always be identified by its nerve supply. Cunningham admits that nerve supply is a most valuable aid to one's endeavours to discover the history of a muscle, but that it is an infallible guide is contrary to fact. In this connection Cunningham observes[2] that wherever two nerves approach one another and reach the confines of their distribution there is a tendency to variation in nerve supply. He quotes Brooks' results as to his investigation regarding the variation in nerve supply of the flexor brevis pollicis in man, thus—

---

1 Loc. cit., (Marsupial Report), p. 48.

2 Cunningham, "The Flexor Brevis Pollicis and the Flexor Brevis Hallucis in Man." Anatomischer Anzeiger VII, 1892, p. 206.

Outer head supplied by the deep branch of ulnar alone	5 cases.
" " " twigs from ulnar and median	19 "
" " " median, inner by the ulnar	5 "
Median nerve, giving twigs to both heads, inner head also receiving an ulnar supply	2 "

In a careful study of the muscles of the feet of certain of the marsupials, Cunningham demonstrates three layers, and concludes that this trilaminar arrangement is the typical one for the intrinsic muscles of the foot and the hand.

1. A layer of adductores.
2. An intermediate layer of flexores breves.
3. A dorsal layer of abductores.

Young[1] has also investigated the intrinsic muscles in the foot and hand of marsupials and agrees with Cunningham in his observations on the trilaminar arrangement; he extended his observations to other members of the group than those dissected by Cunningham.

Cunningham explains that deviation from this trilaminar arrangement may occur by subdivision, fusion or suppression of members of one or other of the layers. The suppression may be complete or partial and the muscle may be represented by ligaments.

In transferring our attention to the conditions obtaining in the ape we can readily determine the trilaminar arrangement and we observe that either the muscle group in the hand or that in the foot corresponds to this typical arrangement. Thus by reference to Plate 3 one can readily distinguish the three layers in the hand of my Orang.

1. Fig. 5 shows the muscles of the palmar layer composed of the adductor muscles of the thumb.

2. Fig. 6 demonstrates certain of the flexores breves of the intermediate layer.

3. Fig. 7 shows the dorsal layer of the abductores.

As I have already stated, so far as the so-called "interossei" are concerned, the condition found in the foot of my Orang corresponded to that found in the hand in every particular, and in plate V is illustrated the arrangement of these muscles in either foot or hand.

---

1 A. H. Young, "The Intrinsic Muscles of the Marsupial Hand." Journ. of Anat. and Phys. Vol. XIV, 1879, p. 149.

The dorsal layer of muscles is represented by a full series; the four dorsal interossei and with them the abductor pollicis and the abductor minimi digiti. It is interesting here to note the suggestion that the abductor of the thumb and the little finger each arise from marginal structures which have been looked upon as possibly præpollex and postminimus rudiments, viz., the ridge (or margin) of the trapezium and the pisiform bone. From this standpoint they have been regarded as interossei muscles which have persisted after the suppression of the osseous elements of the additional digits. I have already noted the relation of the extensor ossis metacarpi pollicis to the præpollex, and in this connection one may note an interesting variation of that muscle which I found in the dissecting room of the University of Toronto. The extensor ossis metacarpi pollicis split into two distinct tendons at a point 5 cm. above the wrist joint; one tendon was inserted into the base of the metacarpal bone in its palmar aspect, and the other passed on to join the abductor pollicis and could be traced as a distinct tendon extending 2 cm. along the deep aspect of that muscle, where it blended with its muscular fibres.

We have thus in the hand the following muscles in the *dorsal layer.*

1. Abductor pollicis.
2. Abductor minimi digiti.
3. The Dorsal interossei.

In the foot Cunningham adds a fourth muscle occasionally present, a rudiment of which I have described in my Orang, viz.:

4. The occasional Abductor ossis metatarsi minimi digiti.

The second layer of muscles, the intermediate layer, is made up of those muscles which Cunningham has termed the Flexores breves in the marsupials. These in man, as in the Orang, include the plantar interossei and the short flexors of the thumb and of the little finger. Cunningham[1] at first was inclined to place the plantar interossei in the plantar group of adductors, but he subsequently placed them in the intermediate layer for the following reasons:

1. In quadrumana he has traced the gradual disappearance of the adductor muscles except those belonging to the great toe.

2. We find plantar interossei not only in those apes which have

1 D. J. Cunningham, "The Intrinsic Muscles of Thylacine, Cuscus and Phascogale." Journ. Anat. and Phys., Vol. XII, 1878, p. 434.

complete adducting apparatus (*e.g.*, Cynocephalus) but also in those in which it is only represented by the adductors of the hallux and by fibrous bands (*e.g.* Orang) and in those in which it is reduced to the adductors of the great toe only (*e.g.* Gorilla).

3. Ruge has pointed out that the deep division of the external plantar nerve, as it runs inwards across the sole is placed between the adductor muscles and the other muscles of the intrinsic group. This is a most useful, and, as a general rule, a most reliable guide in determining the muscles which belong to the plantar layer. Ruge[1] points out that in mammals the deep division of the external plantar passes inwards between the interossei and the contrahentes (adductors). In man this nerve passes between the plantar interossei beneath and the adductor obliquus hallucis above, and this Cunningham looks upon as most suggestive.

4. In a foot dissected by Cunningham he found a distinct fleshy slip proceeding from the outer edge of the adductor obliquus hallucis to be inserted into the outer side of the base of the first phalanx of the index. This clearly represented the adductor indicis.

Cunningham would therefore place in the intermediate layer the following muscles:

1. Flexor brevis pollicis, deep and superficial heads.
2. Flexor brevis minimi digiti.
3. Plantar interossei.

In studying the interossei group (palmar and dorsal), as found in my Orang, and figured in Plate V, it appears to be a question worth considering as to the relation of the palmar portion of the dorsal interossei to the intermediate layer. On reference to the dissection (as figured in plate V), one cannot but be struck by the symmetrical arrangement of the palmar interossei and the palmar portion of the dorsal interossei as forming one group of flexores breves, and the origin of the palmar interossei may yet be accounted for by subdivision of originally single muscles, or we may suppose that fusion has occurred to produce the connection of the palmar portion with the remaining part of the dorsal interossei. In other words one would venture to suggest that the intermediate layer is represented in the Orang by the palmar interossei

1 G. Ruge, "Zur vergleichenden Anatomie der tiefen Muskeln in der Fusssole," Morphologisches Jahrbuch, Vol. IV, 1878, p. 644.

plus the palmar portion of the dorsal interossei, and the short flexors of the thumb and little finger.

The flexor brevis of the first digit is represented by two heads, of which the deep head might otherwise be described as one of the palmar or plantar interossei, the interosseus primus volaris of Henle. This muscle resembling in its attachments and relations the other muscles of the plantar interosseous group, belongs to the intermediate layer.

The common origin of all these muscles of the interosseous group is indicated by Huxley[1] who states that amongst the Platyrrhini the interossei are no longer visible from the dorsum of the foot, but, as in the lower mammals, are altogether flexores breves inserted by sesamoid bones into the bases of the first phalanges. This resembles the condition described by Ruge in the human foetus (vide infra).

We have still left for consideration a series of muscles representing the adductor group. In the Orang, as in man, these are reduced to the adductors for the first digit. Thus we have in the hand the adductor obliquus pollicis and the adductor transversus pollicis. These represent a more extensive series found in marsupials in the plantar layer as adductors of the second, fourth and fifth digits. In the Chimpanzee and Gibbon there are two adductors, viz., for the first and fifth digits, whilst in the Orang and Gorilla the adductor for the first digit alone remains.

Thus in man and in the orang we have, in the palmar layer, the adductors of the thumb (obliquus and transversus),

Adductor obliquus pollicis.

Adductor transversus pollicis.

The only short muscles of the first and fifth digits, which we have not accounted for, are of the opponens group. In my Orang we found an opponens for the first and fifth digits in both hand and foot. These Cunningham considers as developed most commonly from the flexores breves group.

Our complete classification would therefore be:

Dorsal layer.

1. Abductor pollicis.
2. Abductor minimi digiti.

---

1 Loc. cit., Vol. II, p. 94.

3. Dorsal interossei.

and in the foot occasionally

4. Abductor ossis metatarsi minimi digiti.

Intermediate layer.

1. Flexor brevis pollicis { deep head. / superficial head.

2. Flexor brevis minimi digiti.

3. Plantar interossei.

4. Opponens.

Palmar layer.

Adductor Pollicis { obliquus. / transversus.

We can now readily establish homologies for the hand and foot, and we may construct a table thus:

Flexor brevis pollicis	Flexor brevis hallucis
(*a*) Radial head	(*a*) Tibial head
(*b*) Ulnar head	(*b*) Fibular head
Flexor brevis minimi digiti	Flexor brevis minimi digiti
Abductor pollicis	Abductor hallucis
Abductor minimi digiti	Abductor minimi digiti
Opponens pollicis	*Opponens hallucis*
Opponens minimi digiti	Opponens minimi digiti
Adductor obliquus pollicis	Adductor obliquus hallucis
Adductor transversus pollicis	Adductor transversus hallucis
Interossei (Palmar and Dorsal)	Interossei (Plantar and Dorsal).

Homologies are thus established for the limb muscles, as has been done also for the skeletal parts; one may add that an attempt is also made to establish homologies for the nerves (*vide* Quain, Vol. III., Pt. 3, p. 384). I shall not, however, attempt to discuss the homologies of the nerves in this paper. Whilst we can thus establish homologies between the structural elements of the hand and foot, we yet observe certain anatomical differences due, I consider, to modification from a common type of origin. The foot of man is modified as an organ for support, whilst the hand of man, in the erect attitude of the individual, is left free to minister to his varied needs. There can be little doubt concerning the correctness of the view that these two extremities are derived from a common type and that the differences observable between the hand and the foot are due to modification resulting in departure from the

original typical form, these modifications being due to a specialization of function—one holds this view despite the fact that Bischoff comes to the conclusion that both anatomically and physiologically the so-called posterior hand of the ape possesses more agreement with the human hand than with the human foot.

No doubt certain conditions in the ape's foot resemble the conditions present in the hand, and differ from those of the human foot. The adductor transversus hallucis in the ape's foot tends to blend with the adductor obliquus and is much more strongly developed than in the human foot. In this particular the muscle in the ape's foot approaches that found in the hand of man and differs from the human foot. In my Orang I found an opponens hallucis ; this muscle is not always found in anthropoids, but appears to be peculiar to the Orang, and among lower apes it is found in Macacus. This is a characteristic muscle of the hand and is not found in the human foot. Among apes there is a frequent approach to the hand (as in my Orang), in the arrangement of the interossei, whereby abduction is secured from the third digit and not from the second. Huxley[1] admits that the foot of the Orang deviates very greatly from that of man. The great length of the phalangeal portion of the foot is very noticeable, and the narrow os calcis with an absence of the two tubercles which are present in man. There is great mobility between the carpal bones; the phalanges are greatly curved. The hallux is remarkably short,and is capable of extreme abduction from the other digits, whilst opposition is also possible to a complete degree. In connection with the movableness of the great toe in apes one is struck by the peculiarity of the shape of the articulation between the first metatarsal bone and the internal cuneiform. The articular surfaces are saddle-shaped, and thus provide for greater freedom of movement. This differs from the foot of man where the surfaces are flat and is in agreement with the hand of man where the characteristic saddle-shaped joint is found between the trapezium and the first metacarpal. This condition in the ape was described by Huxley in the Chimpanzee's foot, and it was also noted by Huxley that, in the hand, the trapezium in that animal presented a simple, oval, convex facet, and was no longer saddle-shaped.[2] In the lower apes, however, Huxley found the characteristic saddle shape of the trapezium.[3] Fick describes this joint of the first digit as being saddle-shaped in both foot and hand in the Orang;[4] Bis-

1 Loc. cit., Vol. I, p. 564.

2 Loc. cit., Vol, I, p. 428.

3 Loc. cit., Vol. I, p. 671.

4 Loc. cit. 1, p. 50.

choff in the Gibbon, however, describes a hollowed out socket in the trapezium for the head of the metacarpal bone, but says the joint was not a true saddle-shaped articulation.

The flexor accessorius is a characteristic feature in the human foot. We have already noted the fact that it is very frequently absent, and always ill-developed in the anthropoid apes. When we consider that its development is almost universal among the lower apes, it is not to be looked upon as an essential difference between man and apes; when absent, however, the inferior extremity of the anthropoid ape rather resembles the hand of man than his foot.

The strong well developed flexor longus hallucis is a characteristic feature of the human foot not found in apes. The Gorilla is an exception to this statement, as Bischoff and Duvernoy found a well developed strong tendon for the great toe in that animal. In the Orang the flexor longus hallucis gives no tendon to the great toe, whilst in other apes its distribution is mainly to the third and fourth toes, with usually a very weak slip for the hallux.

Whilst the ape's foot thus differs from the foot of man, it is also quite obvious that the hand also differs in a marked degree from the human hand. Compare (see photograph) the long thin hand of the ape with that of man, and note particularly the rudimentary thumb. The thumb is extremely rudimentary and ill-developed. It becomes still more so in the new world monkeys, according to Huxley[1]; in Ateles it is apparently functionless, although all its muscles (abductor, adductor, flexor brevis and opponens) are present, except the long flexor. In the Arctopithecini (marmosets) Huxley[2] says it can no longer be called a thumb; the digit lies on the same plane as the other digits and is not in the least degree opposable—this might be called a paw rather than a hand—whilst such is the case, the hallux, which is very small, is still slightly opposable in this animal.

The absence of a flexor longus pollicis, so strongly developed in man, is obviously a very marked and essential difference observable in comparing the hand of the ape. Again we have noted the absence of the characteristic saddle-shaped articular surface in the joint between the first metacarpal and the trapezium.

A fact of some interest regarding the comparisons which may be

1 Huxley, "Manual of Anatomy of Vertebrated Animals," New York, 1872, p. 396.

2 Loc. cit., Vol. II, p. 124.

established between the ape and man is one to which we have already called attention, namely, that in the human fœtus we find correspondences more marked than they are when the adult man is compared with the ape. Cunningham mentions Ruge's work in the following reference.[1] "Ruge in his memoir upon the development of the muscles of the human foot shows that the interossei muscles in the foot of the early embryo are plantar in position, and that the upward growth of the dorsal interossei and the formation of the interosseous spaces takes place as a subsequent and gradual step. In three of the diagrams which illustrate the text he gives representations by sections through the metatarsus at three different periods of development. In the first the metatarsal bones, with the exception of the first two, are in close apposition, and in consequence, all the interosseous muscles, excepting the first dorsal, are plantar in position. The second diagram is from a foot somewhat more advanced. It shows that as development progresses the metatarsal bones separate from each other, and that simultaneously with this the dorsal interossei begin to shoot up between them like wedges. The third illustration gives a view of the relative position of the muscles and metatarsal bones, as they are to be seen in the adult. The bones are widely apart from each other, and the muscles have reached the dorsum of the foot."

The transverse section (Plate IV, fig. 4), illustrates the fact that the interossei muscles are more plantar (palmar) than dorsal in my Orang; this condition is exaggerated in the lower apes where, as I have already stated, Huxley found among the Platyrrhini the interossei of the foot were no longer visible from the dorsum but existed as flexores breves towards the plantar surface. In the dog the metatarsals are closely compressed, and the interossei wholly plantar.

In the human fœtus the great toe is separated from the other toes and the position of the foot is that of "varus," resembling somewhat that found persistent in the ape. We find that this fact is alluded to by Flower,[2] who, in referring to the principal difference between the foot of the ape and the foot of man, emphasizes the fact that in the ape the foot is converted into a more or less modified grasping organ. He directs attention to the effect produced upon the ape's foot in consequence of the fact that the articular surface of the internal cuneiform for the hallux is saddle-shaped, and is directed obliquely towards the inner or tibial side

1 Quotation rom Cunningham's Challenger Report, p. 138-9.

2 Loc. cit., p. 341.

of the foot. The consequence is that the hallux is not only separated from the other digits, but it is also set in a different plane, so that when it is flexed it turns towards the sole of the foot and becomes opposed to the others much as the thumb does in the hand. Flower (and others, *e.g.*, Fick) remarks that the terminal phalanx of the hallux is often wanting. Fick attributes this to ill-usage. Flower points out that the proportions of the three segments of the foot in the anthropoid ape are the exact reverse of those in man. In the ape the tarsal segment is the shortest and the phalangeal the longest; the reverse is true of man.

The result of our study is to bring us to the conclusion that whether we study the extremities of man or of the Orang we find corresponding structures in the upper extremity as compared with the lower. A common type of origin is clearly indicated. This is the more readily observed in the ape than in man where the highest degree of specialization of function has been reached. As a result of this we find greater differences exist between the human hand and the human foot, than between the hand and the foot of the ape. Moreover, in man there is a greater departure from the common type of origin in both hand and foot. Bischoff has investigated the subject of homologies, and although his conclusions differ in some details from the views expressed in this paper, he agrees in the main and establishes homologies for the hand and foot of man as in the hand and foot of apes. He further admits that certain correspondences exist between the foot of the ape and the foot of man. Following Bischoff's argument to a logical conclusion (as Fick observed[1]) we would be forced to conclude that man, like the ape, had four arms and four hands. Bischoff, however, views the matter not wholly from the morphological side, but from the physiological, and, looking upon the ape's foot as a grasping organ, he considers this strong evidence for the assertion that it is a hand. He admits that this alone is not sufficient evidence ; on similar ground he says one might call the trunk of an elephant a hand, but there are obviously other similarities in the ape's foot to a hand, chiefly the short, movable, opposable hallux, differing from the first digit of the human foot, possessing the saddle joint with the internal cuneiform and thus resembling the human thumb. Whilst one cannot longer uphold in its entirety Huxley's assertion regarding the absolute anatomical differences in distinguishing the foot of man from his hand (see page 75), yet in the skeletal parts his argument regarding the arrangement of the tarsal bones is unanswerable and we are forced to conclude with him that the so-called hind hand of the ape is essentially a foot. The method of articulation of the foot with

1 Loc. cit. 1, p. 53.

the leg at the ankle joint is characteristic of the foot and not of the hand. There is also an absence of pronation and supination in the ape's foot. Langer[1] admits the resemblance of the ape's foot to a hand, but also points out the obvious fact that the anterior extremity of the Orang is as far removed from the human hand as the posterior extremity is from the human foot. Both extremities are wholly organized for holding and grasping in the ape, and Langer would have us look upon the posterior extremity as a holding or grasping foot. Huxley, it is true, argues the matter wholly from the morphological standpoint, and Fick[2] agrees with Huxley that the feet of man and apes are essentially alike in all variety of anatomical detail. But certain differences (non-essential) undoubtedly exist. The absence of a true arch and the fact that the Orang walks upon the outer margin of the foot with the digits flexed like a closed fist. In man the toes are, comparatively, very short, and as Turner points out, the great toe is fastened to the second digit by a strong ligament. The fixation of the great toe, however, may be greatly decreased in man as is evidenced in those individuals who have congenital absence of the arm; they are capable of doing many things with the toes, impossible on the part of an ordinary individual. By training, an armless painter, according to Fick, was able to copy Rubens' pictures, and one knows of the possibility of individuals writing, playing the violin, and doing a variety of things. Thus, when necessary, man is capable of using his foot for a number of purposes and to accomplish work ordinarily relegated to the hands. In the struggle for existence, similarly, the ape has developed great dexterity in the use of his foot, but it still remains a foot. Fick tells us that in the living ape there is an obvious difference in the manner in which he uses the upper and lower extremities. In walking, running and springing forwards from the hind legs the arms are scarcely burdened, but the hands are always ready to grasp an object such as fruit, and to do all finer work, such as the breaking open of fruit, seeking vermin, etc., the legs and feet being used for support and in running.

It was Tyson,[3] two centuries ago, who, struck by the great external resemblance of its hinder limb with its opposable thumb to a hand, remarked that the animals might be called "quadru-manus." Referring to the foot of the Chimpanzee which he dissected, he remarks as follows: —"But this part, in the formation and its function too, being liker a hand, than a foot, for the distinguishing this sort of animals from others,

1 Loc. cit., p. 193.
2 Loc. cit. 1, p. 53.
3 Loc. cit., p. 13.

I have thought, whether it might not be reckoned and called rather quadru-manus than quadrupes, *i.e.*, a four-handed, than a four-footed animal." Huxley remarks that if we are to settle the question on the grasping power of the organ we must consider the terminal division of the hind limb of a bird or an oppossum to be equally a hand with that of the monkey. Huxley, however, holds that morphological analogies cannot be decided by physiological function, but only by exact comparison of the essential anatomical characters. An attempt has been made in this paper to show, with due regard to both structure and function, that the ape must be considered as possessing two feet and two hands; that the posterior extremities of the creature terminate in structures resembling both anatomically and physiologically the human foot rather than the human hand.

The comparative study of the muscles of the Orang is full of interest, and the interest increases when we institute comparisons with the arrangement of the musculature in the human body. Fick[1] holds that in the Orang we have more muscle variation (when we consider the literature), than we have in man, and it is interesting to note that in the sense of the modern view, we have in the present day Orang, evidence of a more active phylogenetic variation than in man.

By studying muscle variation in man relating to normal conditions in lower animals, we may throw light on the position of man in the animal kingdom. This conviction was long ago expressed by Professor Wood,[2] who remarked, concerning the comparative study of the musculature of man and the lower animals, that:—" If in addition to the general resemblance of the muscular mechanism, there are to be found in the former [*i.e.*, in man] fragmentary records of special apparatus which have, in the latter [*i.e.*, in lower animals] the fuller development of a definite purpose, then these may be taken as at least of equal importance with other evidence of traces, some may think, of a general unity of plan with varied teleological intentions, and others, of an ancient morphological relationship of a much closer character. But if, on the other hand, muscles are found which have no place in the various animal types, we may fairly take them as indications, valuable as far as they go, of progress still advancing towards a higher development of the human frame, —of an increase in the distance, already great, which separates physically man from animals."

---

1 Loc. cit. 2, p. 306.

2 Loc. cit., p. 44.

EXPLANATION OF PLATES.

The following plates are drawings from dissections made by the author :—

PLATE III.

FIG. 1.—Dissection of the posterior aspect of the neck and shoulder of the Orang Outang.

acrom., acromion process; *clav.*, clavicle; *e.a.m.*, external auditory meatus; *i.spin.*, infra spinatus; *l.a.s.*, levator anguli scapulae; *m.o.*, omo cervicalis; *rhom.*, rhomboid; *s. spin.*, supra spinatus; *s. mag.*, serratus magnus; *trap.*, trapezius; *t. min.*, teres minor.

PLATE IV.

FIG. 2.—Dissection of the anterior aspect of the chest wall and shoulder of the Orang Outang.

acrom., acromion process; *clav.*, clavicle; *cor.*, coracoid process; *Delt.*, deltoid; *H.*, humerus; *p. min.*, pectoralis minor; *p. m.* 1, the pars costo-abdominalis of the pectoralis major; *p.m.* 2, the pars sterno-costalis of the pectoralis major; *p.m.* 3, the pars sternalis of the pectoralis major. *S. m.*, sterno mastoid.

FIG. 3.—Representation of the mode of insertion of the pectoralis minor muscle.

acrom., acromion process; *clav.*, clavicle; *cor.*, coracoid process; *lig.* 1 and *lig.* 2, continuation of the fibres of insertion of the pectoralis minor muscle into the clavicle and the acromion process; *p. min.*, the tendon of insertion of the pectoralis minor muscle passing to the coracoid process.

FIG. 4.—The arrangement of the interossei muscles in the Orang Outang, as they appear in their relation to the metacarpal bones, on transverse section through the metacarpus.

d. i., dorsal interossei; *v. i.*, palmar interossei.

PLATE V.

FIG. 5.—Dissection of the short muscles of the thumb and the little finger in the Orang Outang.

ab.m.d., abductor minimi digiti; *ab.P.*, abductor pollicis; *ad.o.p.*, adductor obliquus pollicis; *a.t.p.*, adductor transversus pollicis; *F.*, palmar fascia; *f.b.p.* 1, *f.b.p.* 2, outer and inner heads of the flexor brevis pollicis; *fl.b.m.d.*, flexor brevis minimi digiti; *op.m.d.*, opponens minimi digiti; *o.p.*, opponens pollicis.

FIG. 6.—Dissection of the interossei muscles of the hand in the Orang Outang, viewed from the palmar aspect.

v.i. 1, *v.i.* 2, *v.i.* 3, palmar interossei, *d.i.* 1, *d.i.* 2, *d.i.* 3, *d.i.* 4, dorsal interossei.

LIBRARY OF THE UNIVERSITY

FIG. 7.—Dissection of the interossei muscles of the hand in the Orang Outang, viewed from the dorsal aspect.

v.i. 1, *v.i.* 2, *v.i.* 3, palmar interossei, *d.i.* 1, *d.i.* 2, *d.i.* 3, *d.i.* 4, dorsal interossei.

PLATE VI.

FIG 8.—Dissection of the gluteal region, and the back and outer side of thigh in the Orang Outang.

g.max., gluteus maximus; *g.med.*, gluteus medius; *g.min.*, gluteus minimus; *g.s.n.*, great sciatic nerve; *g.troch.*, great trochanter of the femur; *h.m.*, hamstring muscles; *ib.*, iliac bone; *il.*, iliacus; *is.*, ischial spine; *ob.e.*, obturator externus; *ob.i.*, obturator internus; *py.r.*, pyriformis; *q.f.*, quadratus femoris; *rect.*, rectus femoris; *scan.*, scansorius; *v.i.* vastus externus.

LIBRARY OF THE UNIVERSITY OF CALIFORNIA

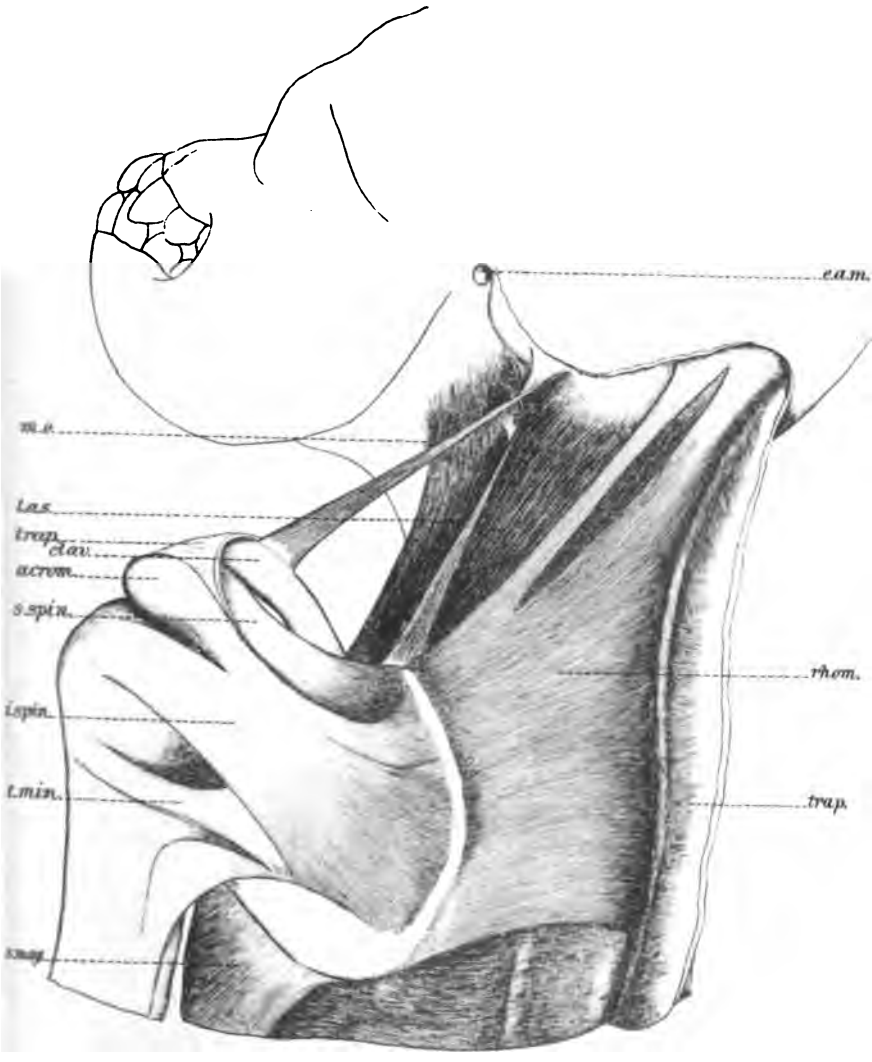

Fig. I.

Brodey, del. Sidney Prosser & Baker

UNIVERSITY OF
CALIFORNIA

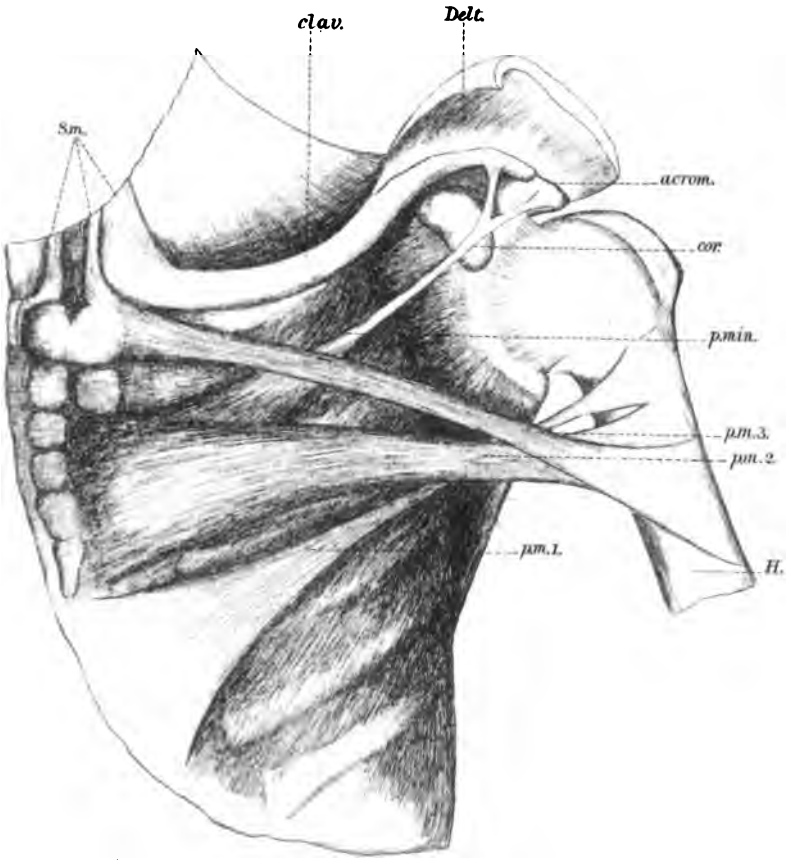

Fig.2

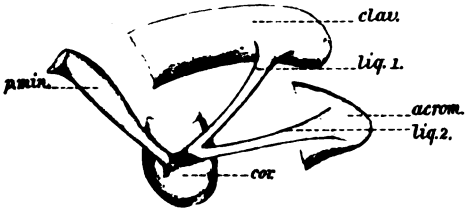

Fig.3.

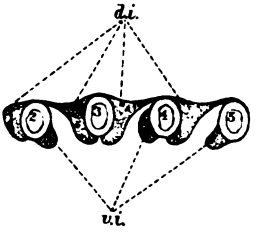

Fig.4.

LIBRARY
OF THE
UNIVERSITY
OF CALIFORNIA

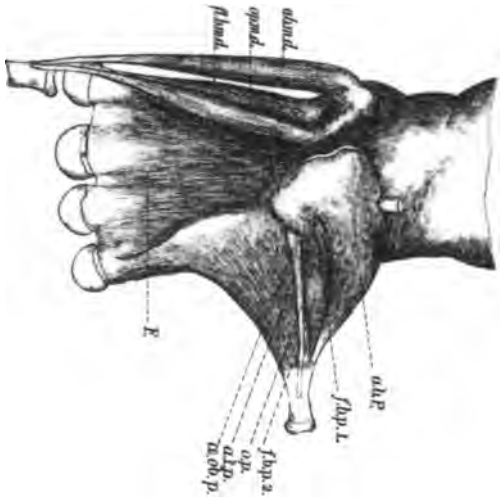

Fig. 5.

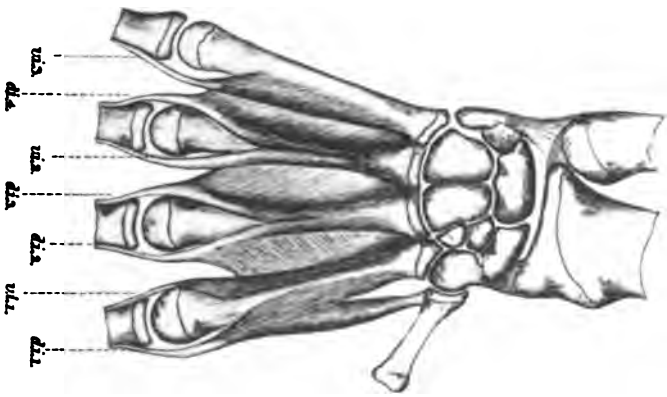

Fig. 6.

Fig. 7.

Bernatz, del.

Ellis & Vollum Lith. Lond.

LIBRARY
OF THE
UNIVERSITY
OF CALIFORNIA

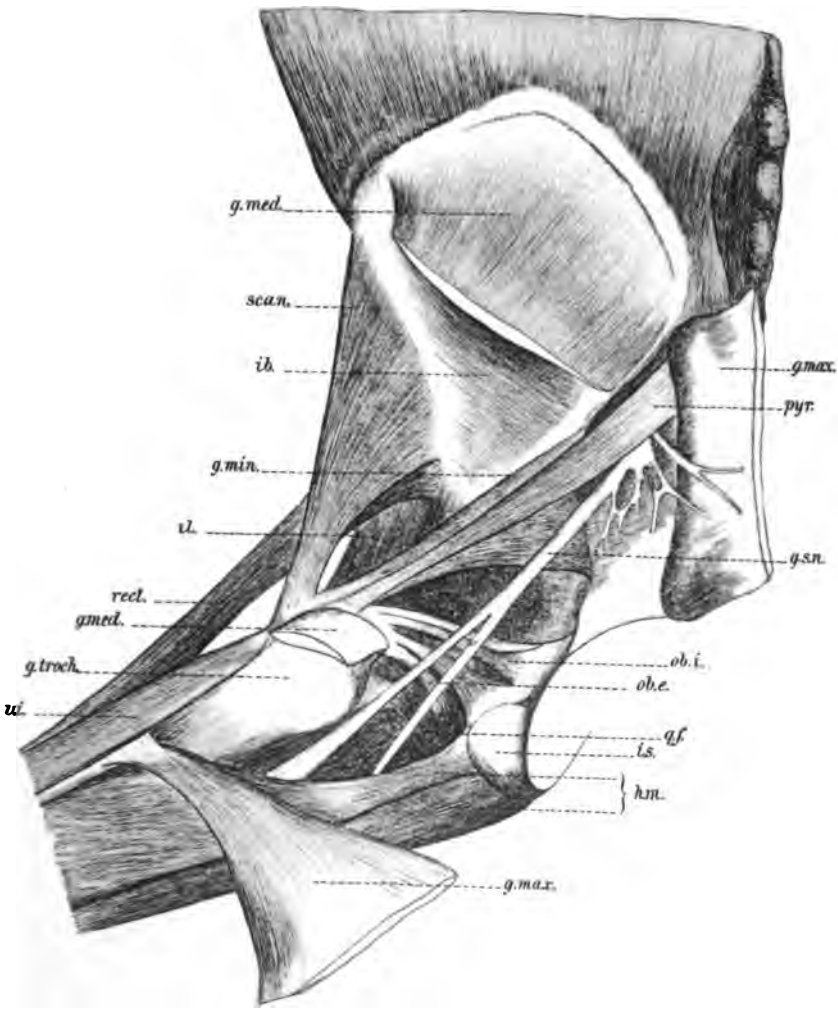

Fig. 8.

Brunley, del.

Edward Mosley & Son, Litho.

LITERATURE.

Bardeleben, K. "Über die Hand und Fuss-Muskeln der Säugetiere, besonders die des Præpollex (Præhallux) und Postminimus." Anatomischer Anzeiger, 1890, p. 435.

Baur, G. "Der Carpus der Schildkröten." Anatomischer Anzeiger, 1892, p. 206.

Bischoff, Th. L. W. (1). "Beiträge zur Anatomie des Hylobates leucisus und zu einer vergleichenden Anatomie der Muskeln der Affen und des Menschen." Abhandl. der math.-phys. Classe der könig. bayer. Akad. der Wissenschaften, Vol. X, pt. 3, 1870, p. 198.

Bischoff, Th. L. W. (2). "Beiträge zur Anatomie des Gorilla." Abhand. der math.-physik.] Classe der könig. bayer. Akad. der Wissenschaften, Vol. XIII, pt. 3, München, 1880, p. 1.

Blake, Edward, M.D. "On the study of the hand for indications of local and general disease." London, 1899.

Born, G. "Die sechste Zehe der Anuren." Morphologisches Jahrbuch, Vol. I, 1876, p. 435.

Brooks, H. St. John. "On the short muscles of the pollex and the hallux of the anthropoid apes, with special reference to the opponens hallucis." Journ. of Anat. and Phys., Vol. XXII, 1887-8, p. 78.

Bryce, T. H. "Note on a group of varieties of the pectoral sheet of Muscle." Journ. of Anat. and Phys., Vol. XXXIV, 1899, p. 75.

Champneys, F. "On the muscles of the Chimpanzee (Troglodytes niger), and a Cynocephalus anubis." Journ. of Anat. and Phys., Vol. VI, 1872, p. 176.

Chapman, H. C. "On the Structure of the Orang-Outang." Proceedings of the Academy of Natural Science of Philadelphia, 1880, p. 160.

Cunningham, D. J. "The intrinsic muscles of hand of the Thylacine, Cuscus and Phascogale." Journ. of Anat. and Phys., Vol. XII, 1878, p. 434.

Cunningham, D. J. "Report on the Marsupialia with an account of the comparative anatomy of the intrinsic muscles and nerves of the mammalian pes." Report of the Voyage of H.M.S. "Challenger," Vol. V, 1882, Part XVI, p. 1.

Cunningham, D. J. "The topographical anatomy of the Chimpanzee, Orang-Outang and Gibbon." Cunningham Memoirs. Royal Irish Academy, 1886, p. 117.

Cunningham, D. J. "The flexor brevis pollicis and the flexor brevis hallucis in man." Anatomischer Anzeiger, 1892, p. 206.

Cuvier, Georges. "Anatomie comparée: recueil de planches demyologie." Paris, 1849.

Darwin, Charles. "The expression of the emotions in man and animals." London, 1872.

Darwin, Charles. "The Descent of Man." London, 1871.

Delisle. "Sur l'ostéologie des orang-outans." Comptes rendus de l'Académie des Sciences, Paris, 1894, Vol. CXIX, p. 241.

Deniker, J. "Recherches anatomiques et embryologiques sur les singes anthropoïdes jeunes et adultes." Archives de Zoo. exper., sr. 2, Vol. III, 1885, p. 1.

Deniker and Boulart. "Les Sacs Laryngiens des Singes anthropoides." Journal de l'Anatomie et de la Physiologie, Paris, 1886, p. 51.

Deniker and Boulart. "Sur divers points de l'anatomie de l'Orang-Outang. Comptes rendus de l'Academie des Sciences, Vol. CXIX, 1894, p. 235.

Dobson, G. E. "On the homologies of the long flexor muscles of the feet of mammalia, with remarks on the value of their leading modifications in classification." Journ. of Anat. and Phys., Vol. XVII, 1883, p. 142.

Duvernoy, M. "Des caractères anatomiques des grands singes pseudo-anthropomorphes." Archives du Museum d'Histoire Naturelle, Paris, 1855-56, p. 1.

Emery, C. "Zur morphologie des Hand und Fussskeletts." Anatomischer Anzeiger, 1890, p. 283.

Fick, Rudolph (1). "Vergleichend anatomische Studien an einem erwachsenen Orang-Utang." Archiv für Anat. und Phys., Anat. Abth., 1895, p. 1.

Fick, Rudolph (2). "Beobachtungen an einem zweiten erwachsenen Orang-Utang und einem Schimpansen." Archiv für Anat. und Phys., Anat. Abt., 1895, p. 289.

Fleming, W. "Über den Flexor Brevis Pollicis und Hallucis des Menschen." Anatomischer Anzeiger, 1887, pp. 68 and 269.

Flower, W. H. "An Introduction to the osteology of the Mammalia." London, 1885.

Gegenbaur, C. "Ein Fall von mehrfachen Muskelanomalien an der oberen Extremität." Archiv für Path. Anat. und Phys., Vol. XXI, 1861, p. 376.

Gegenbaur, C. "Ueber den Musculus Omohyoïdeus und seine Schlussbeinverbindung." Morphologisches Jahrbuch, Vol. I, 1876, p. 243.

Gegenbaur, C. "Lehrbuch der Anatomie des Menschen." Leipzig, 1892.

Goodsir's Anatomical Memoirs. Edited by Prof. Wm. Turner. Edinburgh, 1868. Vol. I.

Grapow, Max. "Die Anatomie und physiologische Bedeutung der Palmaraponeurose." Archiv für Anatomie und Entwickelungsgeschichte, 1887, p. 143.

Gratiolet and Alix. "Recherches sur l'Anatomie du Troglodytes Aubryi." Nouvelles archives du Museum d'Histoire Naturelle de Paris, Vol. II, 1866, p. 1.

Hartman, Robert. "The Anthropoid Apes." New York, 1886.

Hepburn, David. "The comparative anatomy of the muscles and nerves of the superior and inferior extremities of the anthropoid apes." Journ. of Anat. and Phys., Vol. XXI, 1892, pp. 149 and 324.

Hepburn, David. "The Integumentary grooves on the palm of the hand and the sole of the foot of man and the anthropoid apes." Journ. of Anat. and Phys., Vol. XXVII, 1892-93, p. 112.

Humphrey. "On the disposition and homologies of the extensor and flexor muscles of the leg and forearm." Journ. of Anat. and Phys., Vol. III, 1869, p. 320.

Huxley. "The structure and classification of the mammalia." The Medical Times and Gazette, Vol. I. and Vol. II, 1864.

Huxley. "Manual of Anatomy of Vertebrated Animals." New York, 1872.

Huxley. "Evidences as to Man's place in Nature." New York, 1890.

Langer, C. "Die Musculatur der Extremitäten des Orang als Grundlage einer vergleichend-myologischen Untersuchung." Sitz. der math-natur. Classe der kais. Acad. der Wissenschaften, Wien, Vol. LXXIX, pt. 3, 1879, p. 177.

Lubosch, W. "Ein M. Coraco-antibrachialis beim Menschen; Beiträge zur Morphologie des M. Biceps Brachii." Morphologisches Jahrbuch, Vol. XXVII, pt. 2, 1899, p. 307.

Macalister, A. "On the arrangement of the pronator muscles in the limbs of vertebrate animals." Journ. of Anat. and Phys., Vol. III, 1869, p. 335.

Macalister, A. "The muscular anatomy of the Gorilla." Proceedings of the Royal Irish Academy, Sr. 2, Vol. I, 1870-74, p. 501.

Macalister, A. "A text book of human anatomy." London, 1889.

Mayer. "Zur Anatomie des Orang-Utang und des Chimpanse." Archiv für Naturgeschichte, Berlin, 1856, p. 281.

Melzer, W. "Zur Homologie der menschlichen Extremitäten." Internat. Monats. für Anat. und Physiol., Vol. XI, 1894, p. 194.

Owen, R. "Myology of Simia Satyrus." Proceedings of the Zoological Society of London, Part I, 1830-31, p. 28.

Owen, R. "On the osteology of the Chimpanzee and Orang-Utan." Transactions of the Zoological Society of London, Vol. I, 1835. p, 343.

Owen, R. "Osteological contributions to the natural history of the Chimpanzees, etc." Transactions of the Zoological Society of London, Vol. III, 1848, p. 381.

Pfitzner. "Bemerkungen zum Aufbau des menschlichen Carpus." Verhandlungen der anatomischen Gesellschaft, Göttingen, 1893, p. 186.

Quain's "Elements of Anatomy," tenth edition, edited by Schäfer and Thane. 1892.

Ranke, H. "Ein Saugpolster in der menschlichen Backe." Archiv für Path. Anat. und Phys., Vol. XCVII, 1884, p. 527.

Robinson, Louis, M.D. "The meaning of a baby's footprint." The Nineteenth Century, Vol. XXXI, 1892, p. 795.

Ruge, Georg. "Untersuchung über die Extensorengruppe am Unterschenkel und Fusse der Säugethiere." Morphologisches Jahrbuch, Vol. IV, 1878, p. 592.

Ruge, Georg. "Zur vergleichenden Anatomie der tiefen Muskeln in der Fusssole.' Morphologisches Jahrbuch, Vol. IV, 1878, p. 644.

Schmidt, Oscar. "The Mammalia in their Relation to Primeval Times." London, 1885.

Schulze, F. Eilhard. "Die Sehnenverbindung in der Planta des Menschen und der Säugethiere." Zeitschrift für wiss. Zool., Vol. XVII, 1867, p. 1.

Smith, W. Ramsay. "The function of the Peroneus tertius muscle." Edinburgh Medical Journal, 1892, p. 632.

Sutton, J. Bland. "Ligaments, their nature and morphology." London, 1887.

Symington, Johnston. "The topographical anatomy of the child." Edinburgh, 1887.

Testut, L. "Le long fléchisseur propre du pouce chez l'homme et chez les Singes." Bulletin de la Soc. Zool. de France, Vol. VIII, 1883, p. 164.

Testut, L. "Traité d'Anatomie Humaine." Troisième édition, Paris, 1895.

Testut, L. "Les anomalies musculaires." Paris, 1892.

Thilenius, G. "Ueber Sesambeine fossiler Säugetiere," Anatomischer Anzeiger, 1894-5, p. 42.

Thilenius, G. "Die 'Uberzähligen' Carpuselemente menschlicher Embryonen." Anatomischer Anzeiger, 1894, p. 665.

Turner, W. "On variability in human structure, with illustrations from the flexor muscles of the fingers and toes." Transactions of the Royal Society of Edinburgh, Vol. XXIV, 1867, p. 175.

Turner, W. "Some distinctive characters of human structure." Report of the British Association for the Advancement of Science, 1897, p. 768.

Tyson. "Orang-Outang, sive Homo Sylvestris, or the anatomy of a Pygmie compared with that of a Monkey, an Ape and a Man." London, 1699.

Vrolik, W. "Recherches d'Anatomie comparée sur le Chimpansé." Amsterdam, 1841.

Wagstaffe, W. W. "Partial deficiency of the tendon of the long flexor of the thumb." Journ. of Anat. and Phys., Vol. VI, 1872, p. 212.

Wood, J. "Variations in Human Myology." Proceedings of the Royal Society of London, Vol. XV, 1867, p. 229.

Wood, J. (2). "On human muscular variations and their relation to comparative anatomy." Journ. Anat. and Phys., Vol. I, 1867, p. 44.

Young, A. H. "The intrinsic muscles of the marsupial hand." Journ. Anat. and Phys., Vol. XIV, 1879, p. 149.

Zuckerkandl. Discussion on Pfitzner's paper. "Bemerkungen zum Aufbau des menschlichen Carpus." Verhandlungen der anatomischen Gesellschaft, Göttingen, 1893, p. 193.

UNIVERSITY OF TORONTO STUDIES

History, 1st Series: Review of Historical Publications relating to Canada, edited by Professor GEORGE M. WRONG and H. H. LANGTON.

Vol. I. Publications of the year 1896.
Vol. II. Publications of the year 1897.
Vol. III. Publications of the year 1898.
Vol. IV. Publications of the year 1899.
Each $1.00

History, 2nd Series, No. 1: Louisbourg in 1745, the anonymous "Lettre d' un Habitant de Louisbourg," edited and translated by Professor GEORGE M. WRONG 75

History, 2nd Series, No. 2: Preliminary Stages of the Peace of Amiens, by H. M. BOWMAN 75

Economic Series, No. 1: Public Debts in Canada, by J. ROY PERRY 50

Psychological Series, No. 1: Spatial Threshold of Colour and its Dependence on Contrast Phenomena, by W. B. LANE, with Appendices 75

Psychological Series, No. 2: A Contribution to the Psychology of Time, by M. A. SHAW and F. S. WRINCH .....
Psychological Series, No. 3: Experiments on Time Relations of Poetical Metres, by A. S. HURST and JOHN MCKAY 75

Biological Series, No. 1: The Gametophyte of Botrychium Virginianum, by E. C. JEFFREY 50

Physiological Series, No. 1: The Structure, Micro-Chemistry and Development of Nerve-Cells, with Special Reference to their Nuclein Compounds, by F. H. SCOTT 50

Physiological Series, No. 2: On the Cytology of Non-Nucleated Organisms, by Professor A. B. MACALLUM 75

EXCHANGE
MAY 14 1919

UNIVERSITY OF TORONTO STUDIES

ANATOMY

No. 2: THE SKULL OF A HUMAN FETUS OF 40 MM., BY CHARLES CLIFFORD MACKLIN

(REPRINTED FROM THE AMERICAN JOURNAL OF ANATOMY, VOL. XVI)

THE UNIVERSITY LIBRARY: PUBLISHED BY
THE LIBRARIAN, 1914

University of Toronto Studies

COMMITTEE OF MANAGEMENT

Chairman: ROBERT ALEXANDER FALCONER, M.A., Litt.D., LL.D., D.D.
President of the University

PROFESSOR W. J. ALEXANDER, PH.D.

PROFESSOR W. H. ELLIS, M.A., M.B.

PROFESSOR J. J. MACKENZIE, B.A.

PROFESSOR J. P. MCMURRICH, PH.D.

PROFESSOR G. H. NEEDLER, PH.D.

PROFESSOR GEORGE M. WRONG, M.A.

General Editor: H. H. LANGTON, M.A.
Librarian of the University

Reprinted from THE AMERICAN JOURNAL OF ANATOMY, VOL. 16, NO. 3
July, 1914

THE SKULL OF A HUMAN FETUS OF 40 MM.

CHARLES CLIFFORD MACKLIN
James H. Richardson Fellow in Anatomy, University of Toronto

EIGHTEEN FIGURES

CONTENTS

Introduction 317
The skull as a whole 319
Cartilage 321
Chondrocranium 328
Planum basale 328
Regio occipitalis 332
Regio otica 352
Thirteen plates (eighteen figures) 371
Regio orbitotemporalis 387
Regio ethmoidalis 398
Visceral arches 411
Meckel's cartilage 411
Reichert's cartilage 415
Membrane bones 415
Conclusion 423
Bibliography 424

INTRODUCTION

Researches upon the developing human skull have been carried on by various investigators, for a summary of whose results reference may be made to the excellent reviews by Jacoby ('94) and Levi ('00). The plate method of reconstruction, however, has been applied in such investigations only within recent years, and has been used in the study of fetuses in the following stages:

LENGTH	PROBABLE AGE (AUTHOR'S ESTIMATE)	AUTHOR
mm.		
13		Levi
14	37–38 days	Levi
17	42–45 days	Levi
17	50 days	v. Noorden
18.5	7½ weeks	v. Noorden
23	8½ weeks	v. Noorden
30		Jacoby (younger than the 28 mm. stage of Levi)
28	58–62 days	Levi
30		Fawcett
80		Hertwig

It will be seen that a considerable interval occurs between the last two stages in this list, and with a view towards lessening it I undertook, at the suggestion of Professor McMurrich, the study of the skull of a fetus of 40 mm., crown-rump measurement, which would correspond, according to Mall's formula (Mall '06, p. 439), to an age of 63 days. The entire head of the fetus had been cut into serial sections in the frontal plane, the sections being 20 micra in thickness and stained with haemalum followed by erythrosin. From these sections the entire skull, together with the membrane bones and upper two visceral arches, was reconstructed by the wax plate method at an enlargement of 30 diameters, and, to facilitate the study of the nasal and otic capsules, separate models were made, at the same magnification, of the mesethmoid, ectethmoid, right otic capsule and the anlage of the right osseous labyrinth. Drawings were made of every other section by the use of Edinger's "Drawing and projection apparatus," only that tissue being included as cartilage which presented a homogeneous, blue ground-substance and could be clearly differentiated from its surroundings, i.e., the tissue which Levi ('00) has described under the terms 'alteren Vorknorpel' or older precartilage, and "Knorpel" or cartilage. The earlier chondrogenic tissue of which there was very little at this stage, was disregarded.

The sections were not exactly in the frontal plane and to eliminate any lateral distortion in the models the amount of obliq-

uity was determined as accurately as possible and the wax plates piled upon a plane adjusted at the proper inclination. It is also to be noted that a few sections passing through the dorsal extremity of the occiput were wanting from the series, and the small portion of the occipital region which they represented has been reconstructed by reference to other models, the parts so added being painted white, so that they may readily be recognized.

In the following description of the models I have used, as far as possible, the terms which are current in the literature, and when those referring to the human skull were exhausted recourse was had to the terminology in use in the more recent publications upon the chondrocrania of mammals. Preference is given to the BNA, and names not hitherto introduced into human chondrocraniology are usually followed by the name of the author who has employed them, the ideal being always kept in view of a system of terms uniform throughout the mammalian forms at least. New names, introduced by the writer, are indicated by making their initial appearance in italics.

An attempt has been made to select such terms of orientation as may be applied to animals having either a horizontal or a vertical long axis. Thus the terms ventral, dorsal, cranial, caudal, lateral and medial are generally used, but their respective equivalents for the human figure, such as anterior or front, posterior or back, superior or upper, inferior or lower, external or outer, internal or inner, are also employed. Oblique directions are indicated by combinations of the above terms.

Measurements appearing in the text have been taken from the models, and are thus magnified thirty times.

THE SKULL AS A WHOLE

The primitive skull of homo at the 40 mm. stage presents, in general, the characters which have become familiar through the illustrations and descriptions of v. Noorden, Jacoby and Levi for younger embryos, and the model of Hertwig for a more advanced age, combined with several features that are characteristic of this period of development. The outline, when the many gaps are filled in, suggests the osseous skull.

Viewed from above (fig. 1) we note the entire absence of the roof and the extremely rudimentary character of the sides of the cranial vault. The eye meets with an irregular surface of varying depth, surrounded by a broken, ovoid contour, the smaller end being ventral. This surface we recognize as the floor of the primitive brain-case. Its dorsal half is made up of the future posterior cranial fossa, a deep, bowl-like enclosure, the steep sides of which slope rapidly down to an elongated opening in the floor—the primitive foramen magnum. In the ventral wall of this fossa is a trough-like space behind the basilar plate, flanked by two rounded eminences, the partes cochleares of the otic capsule, and terminated above by the horned, ridge-like dorsum sellae, which forms a conspicuous object in the floor of the cranium. Passing forward over this ridge a sideless pit, the hypophyseal fossa, comes into view, which marks the center of the middle cranial fossa, and here, in the region of the body of the sphenoid, the cartilaginous floor is very narrow. Lateral to the corpus sphenoidale is a large, triangular gap in the floor and sidewall of the brain-box, the apex of which meets the side of the sella, while the ventral and dorsal borders are formed by the dorsal border of the ala orbitalis and the cranio-ventral surface of the otic capsule respectively. Forming a lateral, knobbed projection beneath the ala orbitalis is the relatively small ala temporalis, and this is observed to lie ventro-caudal to the plane of the above-mentioned triangular space, just as, in the osseous skull, the greater wing lies below and in front of the plane joining the lesser wing with the petrous portion of the temporal bone. As will be seen later, this plane corresponds in a general way to the situation of a primitive floor and side-wall of this region of the skull, as found in the lizards. Two of the bones which will later wall in this space, viz., the parietal and the squamo-temporalis, are as yet very rudimentary, while the third, or ala temporalis, has only just commenced to ossify.

We now pass forward, over the low ridge in front of the sella turcica, known as the tuberculum sellae, and come upon the plateau-like surface supporting the optic chiasma, which leads laterally into the optic foramina. Ventral to this surface is the

wide, upward-slanting, anterior root of the ala orbitalis, in front of which is a broad, flattened, triangular surface. This we recognize as the floor of the anterior cranial fossa. Perforating it, in the area lateral to the median septum, which represents the developing cribriform plate, are several foramina, the largest being the paired fenestrae cribrosae. Hook-like, backwardly projecting processes mark the dorso-lateral limits of the floor, which ventro-laterally is widened by the orbital plate of the frontal bone.

The only portions of the osseous cranial vault yet in evidence are the rudimentary frontal portion of the frontal bone and the net-like parietal—these being separated by a rather wide space.

Finally, the cranial aspect discloses to view certain accessory cartilages. Above the dorsal wall of the posterior cranial fossa may be seen two cartilages, lying close together, both small, but the left considerably smaller than the right. They may be known as the *cartilagines cranii posteriores*. Above each parietal plate, medial to the parietal bone, is seen an isolated nodule of cartilage, that on the right being larger and more elongated than that on the left; these may be called the *cartilagines cranii laterales*. Below and in front of the cranial pole of each cochlea there is a small, rounded mass of cartilage, which may be termed the *cartilago supracochlearis*.

CARTILAGE

Passing, next, to a consideration of the lateral aspect of the primitive skull (fig. 3), we note that it is made up of two main masses, dorsal (posterior) and ventral (anterior), almost separated by a large gap between the otic and orbitotemporal regions. The dorsal region is composed principally of cartilage, and presents a fairly smooth, convex, fenestrated surface, the most lateral part being formed by the rounded outer wall of the pars canalicularis of the otic capsule. Behind this the flat surface is seen to widen, and then quickly narrow, and to sweep backwards and inwards to unite with the corresponding plate of the opposite side in the tectum posterius. Above, the wall is heightened

by the reticular parietal bone (fig. 4). These structures enclose the lower and posterior portion of the cranial cavity.

The anterior mass is composed principally of the facial parts, and contrasts with the posterior in being narrower from side to side in its lower part, and in presenting a greater proportion of osseous material. Its surface is also much more irregular and uneven. In front of the pars canalicularis we see, in a recess which lies ventro-lateral to the two parts of the otic capsule, an irregular mass of cartilaginous and osseous structures, in which we recognize the anlagen of the auditory ossicles and the upper part of Meckel's cartilage, the latter appearing above the small tympanic and goniale (fig. 2), and being covered laterally by the squamo-temporalis. Below these structures, with its hook-like proximal extremity lying in a small cavity, but unconnected with the rest of the chondrocranium, is the slender shaft of Reichert's cartilage.

Above the otic capsule the large open space which will later form the middle cranial fossa is again apparent, and through this we see the lateral aspect of the hypophyseal fossa (fig. 3), with the high dorsum sellae, upon which are the ventrally projecting posterior clinoid processes, limiting it posteriorly. In the anterior wall of the sella turcica is the middle clinoid process (present on the right side only) and above this is to be seen the orbital wing of the sphenoid, the gentle curvature of the latter being broken by the anterior clinoid process, and its outer and posterior extremity terminated by a sharp process, projecting dorsally. Below the ala orbitalis, and separated from it by the wide and unclosed superior orbital fissure, is the ala temporalis, supported by a short processus alaris, the rounded extremity of the latter almost touching the ventral pole of the cochlea, and being quite close to the cartilago supracochlearis, which is plainly visible from the side.

Looking at the skull from a more anterior position we see, above, the cavity of the orbit, roofed over by the cartilage of the orbital wing of the sphenoid, and by the orbital portion of the frontal bone (fig. 4); limited medially by the shelving posterior portion of the ectethmoid; but widely open downwards and out-

wards, except where cut off by the zygomatic bone and the maxilla, and but imperfectly closed behind. In the posterior portion of the orbit is seen the elongated optic foramen, and the closeness of apposition of the sphenoidal and ectethmoidal cartilages is to be observed. An open space, communicating freely above with the orbit, below with the cavity of the mouth and medially with that of the pharynx, is seen in front of the ala temporalis, the medial wall of the space being indicated by the imperfectly developed vertical plate of the palatine bone and by the rudimentary medial pterygoid plate. The position of the as yet unformed pterygomaxillary fossa is indicated in this space by the sphenopalatine ganglion (fig. 14) (not shown in the model), and lateral to this, bounded by the incomplete zygomatic arch, are the temporal and zygomatic fossae. One is struck with the lack of prominence of the zygomatic region when compared with the osseous skull, the zygomatic bone and arch being completely overhung by the lateral part of the cranial floor. That this disproportion is partly due to the shallowness of the temporal and zygomatic fossae is evident from a comparison of the model with the bony skull. It would appear that the lateral growth of the ala temporalis of the sphenoid and of the zygomatic process of the maxilla, combined with thickening of the temporalis muscle, are the principal factors which bring about the widening of the temporal and zygomatic fossae, and consequent outpushing of the lateral parts of this area. It is evident from a comparison of the skulls of the newborn and the adult that this change continues till some time after birth.

The lower part of the facial region is characterized by the gaping cavity of the mouth, bounded above by the superior maxilla and below by Meckel's cartilage with its covering bone, the mandible (fig. 4). The lack of prominence of the angle of the latter, due to the shortness and inclination of the ramus and its relative nearness to the medial sagittal plane, may be observed, and it will also be seen that there is a small space between the articular process of the mandible and the position of the future glenoid cavity of the squamo-temporalis (fig. 4). The coronoid process of the mandible is quite close to the ala temporalis of the

sphenoid, medially, and to the zygomatic arch (as yet incomplete) laterally, a condition which does not obtain in the mature skull.

Dorsal to the prominent frontal process of the superior maxilla the isolated nodule of cartilage, known as the cartilago paranasalis, is to be seen, lying lateral to the cavity for the lacrimal duct and below the small streak of membrane bone, which is the anlage of the future lacrimal. Another smaller nodule of cartilage is seen near the back of the orbit lying against the upper surface of the ectethmoid and may be known as the *cartilago paraethmoidalis*. Separating the orbital from the nasal cavity is to be seen the shell-like ectethmoid, bearing upon its cranio-ventral aspect the small nasal bone. At the front of the nasal cartilages appear the open anterior nares, separated by the ventral border of the septum.

Regarded from below (fig. 2) the model shows in the foreground the mandibular (not shown in fig. 2) and upper part of the hyoid arches. Behind these we see the semi-cylindrical ventral surface of the planum basale, separated from the elongated, flattened, ovoid partes cochleares by deep furrows. It is to be observed that the anterior extremities of the latter do not project beyond the planum. The forked structure at the root of the planum, perforated for the hypoglossal nerve, is seen to be the anterior commencement of the flattened, ring-like sides of the foramen magnum, a downwardly projecting angle marking the position of the future occipital condyle. Lateral to and above the condyle there appears a stout cartilaginous process, which supports the lower and anterior part of the otic capsule. This is known as the processus paracondyloideus (Voit), and above it is seen a wide opening, the jugular foramen (fig. 4).

The two Meckelian cartilages (fig. 3) enclose an angle, rather sharp ventrally; in which are found the structures of the floor of the mouth. The inwardly curved palatine bones, with the assistance of the inner laminae of the pterygoid processes (fig. 2), imperfectly cut off the posterior part of the nasal cavity, and between the pterygoid laminae and the planum basale is seen the space occupied by the naso-pharynx (fig. 10). Attached to these medial laminae, and indeed developed from their caudal tips, are

the cartilagines parasphenoidales (Voit, '09), the representatives of the later hamular processes. The pterygoid laminae are quite separate from the alae temporales, which appear, from this viewpoint, as rhomboidal, perforated blocks.

Lying along the caudal border of the nasal septum are seen the anterior paraseptal cartilages in front, and the long thin plates of the vomer behind (fig. 2); and within each nasal cavity is a small mass of cartilage, lying in the middle meatus (fig. 12), to which the name *cartilago meatus medii* has been given and whose significance will be discussed with the regio ethmoidalis.

Summing up the cartilaginous and osseous structures which we find participating in the formation of the primitive skull, we have to consider a main cartilaginous mass, or chondrocranium, a number of accessory cartilages, the upper visceral arches, and the membrane bones.

The chondrocranium is a complicated mass of cartilage of exceedingly irregular formation, in which a number of definite areas may be recognized. Upon examination it is seen to consist of a larger dorsal and a smaller ventral enlargement, united by an isthmuslike part, the body of the sphenoid. A median stem, bent to enclose an angle of 115° open caudo-ventrally, forms the main axis, this being made up dorsally of the flattened planum basale and ventrally of the interorbital and nasal septa, or, employing the terms of Kölliker, the pars chordalis and the pars praechordalis respectively. These limbs are united by the corpus sphenoidale, or Balkenplatte of the German authors, which forms the apex of the angle. The four primary regions of the chondrocranium, which Gaupp has named, from behind forwards, the regio occipitalis, the regio otica, the regio orbitotemporalis and the regio ethmoidalis, are all represented in the median stem, in the order named, the first two being found in the pars chordalis and the second two in the pars praechordalis.

Springing out from the sides of the planum we have the walls of the posterior cranial fossa, while to the ventral end of the axis are affixed the side parts of the ethmoidal and orbitotemporal regions.

If the structures lateral to the ventral limb of this stem be removed, we have an object which roughly resembles a dipper or saucepan, the curved handle being made up of the ventral part of the stem, while the bowl, perforated below and at the sides, is formed ventrally by the planum basale, and laterally and dorsally by the walls of the posterior cranial fossa, the median lip being situated at the tectum posterius.

The chondrocranium is, at this stage, a continuous morphological unit, but there is histological evidence going to show that certain of its parts were primarily separate.

In addition to the chondrocranium proper a number of accessory cartilages, which have no direct connection with it and which have already been mentioned, also occur. They will be discussed in connection with the regions to which they refer, and are as follows:

Cartilago cranii posterior	Regio otica
Cartilago cranii lateralis	Regio otica
Cartilago supracochlearis	Regio otica
Cartilago parasphenoidalis	Regio orbitotemporalis
Cartilago paraethmoidalis	Regio ethmoidalis
Cartilago paranasalis	Regio ethmoidalis
Cartilago meatus medii	Regio ethmoidalis

Of the recorded human embryonic skulls that of Levi ('00) for the 28 mm. stage most closely resembles my specimen, but is somewhat younger. The next nearest stage, represented in the Ziegler model of Hertwig's 80 mm. embryo, is somewhat older.

The principal change which has occurred in the interval between the 28 and 40 mm. stages appears to be the development of the anterior cranial fossa. In the Levi specimen this is relatively narrower and deeper than in mine, thus indicating an adaptation of this region to the increasing size of the anterior part of the brain. Levi notes that this part of the skull has made more rapid development than any other in the interval between the 17 mm. and 28 mm. stages, and in the latter it is evidently still making rapid progress. When my model is compared with that of Hertwig, however, it is seen that in the period

between the 40 and 80 mm. stages the posterior fossa has made greater strides than the anterior, thus seeking to accommodate the enlarging, backwardly-growing cerebral hemispheres. The extent of development of the posterior portion of the brain-case in the interval between the 40 and 80 mm. stages will be realized when the ratio of the areas dorsal and ventral to the hypophyseal fossa, as they are found in the model of Hertwig and in my preparation, are compared. Although the dorsal area exceeds the ventral in my model the excess is by no means so great as it is in Hertwig's.

Speaking generally, since the 28 mm. stage of Levi there has been a flattening of the entire cranial floor. Between the 40 and 80 mm. stages the zone of greatest enlargement has been the upper edge of the posterior cranial fossa, the effect being as though this part had become stretched while the part around the foramen magnum had remained relatively stationary. The result is that the brain-case in this region has become more shallow and the sides more flaring, with their lateral and dorsal surfaces directed more caudally than outwardly. The region above the parietal plates has shared in this expansion, as is seen by the more widely placed parietal bones in the model of Hertwig, and this period of development has also witnessed the flattening out of the angle from the cranial aspect of the otic capsule, as may be seen when these skulls are compared.

Other expansive changes which have taken place in the interim between the 40 and 80 mm. stages are noted in the region of the middle ear, in the floor of the mouth, and in the temporal and zygomatic fossae, the details of which will be taken up in the discussion of the regions. In general one is struck with the large development of the cranial cavity, which gives to the Hertwig model a relative broadness when seen from the front, and has also resulted in a greater preponderance of the size of the cranium when compared with the facial region. A comparison of the Hertwig model with that of Jacoby for the 30 mm. stage brings out an even greater disproportion.

Of the skulls of other mammals those of Macacus cynomolgus and Semnopithecus maurus, modelled by Fischer ('03), may be

mentioned. The similarity in general outline is quite striking, when these are compared with my specimen. The illustration of the caudal aspect of the skull of Macacus shows a flattened condition of the partes cochleares closely analogous to that which obtains in my model. Though the dorsal part of the cranium is relatively shorter it is very suggestive of the cranium of homo, especially from the rudimentary condition of the side-walls.

CHONDROCRANIUM

Planum basale

That portion of the central stem of the chondrocranium which forms its dorso-caudal limb and is traversed medially and longitudinally by the notochord, is known as the planum basale (figs. 1, 2 and 5). It is an elongated and unperforated plate of cartilage of varying thickness, which extends from the intercondylar incisure of the foramen magnum to the dorsal border of the hypophyseal fossa, and forms the most dorsal part of the skull-base. Its cartilaginous substance is directly continuous with that of three regions; with the occipital region caudodorsally where the planum is seen to pass over into the lateral portions of the occipital anlage, with the orbitotemporal region cranio-ventrally, where it coalesces with the body of the sphenoidal cartilage at the dorsum sellae, and with the otic region laterally. The entire lateral border, with the exception of the extreme upper portion, is united to the pars cochlearis of the otic capsule, the line of union being indicated upon the medial surface of the latter by an elongated, narrow, crescentic strip (fig. 7). This line of union is formed of cartilage throughout, and in its cranial two-thirds this is of the same character as that of the adjoining parts. In the lower third, however, there is to be seen, microscopically, a distinct but thin sheet of younger cartilage, separating the adjacent parts of the planum and the cochlea, this being the last indication of the primitive separation of these parts.

It is worthy of note in passing that the 17 mm. stage of Levi shows the first indication of a union in the human skull between

the otic capsule and the planum basale, the cranialmost extremity of this bridge being the first to appear.

Encircling the zone of union of the pars cochlearis with the planum is a well-marked groove. The posterior portion of this, which may be known as the *dorsal basicochlear groove* (fig. 5), is crescentic in outline, and is fairly well defined. It contains the inferior petrosal sinus, and appears more sharply marked than in the models of Levi and Jacoby, judging from the illustrations of these authors. The ventral portion—much deeper and narrower—is also crescentic, and may be termed the *ventral basicochlear groove* (fig. 2). These grooves meet, above and below, their confluences being marked by notches, designated the *sphenocochlear* and *occipitocochlear notches* (fig. 5) respectively. The sphenocochlear notch occupies the interval between that part of the lateral surface of the corpus sphenoidale which lies dorsal to the processus alaris, medially, and the medial aspect of the cranial pole of the pars cochlearis, laterally (fig. 1). It is narrow and deep. The occipitocochlear notch is the ventromedial extremity of the jugular foramen.

Viewed from behind (figs. 1 and 5) the planum is seen to be concave from side to side in its lower two-thirds, and caudocranially throughout its entire extent. The cranial third of the dorsal surface terminates above in the crista transversa, a transverse ridge from which the dorsum sellae springs upwards, and which, according to Voit, may be taken to mark roughly the boundary between the body of the sphenoid and the otic or upper portion of the planum basale. This area of the dorsal surface is convex from side to side, and covers the part of the planum which has been called the clivus of Blumenbach. The lower portion of the planum is quite steep, but the cranial portion is much more so, the inclination thus agreeing with the description given by Levi for the 28 mm. stage.

The ventral surface of the planum (fig. 2) is convex from side to side, and almost straight caudo-cranially. It is thus evident that the caudal and cranial extremities are thicker than the middle portion, the latter being in the position of a primitive gap in the cartilage as shown by Levi in the 13 mm. and 14 mm.

stages and by Froriep in the 17.5 mm. stage, the latter having found the planum broken by a gap, filled with perichondrium, 1.9 mm. behind the canal of the hypophysis. This was just dorsal to the region where the occipitopharyngeal ligament, which had disappeared in older embryos (Levi), was inserted. This primitive gap (of which there is no evidence in my model, except the relative thinness of the cartilage in this region—and in this my findings agree with those of Levi and Jacoby for the 28 mm. and 30 mm. stages respectively—marks the site of the division which exists in early stages, between the two constituent parts of the planum, viz., that lying below it, belonging to the occipital region and representing the anlage of the future basi-occipitalis, and that lying above it, the clivus of Blumenbach, which is destined to form the basi-sphenoidalis, and has been included in the otic region.

The connection of the clivus with the body of the cartilaginous sphenoidal anlage is very primitive, according to the investigations of Levi upon young human embryos, as in the 13 mm. stage it is present while as yet there is no cartilaginous otic capsule in existence. This circumstance, combined with the relationship of the clivus to the basi-sphenoidalis of the osseous condition would seem to indicate that the upper portion of the planum should be grouped with the regio orbitotemporalis rather than with the regio otica, and this has been done by Levi, Jacoby and Van Noorden, but since Gaupp has more recently shown that the upper portion of the planum is more properly included with the otic region, and as several authors have since followed this course for the mammals (Voit, Mead) I shall adopt it in this description. The more minute details of the occipital and otic portions of the planum will be considered in the discussion of these regions.

The material composing the planum basale is mature cartilage, of uniform character, excepting one small, isolated mass of enlarged, vacuolated, cartilage cells, the nuclei of which appear larger and more darkly-staining than those of the surrounding areas, and the ground-substance of which has stained a dark

purple, thus standing in sharp contrast to the bluish matrix of the cartilage. This mass appears to be opposite the first part of the sub-basal course of the chorda dorsalis, and lies just ventro-caudal to the middle of the long axis of the planum. It belongs to the occipital portion, and is separated from the perichondrium by a thin sheet of mature cartilage. The perichondrium in the vicinity of this mass is unchanged, and contains no osseous tissue. In the 28 mm. stage of Levi the cells were, in this area, very large, and were surrounded by a very prominent capsule. We have in this area, no doubt, the beginning of the endochondral ossification center of the basi-occipitalis, which is said by Mall ('06) to appear on the 65th day.

The course of the chorda dorsalis has become familiar through numerous investigations, and I have nothing to add concerning it. The condition which I find agrees essentially with that illustrated by Fawcett for the 21 mm. stage (Fawcett '10a, fig. 2). The site of the future ligamentum suspensorium dentis, at the apex of the intercondyloid incisure, is marked by a coiled condition of the notochord, which corresponds to an intervertebral disk.

In my model the caudal portion of the planum is but slightly wider than the cranial, a condition which stands in sharp contrast to that found in the model of Hertwig, where one notices that, though the entire planum has undergone a widening, the region bordering the primitive foramen magnum has outstripped the more cranial portion in this regard. This broadening has, of course, separated the caudal extremities of the ventral and dorsal basicochlear grooves. The latter are both shallower and less strongly marked than in my model, as are also the sphenocochlear notches. Further, the side-to-side concavity in the model of Hertwig is almost obliterated, as is also that from above downward, and the inclination of the planum in the latter model is less steep than in mine.

Regio occipitalis

The occipital region has, in general, the form of a ring, whose irregular circumference, stoutly built and steeply sloping ventrally, plate-like and gently shelving dorsally, encloses the lower part of the posterior cranial fossa, the floor of which is perforated by an elongated fissure, the primitive foramen magnum (fig. 1). Its appearance suggests the occipital bone, of which it is the cartilaginous precursor.

Ventrally the ring is completed by a dorsally concave plate of cartilage, the basilar portion of the occipital anlage, which has been described as the lowermost part of the planum basale. As we have seen, the basilar portion is directly continuous cranially and laterally with the regio otica; below it splits to form the condyloid or lateral portions of the regio occipitalis, which spring downwards, outwards and slightly backwards and enclose, with their deviating, flattened limbs, the incisura intercondyloidea, marking the ventralmost part of the primitive foramen magnum. Reaching the most caudal points of the primitive skull at the paired, downwardly projecting ventral foraminal prominences (figs. 2 and 3), upon the site of the future condyles of the occipital bone, they suddenly bend upwards and outwards, twist on their long axes so that the inner surfaces, which before looked dorsomedially now look principally cranially, and at the same time they broaden ventrally and laterally, their outermost borders coming to underlie and support the partes canaliculares of the otic capsules. The lateral wing-like plate, which is thus formed on each side, is really the ventral and narrowest part of the squamous portion, and is known as the lamina alaris (Voit) (fig. 5). Ventrally it terminates in the prominent processus paracondyloideus, (figs. 2, 3 and 4) which may be seen from the front projecting laterally from the outer surface of the condyloid portion; dorsally it broadens into the squama, which becomes steeper, and swings medially to pass into the tectum posterius (fig. 5). The upper border, after skirting the dorsal surface of the ear capsule, passes backwards and inwards, being continuous above

with the lower border of the parietal plate; the lower border forms the lateral and dorsal boundary of the primitive foramen magnum.

When regarded from the front (fig. 2) the lateral or condyloid portions appear as paired, caudo-lateral extensions of the planum basale, their outer surfaces being simply continuations of the ventral convex surface of the planum; or, stating the same thing another way, if the anterior surface of the planum be regarded as a section of a cylinder, then the outer surfaces of the lateral portions may be looked upon as localized widenings of the same. The upper boundary of each may be arbitrarily marked off by a line drawn from the tip of the occipitocochlear notch to the ventral foraminal prominence (fig. 5), cutting just ventral to the hypoglossal canal, and representing approximately the line of separation which exists between these elements as they occur in their osseous condition at birth. The caudal portion of the planum thus includes the intercondylar incisure. Piercing the outer surface of the lateral portion, which looks ventro-laterally, is seen the outlet of the hypoglossal canal (fig. 2). Upon reaching the external edge of the latter the outer surface becomes narrow, and passes directly outward upon the aforementioned processus paracondyloideus.

Seen from behind, the inner surfaces appear as caudolateral continuations of the side-to-side concavity of the dorsal surface of the planum (figs. 1 and 5). They look medially, dorsally and somewhat cranially, and present the inlet of the hypoglossal canal. The lower borders are by far the thicker, and form the lateral limits of the incisura intercondyloidea, and each, as has been noted, passes over the ventral foraminal prominence to be thence continued dorsally as the lateral border of the foramen magnum (fig. 2). This portion of the border of the foramen, and the lower border of the condyloid portion, much resemble one another in thickness and roundness on cross-section, and when the skull is regarded from the side the ventral foraminal prominence, formed by their approximation, appears as the apex of an angle directed downwards and slightly forwards (fig. 3).

The rounded upper border broadens dorso-laterally and bifurcates to enclose the hollow jugular recess (fig. 5), the ventral limb passing laterally to become the ventral border of the processus paracondyloideus (figs 2. and 4), while the dorsal is marked, at its termination, by a small eminence, the anlage of the future jugular tubercle (fig. 5).

The hypoglossal canal, whose inlet and outlet have been noted, pierces the condyloid portion in a direction from within outwards and forwards. It lies rather nearer the upper than the lower border, between the jugular tubercle above and the ventral foraminal prominence below. The right canal is unpartitioned, but the left presents a bar of cartilage which separates its inner third into cranio-ventral and caudo-dorsal inlets. This bar has a general direction from above downwards, forwards and inwards (fig. 5). The outer two-thirds of this canal is not divided.

When the sections are followed from behind forward it is noted that two fasciculi of the hypoglossal nerve come into close apposition, one with the other (though they remain, for a time, separated by their sheaths), just dorsal to the entrance of the hypoglossal canal. These are of about equal size, and pierce the dura as a single strand, to enter the canal (on the left side the caudo-dorsal inlet) after a short sub-dural course. A third strand, equal in size to the first two combined, may be seen to pierce the dura shortly after the first two, but remains separated from the latter (on the left side by the aforementioned septum) while traversing the canal. Upon emerging the strands unite and shortly after their exit they become intimately associated with the vagus. In the canal they are accompanied by some small veins—the anlage of the rete of the hypoglossal canal—and a small artery. The great bulk of the canal space is, however, filled with loose connective tissue.

The processus paracondyloideus,[1] already referred to more than once, forms a conspicuous object as it springs from the

[1] It may be here noted that Voit uses the term "processus paracondyloideus" to apply only to the outer projecting tip (as it is found in the skull of the rabbit) of the structure which I have designated by this term. Mead, in describing the skull of the pig, uses the name "processus paroccipitalis" with the same meaning

outer surface of the condyloid portion just lateral to the hypoglossal canal (figs. 2 and 4). The straight line which joins the outermost tips of the processes passes through their roots also, and meets the median sagittal plane at a right angle, thus showing that each process is perpendicular to the sagittal plane of the head. The coronal plane in which this line lies cuts the ventral foraminal prominences. Each process is prismatic in shape, and thus presents three surfaces, which meet at the most lateral point, or tip. The medial part of the cranial surface is hollowed for the recessus jugularis; the lateral part lies outside of the cranium (fig. 4), its convex area forming the outermost termination of the caudal delimitation of the jugular foramen. Immediately above this convex surface appears the proximal, curved end of the cartilage of Reichert. The remaining surfaces look ventro-caudally and dorso-caudally respectively, and are separated by the caudal border, which projects downwards in a ridge-like manner (figs. 2 and 3), and forms a prominent object, when the skull is regarded from below, as it springs laterally from the outer part of the ventral foraminal prominence. The dorsal border is continuous with the lamina alaris. The ventral border is free (figs. 2, 4 and 5), and is thin in its medial half, where it bounds the recessus jugularis ventrally. From within outwards it follows a curved line, convex ventrally, and, in the region of the recessus jugularis, there is a small cranial concavity, over which the jugular vein and accompanying nerves pass. As has been observed before, this ventral border is the anterior extension of the bifurcated upper border of the condyloid portion.

The left process presents a slight difference when compared with the right. A small foramen (figs. 2 and 5) is seen to tunnel under its ventral border, thus forming a passageway from the recessus jugularis within to the ventro-caudal surface of the process on the outer aspect of the skull. The outlet lies just lateral to that of the hypoglossal canal. Though the right side

as Voit gives to the term "processus paracondyloideus." I have selected the latter term, and used it in a more extended sense, as applying to the entire structure corresponding to the transverse (and perhaps costal) process of the occipital vertebra, since this represents a morphological unit.

does not present this foramen the cartilage in this locality is very thin. The foramen contains nothing but loose connective tissue and its direction is from within downwards and forwards. It may be known as the *paracondyloid foramen*, and appears in the model of Hertwig on the right side only.

The squamous portions form the dorsal, and most of the lateral, part of the occipital ring. The architectural, and, as we shall later see, possibly the developmental foundation of each half, is the crescentic bar of cartilage which forms the lateral boundary of the primitive foramen magnum, and extends between its two prominences (figs. 1, 2 and 5). Rounded in cross-section it is seen to diminish in size gradually and uniformly from before backwards. Ventrally it is directly continuous with the condyloid portion (and may even be looked upon as a backward extension of this), the area of union being marked by the anlage of the future condyle, which has been termed the ventral foraminal prominence. Its principal direction is dorsal and slightly cranial, in contrast to that of the condylar portion, which, as has been noted, is caudal, lateral and slightly dorsal. Its concavity looks medially and slightly caudally, the latter curvature being evident when the skull is regarded from the side (fig. 3). Dorsally it terminates in the paired dorsal foraminal prominences, which mark the entrances into the incisura occipitalis superior. As will be seen later this bar corresponds to the neural arch of the occipital vertebra, and will be hereafter referred to as such. Medial to it is the anlage of the future medulla oblongata. Just above its ventral portion appears the jugular tubercle, and, upon examining the cartilage in this location, the cells are seen to present, from the dorsal part of this tubercle to a point about midway between the foraminal prominences, a condition similar to that which obtains in the central part of the basilar portion. This would seem to point to the beginning endochondral ossification of the ex-occipital portion of the occipital bone, the center for which, according to Mall ('06) appears on the 56th day. The ventral part of this center is confined to the jugular tubercle, but, as the sections are followed backward, it is found that it gradually comes to involve the entire core of the neural arch. The involve-

ment in ossification of the jugular tubercle is to be noted, as this, as we shall later see, is probably to be regarded as the superior articular process of the occipital vertebra.

Springing laterally and dorsally from this neural arch we find the upward-shelving squama, which narrows ventrally into the lamina alaris, and dorso-medially participates in the formation of the tectum posterius. Its lateral portion is widened. The upper border of the squama may be divided into ventral and dorsal portions, the former being connected with the otic capsule, and the latter with the parietal plate (figs. 3 and 5). The ventral part is fitted closely to the caudal and dorsal surfaces of the pars canalicularis of the otic capsule, the line of union being crescentic in shape, with concavity looking upward, forward and outward. This border extends cranio-dorsally from the outer angle of the jugular foramen to the fissura capsulooccipitalis (Voit), and its position is marked on both the inner and outer aspects of the skull by crescentic grooves, formed by the approximation of the flattened occipital and rising otic surfaces. These furrows, which may be known as the *medial* and *lateral capsulo-occipital grooves* (figs. 3 and 5), are not equally well marked, that on the inside of the skull being much the deeper. It contains part of the transverse sinus.

Evidence of an earlier separation between the pars canalicularis and the squama is afforded by the microscopic appearance. Between these structures there is seen, ventrally, a thin sheet of perichondrium, its plane being parallel with the transverse planes of the head, and when the sections are followed dorsally this is found to give place to a cartilage of younger type than that surrounding it, this being traceable almost as far back as the capsulooccipital fissure. The younger condition of the intervening tissue in the region of the jugular foramen as compared with that farther back would seem to indicate that fusion of the parts has taken place in the more dorsal part first, and has gradually progressed forward, and this assumption is born out by examining the illustrations of Levi. In his 14 mm. model (which is the earliest stage in which the otic capsule appears) the pars canalicularis and squama are almost entirely separated

by an elongated fissure extending from the jugular foramen to a small bridge of cartilage which cuts off the capsulo occipital fissure, and it is believed that this long cleft represents the metotic fissure of the lower forms. Upon examining the illustration of Levi's 17 mm. stage it is found that the aforementioned small bridge of cartilage has considerably widened ventro-medially, and in the subsequent 28 mm. stage the squama and the pars canalicularis are united as far as the jugular foramen. In both the 17 and the 28 mm. stages of Levi the union was marked by a separating sheet of perichondrium.

At the caudo-ventral extremity of this union there is seen a small notch, passing laterally from the outer part of the jugular foramen to lose itself upon the external surface of the skull, just above and behind the tip of the paracondyloid process.

It may be noted that the otic capsule, between its dorso-lateral connection with the squama and its ventro-medial connection with the planum basale, forms a bridge, uniting these structures, roofing the recessus supraalaris, and affording an upper delimitation for the foramen jugulare.

Dorsal to the capsulooccipital fissure the upper border of the squama proceeds backwards and inwards, and describes a curve with concavity upwards, to reach a small eminence, seen in the Hertwig and other models, which may be known as the *dorsal occipital prominence* (figs. 1 and 2). Beyond this it falls away to join with the upper border of its partner of the opposite side, this junction resulting in the formation of a dorsal concavity, directed upwards, which marks the upper edge of the tectum. Between the capsulooccipital fissure and the dorsal occipital prominence the squama is continuous cranially with the parietal plate. The line of union of the two lies at the bottom of a groove, seen from the inner aspect of the skull. It may be known as the *occipitoparietal groove* (fig. 1) and presents, on the right side two perforations, on the left one, through which small veins pass. The paired foramen (known as the *occipitoparietal fissure*, (figs. 3 and 5), is the larger, is elongated, and is situated about midway between the extremities of the groove. It perforates the groove at the most caudal part of its course. The smaller

foramen, which is limited to the right side, appears just in front of the larger. On the right side the terminal fourth of the upper border of the squama is separated from the slender dorsal tip of the parietal plate by a narrow slit. The parietal plate appears to end freely, but dorsal to this there are what appear to be degenerating cartilaginous cells, connecting the end of the parietal plate with the squama. This may indicate that these structures were united at an earlier time.

I regret that the dorsal extremity of the head of my embryo is missing, and that I am, on that account, unable to ascertain the condition in this region. On the right side the sections terminate in the dorsal occipital prominence, and show that the parietal plate has come to an end before this, as described. Owing to the fact, however, that the sections were cut obliquely, being deeper on the right side than on the left, I am unable to say whether or not the termination of the left parietal plate, and the relations which it bears to the squama, are the same as those found on the right side. I have, however, assumed that they are, and have so constructed my model; this having been done there was only the gap between the dorsal occipital prominences to be filled in, and this I did by reference to the Levi illustrations and Hertwig model. There are indications, on the left side, that the separation of the posterior extremity of the parietal plate will take place, as it has on the right, the cartilage connecting it to the squama, in the last few sections, being very thin.

In the membrane just lateral to the tip of the right parietal plate and dorsal occipital prominence there appears the weakly staining spicule of the interparietal bone. I have not represented it in the model, since only a small fragment is available, the remainder being included in the missing sections.

The sections go back sufficiently far to show that the occipital squamae unite dorsal to the tip of the superior occipital incisure, to form the tectum posterius, thus differing from the findings of Voit ('09) in lepus, who states that the squamae never reach the midline, the edges of the superior occipital incisure being the dorsal borders. I am, of course, unable to ascertain the exact width of the tectum.

The ventral part of the lower border has been described as the neural arch. Dorsal to this the character of the border changes completely, for, after the dorsal foraminal prominence is passed it loses its thickness and roundness on section, and becomes thin and serrated. This portion borders the superior occipital incisure, and really represents the lower portion of the original dorsal border, the upper portion being united to form the tectum posterius. The latter, according to Levi's investigations, is formed somewhere between the 14 and 17 mm. stages by dorsal fusion of the squamae.

The surface outlined by the above-described boundaries has been seen to become narrower ventrally in the lamina alaris (fig. 5). This is a wing-like plate of cartilage, bounded ventrally by the processus paracondyloideus. The outer edge of its upper surface bears the caudal extremity of the pars canalicularis of the otic capsule, and medial to this the upper surface, which looks principally cranially, participates ventrally in the structure of the hollow recessus jugularis, and forms the floor of the recessus supraalaris. The latter is a cleft between the lamina and the overhanging pars canalicularis of the otic capsule (fig. 5) through the lateral part of which the transverse sinus passes. The lower surface of the lamina alaris is also hollowed in the more central parts of the paraforaminal area (fig. 2, p. 372), and the plate is, therefore, quite thin—in fact on the right side it is perforated by a minute foramen, just lateral to the neural arch (fig. 1), and posterior to the jugular tubercle, through which a small vein passes. This foramen is doubtless the representative of the condylar foramen of the adult condition. Dorsally the lamina alaris becomes wider, thicker, and more vertical in slope, as it passes into the larger posterior portion of the squama. The inner surface is smooth, and presents, dorso-lateral to the tip of the superior occipital incisure a small oval foramen on the right side, but not on the left, through which a small vein passes (fig. 1). A very shallow groove runs parallel to the neural arch, just lateral to its upper aspect.

Upon the outer surface the most prominent object is a rounded eminence,—*the lateral occipital eminence*—(fig. 3) which appears

immediately dorsal to the otic capsule, and is separated therefrom by the cranial portion of the lateral capsulooccipital groove. Its posterior part projects slightly into the cranial cavity (fig. 5), and its edges are ill-defined, fading gradually into the surrounding cartilage. This marks the thickest part of the squama. It may be followed caudally as a low ridge on the outer surface, and is seen to meet, almost at a right angle, a second ridge, which extends from the tip of the paracondyloid process to the dorsal foraminal prominence, and to which the name *crescentic ridge* (figs. 2–3) may be given, the point of union being about the center of the latter.

The crescentic ridge, seen only on the outer surface of the skull, is a low elevation which sweeps dorsally and medially, between the extremities above mentioned, and in so doing describes a curve with convexity backwards and outwards. At its ventral end it is sharply defined, and is separated from the ear capsule by the small notch which stretches outward from the jugular foramen. Dorsally it is wider, and its margins are not so clearly outlined. It is of considerable thickness throughout, and is the lateral boundary of a semi-crescentic area—well seen in E. Fischer's ('03) illustration of the skull of macacus cynomolgus, and also in Voit's picture of the skull of lepus—which may be known as the *paraforaminal area* (fig. 2). It is bounded medially by the rounded edge of the neural arch, and ventrally by the caudal border of the paracondyloid process. Its hollowed central portion, which represents the lower surface of the lamina alaris, has been before referred to, and on the right side has been seen to be perforated by the minute condylar foramen. We find, therefore, that the thickest parts of the squama are situated immediately behind and below the ear capsule, and are represented by the lateral occipital eminence and the crescentic ridge, the former, just behind the capsulooccipital fissura, being slightly the thicker. The area dorsal to a line passing from the dorsal foraminal prominence to the occipitoparietal fissure is very thin, and presents a short distance behind this line evidence of commencing ossification. The cartilage appears to be undergoing greatest change in the region immediately dorso-lateral to the tip of the superior

occipital incisure, and dorsally the modified cartilage may be traced as far as my sections go. This area no doubt represents the center of ossification of the supraoccipital, which according to Mall ('06) ossifies from four centers, the first pair appearing in the region immediately dorsal to the foramen magnum on the 55th to 56th day, and being followed by other paired centers in the region ventral to this.

In all there have been noted in the occipital region five commencing centers of ossification, one, median, for the basilar portion; two, lateral for the condyloid portions, and two, lateral, for the squamous portions. In the vicinity of these centers the cartilage grades off into that surrounding them. Of the rest of the cartilage it may be noted that the material of the ventral border of the paracondyloid process, of the ventral part of the jugular tubercle, and of the body of the condyloid portion lateral to the hypoglossal canal shows a more advanced character than the remainder.

The atlantooccipital capsules are present; each is a sac composed of a dense sheet of perichondrium, covering the applied facets of the atlas and condyloid portion of the occipital cartilage. They are richly cellular, and above them the cartilage is of a younger type than that found in the remainder of the mass, but gradually grades off into the more mature type.

The primitive foramen magnum (figs. 1–2) is, at this stage, worthy of examination. It consists of three parts; a large central area, with which are continuous ventral and dorsal incisures. The central portion is bordered by the crescentic, rounded neural arch, and its plane looks upward and slightly forward. Ventrally is to be seen the intercondyloid incisure, its plane looking dorso-cranially, and this plane forms an angle with the main portion, which is open cranio-dorsally. This incisure remains a part of the foramen, later undergoing widening, and rounding out at the tip, as may be seen by examining the Hertwig model and the osseous skull. Behind the central portion, and appearing as a dorsal prolongation of it, is the superior occipital incisure, filled by the membrana atlanto-occipitalis dorsalis. The plane of this incisure is somewhat

steeper than that of the part in front, and thus it forms an angle, looking cranially and slightly ventrally, with that of the main area. This is shown upon the lateral contour of the skull as the point of an angle, directed downward and backward, marking the tip of the dorsal foraminal prominence (fig. 3).

The superior occipital incisure, though representing the dorsal part of the primitive foramen magnum, is by no means a part of the adult foramen magnum, as its edges unite later to complete the caudo-dorsal closure of the occipital region, the dorsal limit of the foramen magnum becoming set by the approximation of the dorsal foraminal prominences, as shown by the researches of Bolk ('04).

I find no evidences of the condition which Bolk describes at the posterior extremity of the foramen magnum, viz., a central cartilaginous mass (formed by the fusion of paired pre-existing masses) which lies between the upturned dorsal extremities of the occipital side-walls.

It seems clear from the work of various investigators, beginning with Froriep ('86), that although the occipital region of the mammals has been developed from the skeletogenous elements of four metameres, only the most caudal ever attains the status of a mature sclerotome, the three cranialmost being undifferentiated and playing but a minor part in the construction of the adult bone. This being true it follows that the story of the evolution of the occipital anlage is largely the story of the development of the caudal segment, or, as it will be hereafter called, the occipital scleromere or primitive occipital vertebra.

As in the spinal region, so in the occipital, the sclerogenous tissue passes through successive and overlapping membranous or blastemal, chondrogenous and osteogenous phases (Bardeen '05, '08), and in each phase the condition in the occiput recalls that of the corresponding phase in the vertebrae. Thus in the blastemal stage the occipital scleromere shows paired chordal processes joining across the midline in the region of the notochord, and paired neural processes embracing the neural canal as in the spinal scleromere; the costal processes are, apparently, poorly developed in the occipital scleromere. But along with this

marked similarity to the vertebrae the occipital scleromere shows certain individual peculiarities. Instead of uniting with the cranial portion of the segment immediately caudal to it, after the fashion of the other scleromeres, it retains its connection with the cranial portion of its own segment, and this, in turn, becomes united with the tissue of the three cranial, undifferentiated sclerotomes, the membranous anlage thus formed being known as the occipital plate (Bardeen '08 and '10). According to Froriep the occipital scleromere is marked off from the undifferentiated sclerotomes by the caudal root of the hypoglossal nerve.

The middlepiece of the occipital plate is made up in its caudal portion of the chordal processes of the occipital scleromere, and in its cranial part it also contains the elements of the body masses of the undifferentiated segments. So also while the lateral portions are mainly formed of the neural processes of the occipital scleromere they also contain, in the region cranial to the hypoglossal canal, remnants of the condensed lateral masses of the undifferentiated segments (Froriep, Levi).

In the chondrogenous stage of the occipital anlage of man, for the knowledge of which we are principally indebted to Levi, there are also striking resemblances to the vertebral conditions. The 13 mm. stage, studied by this author, shows the beginning of the transition from the membranous to the cartilaginous condition and in this paired masses of condensed chondrogenic mesenchyme, separated by the perichordal septum, were situated dorso-caudally in the middlepiece or basilar portion, and in the dorsal part of each mass, medial to the hypoglossal nerve, a small cartilaginous nodule occurred, recalling the paired chondrous centers of the body of a spinal vertebra. The mesenchymatous masses, representing the chordal processes of the occipital scleromere, were joined ventrally; they are the first portions of the occipital anlage, and indeed of the entire chondrocranium, to undergo chondrification, and eventually form the diverging, caudolateral portions of the pars basilaris bordering the foramen magnum. In the matter of priority in time of chondrification

of the body over the arch processes the occipital scleromere resembles those of the atlas and axis.

In the 14 mm. stage of Levi chondrous paired centers for the neural processes of the occipital vertebra arise, lateral to the hypoglossal nerve roots, and speedily unite by continuity of cartilage with the nodules just mentioned, which also join with one another in the same way, at first ventrally. The fused basilar centers are a little later joined by the chondrifying middle part of the undifferentiated sclerotomes to form the median part of the pars basilaris, and the chondrifying lateral masses of the undifferentiated sclerotomes join the neural processes. Thus the basilar portion, which may be taken to extend to the ventral margin of the hypoglossal canal is built up from the middle parts of all of the primitive occipital segments, the portion included in the anterior margin of the foramen magnum arising from the body mass of the occipital scleromere, and the cranioventral part coming from the body masses of the undifferentiated sclerotomes.

A lateral outgrowth from the neural arch is seen in a membranous condition in the 13 mm. stage of Levi, and is somewhat later in chondrifying than the neural arch of either the occipital vertebra or of the atlas. It represents, doubtless, the transverse process of the occipital vertebra, and is spoken of by Levi as the Querleiste. The costal process of the occipital vertebra has not been shown to have a separate center of chondrification.

It is to be noted that in the 13 mm. stage of Levi the bodies of the occipital vertebra, atlas and axis are represented by paired masses of chondrogenic mesenchyme, separated by the perichordal septum, and each mass contains a small nodule of cartilage (except in the case of the axis, where the two nodules have fused), their neural arch processes being entirely membranous. In the 14 mm. stage of Levi not only are the bodies chondrified but also the neural arches; for in the occipital vertebra a chondrous center appears just lateral to the hypoglossal foramen, and the arches of the atlas and axis also present each a small nodule of cartilage. Thus chondrification takes place simultaneously in cor-

responding parts of the occipital and first and second spinal vertebrae.

The paired cartilages of the body of the occipital scleromere of Levi's 14 mm. stage appear to be slow in joining dorsally, being found separated in this region by the perichordal septum, while their ventral parts are united. This is possibly to be explained as a result of expansion in this region, from intracranial pressure.

The above identification of the cartilaginous neural arch of the occipital vertebra and its appendage, the transverse process, as found in the early Levi models does not agree with this author's own interpretations of his findings. In his earliest human skull, from a 13 mm. embryo, Levi shows, lateral to the roots of the hypoglossal nerve, what he calls the lateral portions, from whose lateral surfaces the Querleisten project directly outward, and he figures the latter in all four of his stages. In the 14 mm. stage he finds in each lateral portion, just external to the hypoglossal nerve roots (Levi, text fig. 2) a cartilaginous center, which speedily joins with that for the body mass, which latter, as has already been noted, represents the chondrification of the body of the occipital scleromere. It seems evident that the center of chondrification in Levi's lateral portion is the center for the neural process of the occipital scleromere, with possibly the addition of the center for the undifferentiated portion, and hence it follows that the club-like membranous mass in which this nodule is found is the neural process of the occipital scleromere, which, with its partner, builds the lateral part of the neural canal of the occiput. Furthermore, these lateral portions are in direct alignment with the spreading arch-processes of the underlying cervical vertebrae, as is shown by the illustrations of Levi, and, though this author does not label them as the arches of the occipital vertebra, Bardeen, in his copy of Levi's illustration of his 13 mm. stage in Keibel and Mall's "Human Embryology" (vol. 1, p. 401) gives them what I regard as the correct designation, "Arcus vert. occip." Though the lateral portions of the occipital vertebra are here considerably larger than the arches of a cervical vertebra this extra size is probably

a local adaptation. Again, at the same time (14 mm. stage) according to Levi the arch mass of the undifferentiated sclerotomes has chondrified. It would, indeed, be surprising if the neural arch of the occipital vertebra were still membranous at a time when the arch processes of the undifferentiated sclerotomes were chondrified (those of the atlas and axis being also chondrified), as would be the case if Levi's interpretation were correct. My identification obviates this difficulty.

Accepting this interpretation it follows that the small processes or Querleisten which project laterally from the lateral processes cannot be the tips of the neural arches, as Levi describes them; they are really the anlagen of the transverse processes of the occipital vertebra. Levi, who does not account for the dorsal tips of the lateral portions of the occipital vertebra at all, is led to conclude that the Querleisten represent the tips of the neural arches, apparently, by the histological resemblance of their tissue, in the early stages, to that composing the tips of the neural arches of the underlying cervical vertebra. He remarks, however, that the Querleiste is very tardy in chondrifying when compared with the neural tip of the atlas, a detail which is, if anything, opposed to his identification of it as the tip of the neural arch of the occipital vertebra, but is what might be expected if it be homologized with a transverse process. The Querleisten are shown in the Levi models to be in direct alignment with the transverse processes of the cervical vertebrae, and they never come together dorsally and unite, after the fashion of the dorsal extremities of the neural arches. They are identical with what I have called in my model the paracondyloid process, following Voit, who described similar structures in the rabbit, and identified them as the representatives of the transverse processes, also remarking that the rectus capitis lateralis muscle, which each has attached to its lower surface, is to be regarded as the morphological equivalent of an intertransversarius muscle. Mead ('09), too, finds a similar and very strongly marked process in the skull of the pig, and calls it the paroccipital process. Both Levi and Voit state, correctly I believe, that the process ultimately becomes the jugular process of the occipital bone.

My identification of the primitive elements forming the pars basilaris also is not exactly in agreement with Levi's, but the difference depends largely on where the line between the basilar and lateral portions of the occipital anlage is drawn. I have assumed the separation between these portions to be approximately as it exists at birth, while Levi includes in his lateral portions the nodules which I believe represent the paired body of the occipital vertebra. If my interpretation of these structures is correct they should be regarded as constituents of the basilar portion, which would thus represent the body masses of the undifferentiated sclerotomes plus the body mass of the occipital vertebra, while according to Levi's view it would represent only the body masses of the undifferentiated vertebrae.

In the later development of the chondrogenous stage the forerunners of the individual features of the occipital bone begin to show themselves, and we find cartilaginous representatives of the body, pedicles, inferior and superior articular processes, transverse (and possibly costal) processes, laminae and spinous processes, these almost altogether differentiating from the occipital scleromere. The development of the body (pars basilaris) has already been discussed. The pedicles are, of course, represented by the cartilaginous tissue in the region of the hypoglossal foramen, but here we have material added from the lateral mass of the cranial sclerotomes, (Froriep, Levi), which results sometimes in the partitioning of the foramen, as may be seen on the left side of my model, and as has frequently been found by other observers in young embryos of homo and other mammals. The inferior articular process is, doubtless, represented by what has been designated the ventral foraminal prominence, the forerunner of the condyle, though the condyle of the mature bone is partly formed by the pars basilaris. The rudiment of the superior articular process is, perhaps, to be seen in the jugular tubercle. The transverse process, as we have seen, is to be found in the paracondyloid process, and there is some evidence to indicate that in this latter there may be included the costal process as well. It will be remembered that the paracondyloid process was perforated on the left side by

the paracondyloid foramen, and that on the right side the corresponding area of cartilage was thin, and, further, that the Hertwig model also presented this foramen on one side. It pierces the process from above downwards and forwards and is in series with the costo-transverse foramina of the cervical vertebrae below. If it be regarded as the costo-transverse foramen of the occipital vertebra, then the bar of cartilage which closes it in front must be looked upon as the costal process of this vertebra. I have not been able to find that the costal process of the occipital anlage has a separate center of chondrification as it has in the spinal vertebrae. Though there is no vessel or nerve passing through the paracondyloid foramen yet it is possible that this represents an old channel of the vertebral artery, which has become obsolete on account of the change of course of this vessel. In this regard the foramen may be analogous to the costo-transverse foramen of the 7th cervical vertebra, which no longer transmits the vertebral artery.

I regard as the representatives of the laminae the crescentic, tapering, hornlike masses of cartilage which form the lateral borders of the foramen magnum, and which I have spoken of as the neural arches. Since the squamous portions are continuous with the outer borders of these they may be considered as extensions of the laminae, and the tips of the latter (dorsal foraminal prominences) as the representatives of the spinous processes.

Not only on developmental, but also on histological grounds, does it appear evident that the margin of the foramen magnum is formed from the primitive neural arch of the occipital vertebra. Upon an examination of my slides it is seen that the cartilaginous tissue of this portion bears a strong resemblance to that composing the arches of the upper cervical vertebrae, and even more striking is the situation of the ossification center. It appears, as I have described, in the arch of the occipital vertebra, just dorsal to the root of the transverse process—exactly the same relative position as the ossification center in a cervical vertebral arch occupies. This point is beautifully brought out in the model of Hertwig, where, upon either side of the neural canal a

series of ossification centers presents itself, the uppermost member of the series being found in the exoccipital, in the position in which I have described it in my model, and being followed caudally by the ossification centers for the 1st, 2nd, 3rd and 4th cervical vertebrae; each center being uniformly situated with reference to its respective arch. In the basi-occipital, too, the single median ossification center recalls the center of a typical vertebral body, and indeed the osseous elements of the occipital bone at birth are strikingly similar to those of a vertebra, especially the fifth lumbar vertebra.

Keeping in mind the intimate and peculiar relationship which a typical vertebral arch bears to the cord which it encloses it seems reasonable to suppose that this relationship would be retained even after the vertebra had been taken up into the skull. It seems much more reasonable, even on purely theoretical grounds, to assume that the arch of the occipital vertebra goes to form the margin of the foramen magnum of the mature skull than to postulate that it forms the jugular process, as Levi maintains, and when it is realized that the latter is formed from the transverse process of the occipital vertebra, and that the margin of the foramen magnum is merely the modified arch of the occipital vertebra the proper relationship of the parts becomes intelligible.

Not only do the neural arches of the occipital vertebra exhibit a striking resemblance to those of the cervical vertebrae in each stage which has been studied, but their behavior in growth recalls very strongly that of the arches below. This parallelism in manner and time of development between the arch of the occipital vertebra and those of the cervical vertebrae is clearly shown by an examination of the 13 mm., 14 mm., 17 mm., and 28 mm. stages of Levi, my own 40 mm. stage, and the 80 mm. stage of Hertwig. The neural arches of the occipital vertebra, small at first, are seen to grow backwards and outwards, and then to come together medially and dorsally, thus hedging in the dorsal part of the foramen magnum, this process being duplicated coincidently by each of the upper cervical vertebral arches.

In each successive stage the tips of the neural arches, both occipital and cervical (which retain their original alignment), are seen to be farther advanced than in the last in their enclosure of the spinal cord, a condition strikingly brought out by a comparison of the foramen magnum and the underlying vertebral arches of my model with those of the oldest Levi model, on the one hand, and the Hertwig model on the other. In the 28 mm. Levi model the tips of the neural arches of the occipital and upper cervical vertebrae are separated by a considerable interval, in my model they are almost united, and in the Hertwig model, as has been noted, they are all completely joined; in the adult bone the tips of the occipital vertebra are represented by the internal and external occipital crests (representative of a spinous process). This closure of the foramen magnum takes place, accordingly, somewhere between the 40 and 80 mm. stages in man, and it bears a striking resemblance to that of the segments of the spinal canal. Growth seems to progress uniformly throughout the series, and dorsal closure is apparently completed at about the same time in each segment. Thus, with the fusion of the dorsal foraminal prominences there is completed what amounts to the closure of the cranial extremity of the spinal canal.

From what has been said regarding the formation of the foramen magnum it will be evident that what is found in the 40 mm. stage is something more than the foramen of the adult condition; it is this plus the superior occipital incisure. Further, the structure described as the tectum posterius is not the dorsal delimitation of the real foramen magnum at all, but merely that of the superior occipital incisure. The edges of the latter unite in the form of a median seam upon the union of the dorsal extremities of the neural arches of the occipital vertebra, and thus is effected the closure of the portion of the floor of the occipital region dorsal to the foramen magnum. This conception of the development of the foramen magnum explains why the primitive foramen is relatively so much larger than the adult condition.

In the condition of the occipital anlage at birth we find a basilar portion, formed in its cranial part from the body mass

of the undifferentiated sclerotomes and in its foraminal portion from the body mass of the occipital vertebra. The exoccipitals have been developed, as we have seen, principally from the neural arches of the occipital scleromere, but in the region of the foramen hypoglossi there has been added material from the lateral masses of the undifferentiated scleromere. The supraoccipitals, which ossify separately, are to be regarded as primarily connected with the neural arch of the occipital vertebra, and their separateness of ossification is analogous to the condition which we find in the 5th lumbar vertebra.

Regio otica

The otic region, like the occipital, is transversely somewhat ringlike in form, and its irregular sides, for the most part flattened from within outwards, are united by their caudal edges with the upper border of the occipital anlage, except where sundry foramina occasion interruptions. The otic ring, accordingly, heightens the dorsal part of the cartilaginous brain-case. In it we recognize four distinct elements, two unpaired, the otic portion of the lamina basalis and the tectum synoticum, and two paired, the otic capsule and the lamina parietalis. In addition to the parts entering into the composition of the ring there are also to be considered in the otic region the small, paired, isolated nodules known as the cartilagines supracochleares, cranii laterales and cranii posteriores.

When the skull is viewed from within (figs. 1 and 5) the upper or otic portion of the lamina basalis is seen to unite the ventromedian portions of the otic capsules. Passing laterally the eye meets the large, irregular mass of cartilage known as the otic capsule, which forms the ventro-lateral delimitation of the posterior cranial fossa, as well as part of the floor of the middle cranial fossa. Caudo-laterally the capsule is continuous with the lamina alaris, and dorsal to this with the wider portion of the squama of the occipital anlage, while cranio-dorsally the commissura capsuloparietalis (figs. 3 and 5) is seen uniting the larger dorsal portion of the otic capsule with the lamina parie-

talis the latter having also a union with the capsule below the capsuloparietal fissure. Dorsal to the capsuloparietal commissure the flattened parietal plate appears, and we note that it is wide ventrally, but becomes narrow dorso-medially. With the parietal bone it assists in the formation of the wall of the cranium in this region. Below, the parietal plate is continuous with the upper border of the squama; dorsally it is represented in the model as terminating freely just before reaching the dorsal occipital prominence, but there is microscopical evidence, as far as my sections go (as I have already stated) which seems to indicate that there was here a previous union of parietal plate and squama. Of the unpaired, dorso-median tectum synoticum, described by several authors, I can, unfortunately, make no statement, as my sections for this dorsalmost region are lacking. The otic ring, as I have represented it in the model, is therefore incomplete dorsally. This may possibly be its actual condition, and in this connection it may be noted that Mead states that the otic ring in Sus is incomplete dorsally.

The pars otica of the lamina basalis, which is the most cranial part of the chordal portion of the base of the skull, has already been described. The fissura basicochlearis is incomplete above, being represented by the lowermost part of what I have designated the spheno-cochlear notch—filled with connective tissue and a few small veins. The abducens nerve passes above the notch, lateral to and below the outwardly-projecting posterior clinoid processes, and in this the condition is similar to that described in such mammals as the rabbit (Voit) and pig (Mead), except that the basi-cochlear fissure in the latter types is closed above by a cartilaginous bridge joining the upper surface of the pars cochlearis with the lamina basalis, the abducens nerve passing over this bridge. In the model of Sus by Mead this nerve passes throught a foramen formed by cartilaginous connection of the posterior clinoid process with the cochlea. There is no evidence of this in my preparation.

The connections of the otic capsule with the planum basale, squama occipitalis and parietal plate have been noted. The model also shows it continuous ventro-laterally with the incus,

but histologically a sheet of perichondrium intervenes. There is no connection with the processus alaris of the temporal region through the commissura alicochlearis, such as Jacoby shows in the 30 mm. stage of homo and Voit figures in his model of the skull of lepus, but there is what I regard as a rudiment of this, viz., the cartilago. supracochlearis, (figs. 1 and 3) which will be later described. The otic capsule roofs over the recessus supra-alaris and recessus jugularis, and bridges the foramen jugulare (fig. 5).

In the otic capsule (figs. 6 and 7) we may distinguish a larger dorsolateral portion, which contains the semicircular canals, and which may therefore be known as the pars canalicularis (Voit), and a smaller, ventro-median portion, which contains the cochlear part of the membranous labyrinth, and which may therefore be termed the pars cochlearis. Voit has restricted the use of the term 'pars vestibularis' to the dorsal part of the pars cochlearis, which presents the fenestrae vestibuli and perilymphatica and the fenestrae for the vestibular division of the eighth cranial nerve. It contains the first, or unwound, portion of the ductus cochlearis. I shall adopt this usage of the term in this description.

The cartilage of the two portions is directly continuous, the zone of union being marked cranially by a notch, open above, which may be known as the *superior otic notch* (figs. 6 and 7), and ventro-laterally by a recess formed by the union of the lateral surface of the pars cochlearis with the ventral surface of the pars canalicularis; this may be known as the *ventro-lateral otic recess* (fig. 6). It contains the anlagen of the auditory ossicles.

The pars canalicularis is an irregular, somewhat flattened, ovoid mass of cartilage, hollowed for the passageways of the semicircular canals and utriculus. It presents for examination three surfaces, ventral, lateral and medial. Of these the lateral and medial are convex, and are approximated above and behind, their ventral edges being widely separated. The lateral surface (fig. 6) is smooth, and somewhat triangular in shape, being wider above than below. The cranial border is rounded, and is formed

by the out-bulging of the anterior semicircular canal; it is known as the prominentia semicircularis anterior. Ventrally this prominence terminates in the prominentia utriculo-ampullaris superior, a conspicuous rounded eminence at the cranio-ventral extremity of the pars canalicularis, marking the upper approximation point of its three surfaces. It is formed principally by the wall of the ampulla of the anterior semicircular canal (fig. 8). Springing upward from the dorsal part of the anterior semicircular prominence the capsuloparietal commissure may be seen, its connection with the otic capsule being shown in figures 6 and 7. Dorsal to this the border is marked by the capsuloparietal fissure (fig. 3), and caudal to this again by the lower union of the parietal plate with the otic capsule; under the latter union is to be noted the capsulooccipital fissure (fig. 7). The lowermost part of this border is formed by union with the squama. These borders separate the lateral from the medial surface of the capsule.

Both the capsuloparietal and capsulooccipital fissures appear in other models of the human skull (Levi, Hertwig), and they have also been shown to be present in the primitive skulls of other mammals, as the ape (Fischer) and rabbit (Voit). The capsuloparietal fissure is sometimes known as the foramen jugulare spurium, and the capsulooccipital fissure as the foramen petrosooccipitale.

The ventral border, which separates the lateral from the ventral surface, is, below the superior utriculoampullary prominence, marked off mainly by the conspicuous crista parotica, below this by the mastoid process, and below this again by the prominentia semicircularis posterior (fig. 6), which passes over the root of the mastoid process at this point.

The most prominent object upon the lateral surface is the *lateral otic eminence* (fig. 6), which lies in its dorso-cranial area, separated from the dorsal part of the anterior semicircular prominence by a very shallow groove. It slopes backward into the parietal plate between the two post-otic fissures, and is formed by the backward and outward projection of the massa angularis, a large mass of cartilage lying in the enclosure formed by the anterior and lateral semicircular canals, the crus com-

mune, and the upper part of the posterior canal (fig. 8). The two lateral otic eminences mark the extremities of the greatest transverse diameter of the primitive skull.

The dorsal extremity of the posterior semicircular prominence forms a gentle rise in the caudal area of the lateral surface, and then passes over the root of the mastoid process, as we have seen, to become prominent in its ventralmost portion, the prominentia utriculoampullaris inferior (figs. 6 and 7), which forms the conspicuous border between the ventral and medial surfaces and acts as the upper border of the lateral part of the jugular foramen.

The prominentia semicircularis lateralis is an indistinct swelling passing downward and backward from the crista parotica in the region of the incus to the dorsal extremity of the posterior semicircular prominence.

The medial surface (fig. 7) is more extensive than the lateral. Its cranial and dorsal borders are the same as those of the lateral surface; its ventral border is marked above by a rounded ridge passing downwards from the superior utriculoampullary prominence to the superior otic notch, and below by the posterior semicircular prominence, which, as has been seen, terminates ventro-medially in the inferior utriculoampullary prominence, the latter bearing a ventrally-projecting process, the processus interperilymphatica (Voit). The middle portion of the ventral boundary is formed by the transition of the medial surface of the pars canalicularis into that of the vestibular portion of the pars cochlearis. As has been mentioned the medial surface is convex, and presents in its central area as its most prominent object the prominentia cruris communis (Voit), formed by the crus commune within (fig. 9). Upon the dorsal part of this prominence is seen the long, almost horizontal, slit-like foramen endolymphaticum, for the outlet of the ductus endolymphaticus. Both lips of this foramen are formed of a young type of cartilage and it may be noted that the upper lip projects medially in its dorsal part to overhang the duct, and is continued dorsally past the foramen to form a groove, in which the duct lies (fig. 7). The dorsal extremity of this upper lip appears as a short, free process, overlying the duct.

The condition of the terminal portion of the ductus endolymphaticus is of interest. This does not end in a sac, but becomes a long, narrow fusiform dilation shortly after emerging from the foramen, and gradually decreases in size, to be prolonged, at its dorsal extremity, into a fine, lumenless filament or cord of cells. After leaving the foramen endolymphaticum it passes medial to the transverse sinus in the sub-dural space, outward and backward, and ends in the loose sub-dural connective tissue just medial to the occipitoparietal groove, about 1.8 cm. dorsal to the capsuloparietal fissure. It is not intimately associated with the cartilage of the ear capsule after its exit therefrom, and hence cannot retard the development of this locally to bring about a thinness of the wall, which is found in my preparation just dorsal to the endolymphatic foramen, in the area corresponding to that in which the small foramen which Voit describes in the developing otic capsule of the rabbit appears. This thin region of the wall (which is unperforated) is caused by encroachment upon it from within of the cavities surrounding the dorsal extremities of the anterior and posterior semicircular canals, and not by pressure of the saccus endolymphaticus from without, as Voit assumes in the skull of lepus.

The upper part of the medial surface is marked by the crescentic inner aspect of the anterior semicircular prominence (fig. 7), which is more distinct here than on the lateral surface, and sweeps backwards, from the superior utriculoampullary prominence to the dorsal end of the prominence of the crus commune. It corresponds to the arcuate eminence of the adult bone. Below this prominence is to be seen a distinct fossa, the fossa subarcuata anterior (Voit), delimited caudally by the prominence of the crus commune. This fossa invades the substance of the massa angularis, and upon examining the slides microscopically it is found that it is filled with a mass of loose connective tissue, covered by the dura.

The medial surface below the prominence of the crus commune looks downward, backward and inward in its upper portion, and almost directly downward in the lower. The latter is thin, composed of more darkly staining cartilage with thickset cells and little ground substance, and forms the roof of the supraalar

recess. In its ventral area may be seen the inferior utriculo-ampullary prominence, continuous dorso-laterally with the posterior semicircular prominence and ventrally with the short interperilymphatic process. A spur of the inferior utriculo-ampullary prominence caused by a localized thickening of the wall, projects backwards and upwards as a low ridge to disappear somewhat below the endolymphatic foramen. It overhangs the transverse sinus in this region. The fossa subarcuata posterior, which Voit mentions in his description of the skull of the rabbit, is not represented here.

The boundaries of the ventral surface (fig. 6) have already been described in connection with the discussion of the ventral boundaries of the lateral and medial surfaces. Its medial part is concerned with the junction of the pars canalicularis with the vestibular portion of the pars cochlearis. The lateral part of the ventral surface forms the dorsal wall of the ventro-lateral otic recess, which has been already referred to, and which contains the structures entering into the formation of the middle ear.

In the cranial area of the ventral surface there appears, projecting forward from the ventral surface of the superior utrioulampullary prominence, a distinct, almost vertical, ridge (figs. 5 and 6), which lies immediately medial to the body of the malleus, but is separated therefrom by a sheet of connective tissue. This represents the medial part of the cartilaginous tegmen tympani, or processus perioticus superior. The lateral portion of the tegmen, such as is shown in Voit's model of the skull of lepus, is not present, but its position is indicated by a low ridge, which arches downward and outward from the upper end of the medial portion of the tegmen and marks off the ventral from the lateral surface, terminating below in the crista parotica (fig. 6). The cartilage is not developing rapidly in this location, as in Voit's specimen. Upon examining the model of Hertwig it is found that the tegmen tympani has grown forward and outward to overlie partially the bodies of the malleus and incus, but the lateral portion has evidently made no further development, and so it may be concluded that the ossicles in man do not occupy a deep cartilaginous recess formed by the teg-

men tympani as they do in the rabbit. In the oldest rabbit skull examined by Voit the lateral portion of the tegmen had become quite a prominent plate, covering the ossicles, and reaching out toward the lateral wall of the middle cranial fossa. It appears evident that the tegmen tympani is rudimentary in man.

The crista parotica (figs. 2, 3 and 6) forms a conspicuous object upon the border between the ventral and lateral surfaces. It is narrower, as well as more prominent, below than above, and its edge shows younger cartilage than the adjacent regions. The cartilage of the incus, though in the model it appears to be attached, is really quite separate from that of the ear capsule, there being an intervening sheet of perichondrium.

The lowermost part of the ventral surface lies in a somewhat more posterior plane than the upper, and forms the dorsal wall of a small recess, open in front and below, bounded laterally by the crista parotica and medially by the interfenestral septum of the vestibular portion of the pars cochlearis (or promontorium). In the upper and medial part of this recess appears the lower portion of the fenestra vestibuli, while in the lateral portion, sheltered by the lower part of the crista, the facial nerve is to be found, this region becoming later the lower part of the facial canal or aqueduct of Fallopius. The proximal end of the cartilage of Reichert may be seen just medial to the lower extremity of the crista (fig. 2).

Just below the crista, and separated from it by a small notch, there appears, on the right side, a short, free, anteriorly projecting conical spur of cartilage, slightly younger in character than that of the adjacent otic capsule, and representing the mastoid process of the adult condition (fig. 6). Its substance is directly continuous with that of the ear capsule dorsally, but medially it is separated therefrom by perichondrium. On the left side the same formation is to be seen, except that a portion of the intervening sheet of perichondrium is, near the point of the process, replaced by cartilage. Immediately medial to each process is to be seen the origin of the stapedius muscle.

A brief word as to the course of the facial nerve may here be in place. After entering the internal acoustic meatus it traverses

the facial foramen in a direction outward and slightly forward and enters the ventro-lateral otic recess. Here it becomes associated with the geniculate ganglion from which the great superficial petrosal nerve may be followed forward. Leaving the geniculate ganglion the facial nerve now passes downward and slightly outward over the large cartilaginous bar which unites the pars cochlearis with the pars canalicularis and which is found between the facial foramen above and the vestibular fenestra below; thence it proceeds backward over the incudo-stapedial articulation. It now is to be found just medial to the crista parotica, and runs steeply downward, the relatively small stapedial muscle lying medial to it here. Passing lateral to the upturned end of the cartilage of Reichert, just between the latter and the lower tip of the crista parotica, it gives off the chorda tympani, and turns suddenly forward, following the line of the shaft of Reichert's cartilage, being situated slightly above and lateral to it, and almost immediately lateral to the auditory or Eustachian tube. The relations of the facial nerve at the proximal end of Reichert's cartilage are those shown in Low's ('09) plate, figure 3. The chorda follows its wellknown course through the middle ear anlage.

It is to be noted that the facial nerve does not go through a secondary facial foramen formed by the connection of the tegmen tympani ventrally with the cochlea, as is the case in the rabbit (Voit), and hence there is no true fovea genicularis in the skull of man in this stage, or, indeed, in any stage, judging from the evidence at hand.

The slightly younger condition of the cartilage along the ventral margin of the crista parotica would seem to indicate that the facial canal was closing here, but in the Hertwig model it is still open at this region.

The walls of the pars canalicularis are for the most part thin, and composed of mature cartilage. The largest mass of cartilage is formed by the massa angularis, mentioned above, the ventro-median side of which lies immediately lateral to the fossa subarcuata anterior, while the dorso-lateral side projects outward as the lateral otic eminence. Within the mass, just below the

floor of the anterior subarcuate fossa, there is a small isolated cavity, and as this is within the arch of the anterior semicircular canal I regard it as a remnant of a portion of the otocyst, which is, as yet, unclosed here. The ground substance of the cartilage of this mass is abundant and pale staining, the nuclei being relatively scattered, and surrounded by capsules not increased in size.

The remainder of the cartilage of the pars canalicularis is made up of masses filling the interstices between the canals and ampullae.

The pars cochlearis is the anterior and smaller part of the otic capsule, and lies immediately lateral to the upper end of the basal plate (figs. 1 and 2). Like the pars canalicularis it is of flattened, ovoid form, and contains the sacculus and ductus cochlearis. Upon it we may recognize two principal surfaces, medial and lateral, to which may be added a third or caudal surface, made up of the structures in the vestibular portion surrounding the foramen perilymphaticum.

The medial and lateral surfaces are separated by a rounded border, which runs from the perilymphatic foramen below, around the ventral part of the pars cochlearis, over the cranial pole, and thence backward to terminate by passing over the suprafacial commissure to become continuous with the pars canalicularis at the superior otic notch. The lowermost part of this border is deflected outward to form the promontory; within it is the first and uncoiled part of the cochlear duct, and it is known as the prominentia cochlearis inferior (Voit) (figs. 2, 6 and 7). This prominence passes at first inward, forward and upward, then almost directly upward to reach the cranial pole, and finally passes backward into the prominentia cochlearis superior (Voit) (figs. 1, 6 and 7) as the cranialmost border of the pars cochlearis, which roofs the coiled part of the cochlea (fig. 8), is called. Above the cranial pole the cartilago supracochlearis appears (fig. 3).

The lateral surface of the pars cochlearis (fig. 6) is smooth and gently convex in its ventral portion, and here presents a shallow groove, lying between the promontory and the cranial pole,

though it falls a little short of reaching either of these extremities (fig. 6). It is known as the sulcus caroticus (Voit) and contains a portion of the internal carotid artery (fig. 13). The sulcus caroticus does not correspond to the line of attachment of the lamina spiralis within, but crosses its cranio-ventral convex portion. Its lower part forms a low rounded projection into the lumen of the uncoiled portion of the cochlear duct, which appears in the figure of the cast of the cavity (fig. 8) as a shallow fossa.

The dorsal part of the lateral surface is made up principally by the outer wall of the vestibular portion, and forms the medial wall of the ventro-lateral otic recess. Above, the outlet of the facial foramen is to be seen, bridged by the suprafacial commissure. Below this opening is a small groove, the sulcus facialis (Voit), for the facial nerve, and below this, again, appears the elongated, crescentic, fenestra vestibuli, lying in a general direction from above downward and backward, and presenting a concavity downward and forward. It contains the anlage of the footplate of the stapes, which, however, fills only a small portion of the space of the fenestra, the remainder being occupied by the connective tissue representative of the annular ligament of the base of the stapes. Below the fenestra vestibuli is the cartilaginous septum which separates it from the fenestra perilymphatica below. This septum, which acts as a commissure to join the promontory of the pars cochlearis with the ventral surface of the pars canalicularis, has been referred to by Voit as the promontorium (fig. 6).

Passing below the lower, downwardly concave, border of the promontorium we come upon the small caudal surface of the vestibular portion (fig. 2), marked centrally by the large fenestra perilymphatica, which will later be separated by the processus interperilymphaticus into the larger lateral fenestra cochlearis or rotunda (over which is stretched the membranous anlage of the membrana tympani secondaria), and the smaller, medial foramen for the aquaeductus cochleae, within which may by seen the saccus perilymphaticus (Voit). The interperilymphatic process, more prominent on the left side than on the right, has been referred to, and appears as a short, conical

projection directed forward from the inferior utriculoampullary prominence. The cochlear fenestra is apparently closed off on the left side of the Hertwig model, and almost so on the right.

The perilymphatic fenestra (fig. 2) is sharply concave, from before backward, the direction of the concavity being downward. Its inner wall is formed by the lower edge of the *massa pyramidalis* of the median wall of the vestibular portion. When regarded from below the circumference of the perilymphatic fenestra appears to have been formed by the bifurcation of the inferior cochlear prominence at the promontory, the lateral limb forming the promontorium; the medial the lower border of the massa pyramidalis; the two limbs uniting dorsally in the inter-perilymphatic process.

The boundaries of the medial surface have already been noted (fig. 7). It is quite smooth, and is more flattened than the lateral. Ventrally the elongated, narrow, crescentic line of union with the basal plate may be seen; immediately ventral to and parallel with this, the everted, narrow, extra-cranial surface, formed by the medial aspect of the inferior cochlear prominence, makes up the outer wall of the ventral basicochlear groove (fig. 2) as a strip 1.5 mm. wide.

Dorsal to the basal lamina the medial surface is intracranial, the strip immediately bordering the lamina being concerned in the formation of the outer wall of the dorsal basicochlear groove (fig. 5), which is sharply marked throughout, but more so above than below, In the dorso-cranial area of the medial surface the large, deep, meatus acusticus internus appears (fig. 7); below, the surface passes into the caudal surface of the pars cochlearis and behind into the medial surface of the pars canalicularis.

If we now consider, briefly, the passageway of the ductus cochlearis (figs. 8 and 9) we find the first, or uncoiled part, outwardly deflected at and for a short distance beyond its entrance from the perilymphatic fenestra. The lateral wall is here quite thin, but the opposite medial wall presents a pronounced conical thickening, to which reference has been made as the massa pyramidalis (fig. 2). The apex of the pyramid projects laterally into the first portion

of the cochlear duct, and, indeed, it is owing to this circumstance that this part of the duct is thrust outward to form the promontory on the outer surface. From a point just ventro-cranial to the tip of this pyramid a small commissure, known as the *commissura laminopyramidalis* (fig. 8), springs to join the lamina spiralis which is immediately ventral, and this commissure passes over the uncoiled part of the cochlear duct; at the same time it divides the *crescentic fissure* in the floor of the internal acoustic meatus into ventral and cranial parts. The caudo-ventral surface of the pyramidal mass forms the medial wall of the first part of the cochlear duct; the cranio-ventral surface constitutes the medial and steepest part of the floor of the internal acoustic meatus, while the border between these delimits laterally the slit-like foramen, piercing the ventralmost part of the meatus, which transmits the cochlear division of the acoustic nerve. Dorsally the base of the pyramid is seen to be pierced from above downward and backward by the foramen singulare (fig. 9), which leads into the cavity of the ampulla of the posterior semicircular canal, the region of exit appearing as an indentation of the inner wall just medial to the inner edge of the fenestra perilymphatica. It appears in the cast of the cavity of the capsule as a projection (fig. 9). A small portion of the dorsal side of the pyramid is concerned in the formation of the ventral wall of the vestibular space; the remainder, together with its border joining the cranio-ventral surface, is directly continuous with the cartilage of the medial wall of the vestibular part of the pars cochlearis.

The ductus cochlearis, shortly after passing the level of the lamino-pyramidal commissure (fig. 8), emerges from the vestibular part of the pars cochlearis, and enters the ventral, completely enclosed pars cochlearis (sensu stricto) which contains its coiled part. The only entrances into the closed portion of the cochlea are the passageways for the cochlear duct and the cochlear root of the acoustic nerve. The medial wall is here quite thin, while the lateral wall presents the coiled lamina spiralis (fig. 5).

If the suprafacial commissure were removed (fig. 7) it would be seen that the superior cochlear prominence is continued downward and backward as the first and widest part of the spiral lamina, which here separates the upper coiled portion of the cochlear duct, in front, from the internal acoustic meatus behind. In front of the upper part of the ventro-medial edge of the lamina spiralis, at a point marked by the widened cranio-ventral extremity of the foramen for the cochlear root, the medial downward continuation of the superior cochlear prominence passes over upon the medial surface of the pars cochlearis. When the medial wall of the pars cochlearis is removed it is seen that the lamina spiralis is attached to the lateral wall of the pars cochlearis, the line of attachment being in the form of a helix, which makes but little more than one turn. If the lower edge of the internal acoustic meatus (figs. 5 and 7) be followed forward and inward it passes over the upper edge of the foramen for the cochlear root to reach the medial edge of the lamina spiralis; thence it may be followed along the edge of the narrowing lamina, whose curvature becomes progressively sharper, ending on the lateral wall in a downward turn. In this way there is formed a commodious recess for the upper coiled part of the cochlear duct and its surrounding space. In all the cochlear duct makes about two turns (fig. 8).

The internal acoustic meatus (figs. 5 and 7) presents a rounded border, although its edges are somewhat straightened below and behind. The dorsal portion of the upper border is sharp, and represents the medial edge of the foramen faciale. Passing caudally the edge becomes less sharply marked on the dorsal side, the cartilaginous surfaces which form it here meeting at a right angle. Ventrally we come upon the caudal edge, which is very sharp indeed, and represents the upper edge of the base of the massa pyramidalis. The dorsal and caudal edges form a rounded angle, and about 1 cm. below this point the entrance of the foramen singulare appears. Passing upward from the ventral end of the lower edge we come upon a crescentic and illdefined border which delimits the meatus cranio-ventrally,

and passes dorsally into the medial edge of the suprafacial commissure.

The floor of the meatus is composed of three distinct portions; the ventral, formed by the first part of the lamina spiralis, the dorsal, which is the ventral edge of the wall of the vestibular portion in this region, and the medial, formed by the cranio-ventral surface of the pyramid, as we have seen. These surfaces increase in steepness in the order mentioned, so that the crescentic fissure (fig. 7) formed by their approximated deep edges, is deeper caudo-ventrally than cranio-dorsally. Looked at from within the ventral and dorsal are the only surfaces visible, the ventral presenting much the greater area. The borders of the latter where they join with the margins of the meatus present the enlarged extremities of the crescentic fissure, the upper of which serves for the passage of the facial nerve, the lower and anterior for the upper part of the cochlear division of the acoustic nerve.

Five foramina appear in the internal acoustic meatus, and of these the foramen singulare has been considered. It transmits the posterior ampullary nerve to the inferior cribriform macula. The other four are parts of the crescentic fissure. This latter is divided into almost equal limbs by the lamino-pyramidal commissure, which has been noted overlying the first part of the cochlea, and joining the dorsal surface of the first part of the spiral lamina with the pyramid. The ventral limb is long and slit-like, widest in its ventro-cranial end, and transmits the fibres of the cochlear root of the acoustic nerve. It will later become the spiral foraminous tract. The cranial limb is separated by two cartilaginous septa into three foramina, the upper, which we have seen, being large, and transmitting the 7th cranial nerve, and being known as the facial foramen, the lower two being of about the same size, and transmitting the superior and inferior branches of the vestibular root of the acoustic nerve (figs. 5 and 7).

I have also reconstructed a model of the cavity of the otic capsule, and from the illustrations of this a conception of the general plan of the cavity may be gained (figs. 8 and 9). This

cast includes not only the membranous labyrinth but the space surrounding it, together with the entrances of the various foramina. In the illustration the laminopyramidal commissure appears as a foramen behind the coiled portion of the cochlear tract. In general form the cast resembles the later osseous labyrinth.

The cartilago supracochlearis (figs. 1, 3, 13) may now be considered. This is a small, rounded mass of cartilage, situated upon the cranial pole of the pars cochlearis, and, in the model, is about 8 mm. wide, and almost as long dorso-ventrally. It is quite free from cartilaginous union with the underlying cochlea, but the two are more closely approximated posteriorly than anteriorly, where the intervening connective tissue is thicker. The cartilage is immediately beneath the anterior part of the semilunar ganglion (fig. 13), and the material of which it is formed is mature cartilage of apparently the same age as that in the adjoining pars cochlearis.

It is difficult to say what may be the significance of this cartilage. Certainly it cannot be any one of the Restknorpeln which Voit describes in his Stage II (43 mm.) of the rabbit, since only one of these, Restknorpel b, corresponds at all in position with this cartilage, but it is distinctly above the semilunar ganglion while the supracochlear cartilage is below it. I am inclined to regard it as a rudiment of the commissura (or trabecula) alicochlearis, which Jacoby describes in his 30 mm. human embryo as a cartilaginous bridge extending between the anterior part of the pars cochlearis of the otic capsule and the ala temporalis. There is no evidence in my model of such a commissure, though the surfaces of the processus alaris of the temporal wing and the ventral surface of the pars cochlearis are very close together, and in the later stage modelled by Hertwig (80 mm.) there is no evidence of either commissure or rudimentary cartilage in this location, indicating that the cartilage in my embryo is probably undergoing retrogression. Voit describes and figures such a commissure in the skull of the rabbit, which encloses the carotid foramen laterally. He states it is a direct forward continuation of the planum supracochleare of the pars cochlearis.

The parietal plate (fig. 3) is a thin, semi-crescentic plate of cartilage, situated above and behind the pars canalicularis of the otic capsule, and bearing upon its median surface a concave impression for the brain (fig. 5). The ventral extremity is wide, and is surmounted by an irregularly formed and rudimentary portion, the upper border of which is overlaid laterally by the caudal edge of the parietal bone. Above this part, and lying in the membrane within the parietal bone is to be seen, on the right side, an elongated nodule of cartilage, which may be known as the *cartilago cranii lateralis* (fig. 3)—probably a remnant of the side wall in this region. On the left side there is a somewhat smaller nodule. That this portion is undergoing retrogression is evident from a comprison with the models of Levi, on the one hand, and with the model of Hertwig on the other, when it is seen that the 14 mm. stage of Levi marks, perhaps, the stage of greatest development of the parietal plate, there being, after this, a progressive reduction, moderate in the 28 mm. stage of Levi and in my model, and pronounced in that of Hertwig.

With the otic capsule the parietal plate is connected at two points—in front through the capsuloparietal commissure, and below this through the bridge of cartilage between the capsuloparietal and capsulooccipital fissures. The ventral edge is indented and presents no evidence of the spheno-parietal commissure, such as exists in certain of the lower mammals, as the rabbit and pig, and which represents, according to Gaupp (:00) the taenia marginalis of reptiles. The upper border is concave upward, and in its ventral portion there may be seen a small incisure, open behind, formed by an overhanging, backwardly projecting spicule from the uppermost part of the plate. This incisure appears to be the representative of what Mead calls the fissura laminae parietalis in the skull of Sus, where it is quite conspicuous. The upper border is continuous above with the membrane covering the brain.

The lower border is continuous ventrally with the otic capsule at the upper edge of the capsulooccipital fissure. Behind this it follows the elongated occipitoparietal groove (figs. 1 and 5) which runs backward to the dorsal occipital prominence, and

marks the zone of union with the squama. Several small blood-vessels are found in the ventral portion of the occipitoparietal groove, but in its dorsal part there is but a single small vessel. Just above the groove, and running parallel with it, is a low rounded ridge. The dorsal, scimitar-like extremity of the parietal plate is shown projecting freely dorso-medially. The outer surface is convex and is but indistinctly marked off from the underlying squama.

In the membrane forming the posterior and superior part of the cranium, considerably above the tectum posterius, are to be seen two small cartilages lying side by side, the cartilagines cranii posteriores. The cartilage on the right side, though small, is relatively very large when compared with its partner of the left, which is insignificant.

These cartilages appear to represent the unpaired mass described by Bolk as lying above the tectum synoticum, which subsequently disappears. Possibly in my embryo they are undergoing reduction. Mead describes a somewhat similar small free nodule in Sus, but this is single and, although in the midline, it lies immediately above the tectum. He calls it the processus ascendens of the tectum posterius, and thinks it may possibly be the homologue of the processus ascendens of the tectum posterius of reptiles.

Reprinted from THE AMERICAN JOURNAL OF ANATOMY, VOL. 16, NO. 4
September, 1914

II. THE SKULL OF A HUMAN FETUS OF 40 MM.[1]

CHARLES CLIFFORD MACKLIN
James H. Richardson Fellow in Anatomy, University of Toronto

Regio orbitotemporalis

The orbitotemporal region, in the present stage, is composed of the cartilage of the sphenoidal anlage and unites the otic region, behind, with the ethmoidal region in front. In it we recognize an unpaired, median portion, made up of that part of the central stem of the chondrocranium which contains the bend; this represents principally the cartilaginous body of the sphenoid, and is directly continuous dorsally with the otic portion of the planum basale and ventrally with the nasal septum of the ethmoidal region. In addition there are two paired, lateral parts, the forerunners of the greater and lesser wings. The internal pterygoid plate, which is laid down in membrane bone, will be considered in the section devoted to the discussion of the purely osseous elements.

If we examine, successively, the parts of the median portion, beginning dorsally, we note first a prominent transverse ridge, the crista transversa (fig. 5), which marks the boundary between the orbitotemporal and otic portions of the median stem. Directly continuous with this ridge, and springing upward from it, is the prominent dorsum sellae (figs. 1 and 3), here showing no median perforation, as it does in the rabbit (Voit), and it is owing to this circumstance that the upper edge of the crista is, in homo, entirely obliterated.

The dorsum sellae forms the conspicuous posterior wall of the hypophyseal fossa. Its upper and lateral corners are thickened

[1] Part I of this paper was published in the July number of the Journal, vol. 16, no. 3.

THE AMERICAN JOURNAL OF ANATOMY, VOL. 16, NO. 4
SEPTEMBER, 1914

and project upward, outward and forward in a horn-like manner, so that their ventral extremities overlie, to some extent, the hypophyseal fossa. These are the posterior clinoid processes. Their upper extremities rise higher than the cranial edge of the dorsum sellae between them, and hence the latter is concave cranially, as well as ventrally. The dorsal surface of the dorsum sellae is gently concave from side to side, and from above downward, passing uniformly over upon the surface of the otic portion of the planum basale below.

Histologically there is here, at this stage, no evidence of the primary separation of the chondrous anlagen of the dorsum sellae, such as Fawcett describes in earlier stages (19 and 21 mm.), except a slightly younger condition of the cartilage at the ventral side of the junction of the dorsum sellae and crista transversa.

In front of the dorsum sellae we come upon the wide, flattened floor of the hypophyseal fossa (fig. 1), or sella turcica, which opens laterally into the side-parts of the middle cranial fossa, and is thus more correctly a short wide groove than a fossa. Ventrally the wall rises abruptly,—almost vertically,—to reach a transverse ridge,—the anlage of the tuberculum sellae. The lateral edge of the ventral wall presents, on the right side, but not on the left, a small, conical backwardly projecting middle clinoid process. The tuberculum sellae of my model is much more prominent than it is in that of Hertwig. It is interesting to note in passing that Levi is of the opinion that in the development of the human skull the sella turcica is the only part to retain its primitive position, the other parts moving cranially, and he finds in the 28 mm. stage, among other evidences of this, the appearance of the tuberculum sellae as the anterior wall of the sella turcica. There is no evidence of the tuberculum sellae in the 17 mm. stage, while in the 28 mm. stage the sella has a vertical ventral wall, as in my model.

The part of the central stem of the chondrocranium composing the floor and ventral wall of the sella turcica has been termed the Balkenplatte or lamina trabeculi. It is wide, and, when compared with the parts in front and behind it, quite thin. It shows no evidence of perforation. From the ventral half of each

lateral edge of the floor there is seen to project, in a direction downward and outward, the short, rod-like processus alaris.

When the model is regarded from the side (fig. 3), the floor of the sella turcica, which is slightly concave cranially, appears as the upper expanded end of the planum basale, the ventral wall of the sella appearing as a continuation upward of the ventral surface of the planum; indeed if the ventral border of the latter (which we have noted is almost straight) is projected upward it will pass just ventral to, and parallel with, the ventral wall aforementioned. From the same position, too, the ventral wall of the sella appears as the dorsal expanded end of the cranio-ventral or horizontal limb of the central stem of the chondrocranium, and the appearance is as if the caudo-dorsal edge of this had been applied to the cranio-ventral edge of the vertical limb, making an angle of 115°, open caudo-ventrally, the flattened extremities forming the ventral wall and floor of the sella turcica respectively. Ventrally (fig. 2) this angle is seen to be quite sharply marked, and to lie on the line between the ventral edges of the roots of the processus alares, or, just below the level of the ventral wall of the sella. Ventral to this angle the cartilage of the central stem gradually becomes narrower from side to side, and expanded caudo-cranially, passing ventrally into the nasal septum (fig. 10).

If we now turn our attention again to the upper surface of the median stem, we pass forward from the sella turcica, over the rounded, transverse, tuberculum sellae, and come upon the flattened lamina hypochiasmatica (fig. 1) (sulcus chiasmaticus of Levi), triangular in shape, with the apex placed ventrally in the midline, and the base formed by the upper edge of the ventral wall of the sella turcica. This surface underlies the optic chiasma, and is horizontal, thus making almost a right angle with the ventral wall of the sella. Ventrally the apex rises upon the dorsal edge of the interorbital septum, forming therewith an angle of 120°. Immediately lateral to this junction is a small, slit-like foramen, which may be known as the *foramen praechiasmaticum* (figs. 1, 10 and 14); it has been shown in the models of the skulls of several mammals, as the ape (Fischer) and the rabbit (Voit),

as well as man (Hertwig). It contains nothing but loose connective tissue. It does not appear in Jacoby's figure, but the optic foramen extends all the way to the interorbital septum, and one may assume from this that the small isthmus of cartilage, which cuts off this small aperture from the optic foramen, and which may be known as the *commissura praechiasmatica* (figs. 1, 10, 14), has been developed between the 30 and 40 mm. stages. In my sections this commissure shows a rather younger condition of cartilage than that found in the surrounding chondrocranium. The foramen praechiasmaticum evidently disappears later, as it is not to be found in the osseous condition. At the dorsal extremity of the optic foramen the lamina hypochiasmatica is seen to pass over upon the dorsal root of the ala orbitalis.

A feature which I have not noticed in the description of human primitive skulls, but which is described by Voit in the skull of lepus, as the ala hypochiasmatica, is a small but strong crescentic ridge which projects antero-laterally from the surface of the lamina hypochiasmatica just ventral to the origin of the dorsal root of the ala orbitalis, and which is continuous dorsally with this root. It appears in figure 10 and may be seen from above as a projection into the optic foramen (fig. 1). It presents a convex ventral edge, and is separated from the surface of the interorbital septum, lying within, by a distinct furrow containing only connective tissue. In the Voit model of the skull of rabbit this shows beginning ossification, but such is not the case in my model, in which the ala presents a somewhat younger type of cartilage, especially in the ventral edge, when compared with that of the adjacent cartilage.

Ventrally, as we have seen, the lamina hypochiasmatica is continuous, medially, with the dorsal border of the interorbital septum. From the sides of this septum the ventral roots of the alae orbitales are seen to spring (fig. 1), and its cranialmost edge, delimiting the orbitonasal fissure medially, passes over directly upon the nasal septum.

The interorbital septum (figs. 10, 11, 14 and 15) is narrow cranially, being delimited dorsally by the roots of the alae orbi-

tales and ventrally by the dorsal extremities of the side-walls of the ethmoidal region (fig. 11). It is thicker below than above, its lower surface being keel-like, and passing horizontally forward upon the lower edge of the nasal septum; the upper part becoming increasingly thinner as we follow it ventrally, to coalesce with the upper portion of the same structure. It represents a transition from the flattened Balkenplatte to the thin nasal septum, in which the median stem appears to undergo a torsion of 90°, and forms the median delimitation of the narrow inner recess of the orbit.

The interorbital septum of man is homologous with the structure bearing the same name found in the Saurians, but, as is the case in the other mammals, it is rudimentary when compared with these lower forms. A theory which seeks to account for the shortness of this septum when compared with the condition in the lower forms is that, in the mammals, the nasal side-wall has gradually grown backwards, to encroach more and more upon the territory of the interorbital septum, to the advantage of the nasal septum (Mead).

If we start at the floor of the sella turcica (fig. 1), and proceed upward and forward we come upon three successive steps, at about equal intervals apart, formed, as we have seen, by the lamina hypochiasmatica, the uppermost edge of the interorbital septum, and finally, in the most cranial, which reaches the highest point of the chondrocranium, by the crista galli of the mesethmoid (fig. 11).

The orbital wings (figs. 1 and 10) are the cranio-ventral and the larger of the paired lateral extensions of the sphenoidal anlage. Each wing has the form of an imperfectly defined, triangular plate, with the irregular base parallel with the median plane, and the apex lateral and turned dorsally. The plate is gently concave downward, forming the roof of the orbit; above it takes part in the formation of the floor of the anterior cranial fossa. Of the unions, two are with the central stem of the chondrocranium, the dorsal and ventral roots, and one which is elongated and broken by several foramina is with the side-wall of the ethmoidal region. The two wings lie almost hori-

zontally, and thus differ from the earlier conditions, where they are considerably higher laterally than medially (Jacoby).

The dorsal root is the smaller, and is directed outward and slightly upward. Thick and rounded in section, its cartilage is directly continuous with that of the lamina hypochiasmatica, from the side of which it has been seen to project. A short distance from its origin it widens out, and at the same time rises cranially to form a plate, flattened from above downward, outward and slightly forward, the dorsal edge of which presents, near the median line, a backward projection, the anterior clinoid process (fig. 3). Between this process and the edge of the Balkenplatte, rendered more sharply defined on the right side by the middle clinoid process, there is to be seen a distinct notch, which lies dorsal to the root, opposite the most posterior extremity of the optic foramen, and conveys the internal carotid artery. The dorsal border of the wing, after leaving the anterior clinoid process, passes upward, forward and outward, making a dorso-lateral convexity, and finally turns abruptly backward upon the dorso-lateral process. The ventral border of the root forms the dorsal and part of the lateral border of the foramen opticum, while its lower surface, together with that of the wing lateral to it, forms the cranial delimitation of the superior orbital fissure.

The ventral root is wide and flat, and is directed outward and slightly backward. It is considerably the longer, as well as the broader, and is directly attached to the dorsal border of the interorbital septum along the line indicated in figure 11. In addition it is connected, through the praechiasmatic commissure, with the ventro-lateral edge of the hypochiasmatic lamina (fig. 1). The ventral root occupies a somewhat higher level than the dorsal. The dorsal border curves outward and backward, to assist in the delimitation of the foramen opticum; the ventral border passes almost directly outward, and forms the dorsal border of the orbitonasal fissure. Through the portion of the wing lying lateral to the optic foramen it is continuous with the dorsal root; and in this way is formed the shelving side of a recess, the floor of which is made up of the hypochiasmatic

lamina, in which is found, among other structures, the optic chiasma.

The optic foramen is pear-shaped in outline, with the narrow end ventro-medial. The lateral border is somewhat higher than the medial, and is downwardly and inwardly concave. The optic nerve and ophthalmic artery may be seen to pass through it, the former overlying the latter.

The ventralmost portion of the orbital wing has been known by the name of cartilago sphenoethmoidalis. This is a triangular plate of cartilage, somewhat thinner than that composing the remainder of the wing, and showing ventrally a connection with the superior prominence of the lateral nasal cartilage through the sphenoethmoidal commissure (fig. 1), and dorsal to this connections at several points with the lateral nasal cartilage as far back as the orbitonasal fissure, the bonds of attachment being broken by intervening foramina. Thus there is formed here a secondary, lateral cribriform plate, similar to that shown in the model of Hertwig, which leads from the anterior cranial fossa, not into the nasal capsule, but into the orbit. The dorsal margin is irregular and forms the outer half of the ventral margin of the orbitonasal fissure, the medial half being formed by the dorsal surface of the ectethmoid.

The ventral border of the orbitonasal fissure is somewhat lower than the dorsal. The fissure is elongated, its long dimension being directed laterally, and in this it differs from the condition shown in the skull of lepus (Voit), where it is directed ventro-laterally. In the latter animal, too, there are no connections with the ectethmoid dorsal to the sphenoethmoidal commissure. As in the skull of lepus (Voit) so in man, the fissure is principally filled with connective tissue, but in its ventral region it transmits the anterior ethmoidal nerve and vessels from the orbit to the anterior cranial fossa. It is thus, in this region, representative of the anterior ethmoidal foramen of the adult skull.

The lateral border of the ala orbitalis is serrated, and passes directly backward and outward to terminate in the hornlike, dorso-lateral process (fig. 1). It overlies, except at its tip, the

median edge of the orbital plate of the frontal bone (fig. 2). The dorso-lateral process marks the lateral extremity of the ala, and also represents the ventral rudiment of the primitive taenia marginalis of this region, which in the lower forms stretches over the foramen sphenoparietale to make a connection with the parietal plate, as has been already noted.

The ala temporalis (fig. 10) is the smaller of the paired lateral appendages of the median portion of the sphenoidal anlage. It lies lateral to the Balkenplatte, and, for the most part, in front of and below the level of the floor of the sella turcica (fig. 3). As H. Fuchs remarks one must distinguish in the temporal wing of mammals two portions; a medial, sloping steeply downward and outward, and a lateral, ascending part. The medial portion, or processus alaris, is a short, straight, rodlike mass of cartilage, directly continuous with the outer edge of the Balkenplatte, from which, as we have seen, it projects downward, outward and slightly backward. Its dorsal surface comes into close contact with the cranio-ventral pole of the pars cochlearis, but is not connected therewith by a cartilaginous bridge (commissura alicochlearis), as is the case in the Jacoby model, and in the models of several of the lower mammals. What I regard as a remnant of this bridge is, however, to be found in the supracochlear cartilage, which has already been described. Levi was unable to find any trace of this commissure in his specimens.

It may be noted in passing that Jacoby states that this bridge extends from the lateral edge of the sella turcica to the anterior edge of the ear capsule, but he has evidently included in the median portion of this the structure which other authors refer to as the processus alaris. Jacoby states that the ala temporalis springs outward from this bridge; perhaps a better way of stating it would be to say that the ala temporalis, through the processus alaris, springs from the edge of the floor of the hypophyseal fossa, and that the bridge, or commissura alicochlearis, connects the ala with the anterior surface of the pars cochlearis of the otic capsule. By the disappearance of the commissura alicochlearis the carotid foramen is left open laterally. It is quite small, being delimited ventrally by a small notch between

the root of the alar process and the Balkenplatte, and dorsally by the ventral basicochlear groove, which passes backward into the sphenocochlear notch.

The ventral surface of the alar process is almost completely taken up with the attachment of the lateral portion of the wing. The rounded outer extremity projects freely into the surrounding mesenchyme (fig. 1).

The larger lateral portion of the temporal wing lies immediately below the dorsal portion of the orbital wing, from which it is separated by the superior orbital fissure, now open laterally (fig. 4). It is rhomboidal in shape, the long axis being directed upward, outward and slightly forward, towards the lateral extremity of the ala orbitalis. The central portion of its mass is perforated, from before backward, by the large foramen rotundum, which transmits the second branch of the trigeminal nerve. The nerve, however, by no means fills the foramen, the greater portion of the space within it being occupied by connective tissue. The foramen rotundum is found in Levi's 28 mm. stage, but not in Jacoby's 30 mm. stage, the second branch of the fifth nerve here occupying a groove upon the upper surface of the wing. It is well shown in the illustrations of Fischer's ('03) ape skulls.

Immediately below the foramen rotundum the dorsal surface is concerned in the union with the ventral surface of the alar process, the long axes of the medial and lateral portions crossing at a right angle, open above. When regarded from above the effect is as if the caudo-medial corner of the lateral portion had been applied to the ventral surface of the medial portion in such a way as to leave the lower extremities of both free. The foramen ovale is not as yet formed.

Histologically there is to be seen at the junction of the alar process and lateral portion a sheet of younger cartilage and procartilage cells, which almost completely separates the two portions. This is evidently the last trace of the primitive separation of these parts, of which Levi, Fawcett and other authors speak. In the 14 mm. stage Levi finds the temporal wing represented by two procartilaginous anlagen, separated by a sheet of connective tissue.

The portion of the wing above the foramen rotundum is known as the lamina ascendens, and ends laterally in a somewhat sharp angle, which projects freely outward and forward. The uppermost angle, rather more blunt, is to be seen almost immediately under the lateral edge of the optic foramen. The dorsal surface of the lamina ascendens is convex, and terminates dorsally in a ridge, bordering the foramen rotundum laterally.

The lowest portion of the wing is marked by a blunt angle, lying below and a little medial to the foramen rotundum, and representing the processus pterygoideus. The innermost extremity of the wing presents a more sharply marked angle, which projects freely inward, where it comes into close contact with the parasphenoid bone, or internal pterygoid plate, the upper extremity of which lies immediately ventro-medial to it. Medially and caudally this angle is separated from the alar process by a well-marked groove,—the deepest part of the circular groove which surrounds the union of the alar process and the lateral portion.

The outer margin of the lateral portion projects farther forward than the medial (fig. 14) so that its ventral face looks inward as well as forward. There is no trace of a lamina pterygoidea, perforated by the internal maxillary artery, such as Voit describes in the skull of the rabbit.

Histologically, modification of the cartilage cells in the upper lateral portion of the wing indicates beginning endochondral ossification; Mall found the first trace of the alisphenoid bone in an embryo of 58 days. Medial to the foramen rotundum the cartilage is thinner and of younger character than that elsewhere in the lateral portion, indicating that this was the part which was, perhaps, latest to form.

Gaupp has pointed out that the brain-case of the mammals has, in the orbitotemporal region, been enlarged by the inclusion of a space which, in the lizards, lies below the primitive side-wall of this region, and to which he has given the name 'cavum epiptericum.' This space is the ventral continuation of the cavity which has been described by Voit in lepus as the cavum supracochleare. Voit has found in an early rabbit embryo

evidences of the medial attachment of the primitive side-wall of the orbitotemporal region in the form of three rudimentary cartilages, and membrane connecting them, and stretching out from them. From behind forward he finds, first, Restknorpel *a*, surmounting the commissura suprafacialis (continuous with this on one side but not on the other), next Restknorpel *b*, overlying the semilunar ganglion, and connected by a sheet of connective tissue, which overlies the abducens nerve, with the pillar of the dorsum sellae. Restknorpel *b* is quite free. A third rudimentary cartilage, Restknorpel *c*, appears only on the left side of Voit's youngest rabbit skull, and this fact appears to point to its transient nature. It presents itself at about the site apparently of the middle clinoid process, and is attached directly to the side of the Balkenplatte. Between Restknorpeln *b* and *c* the boundary between the primitive cranial cavity and the cavum epiptericum is not clearly marked. From these three Restknorpeln, and from the cartilage intervening, anchorage is afforded for a stout sheet of connective tissue which stretches outward and upward to find its cranial attachment in the lower edge of the taenia marginalis, or, as Voit calls it in this region, the commissura orbitoparietalis. Underlying this membrane, which Voit thinks is, to some extent, the precursor of the dura mater of this region, are several important structures which are primarily outside of the primitive brain case, as in the lizards, but are later taken into the brain case of the mammals; among these have already been mentioned the semilunar ganglion and part of its nerve trunks, part of the facial nerve, the geniculate ganglion and part of the great superficial petrosal nerve. In addition might be mentioned the nerves to the eye muscles, and the internal carotid artery—indeed all the structures in the cavernous sinus. The carotid artery is shown in the youngest stage of Voit winding around the caudo-ventral surface of Restknorpel *c* to enter the primitive cranium, this point marking its original inlet.

From the researches of Voit it would appear that the new floor and side-wall of the cavum epiptericum and the cavum supracochleare are formed by the upper part of the ala temporalis,

the tegmen tympani and its forward extension, and the commissura alicochlearis, together with the osseous elements formed by the parietal, and squamous portion of the temporal, bones. These completely shut off this space, except for the foramina.

In my embryo there do not appear to be any of the nodules corresponding to the three Restknorpeln of Voit. The space corresponding to the above cavities is filled with loose connective tissue containing vessels and nerves. The dura has not condensed, is loose, and spreads outward and upward from the level of the upper part of the pituitary body. Thus the primitive cranial floor and side-wall of this region is not represented in my model. There is, however, what may be a rudiment of the cartilaginous secondary cranial floor—the floor of the cavum epiptericum, viz., the small nodule which I have called the cartilago supracochleare. Voit considers the alicochlearis a part of this floor, which dorsally is directly continuous with the planum supracochleare; this being so it follows that, if the cartilago supracochleare be regarded as a rudiment of the commissura alicochlearis it is then a rudiment of the cartilaginous floor of the cavum epiptericum, or, more accurately, the cavum supracochleare.

Regio ethmoidalis

The ethmoidal region is the most ventral of the primary divisions of the chondrocranium. With the orbitotemporal region it is directly continuous at three points, as we have seen; medially the septum nasi passes directly backward into the septum interorbitale, and laterally the upper portion of the lateral wall of the ectethmoid is united, on each side, with the sphenoethmoidal cartilage through the sphenoethmoidal commissure and the line of bridges of cartilage dorsal to the latter.

Architecturally considered the principal elements entering into the construction of the ethmoidal region are those going to form the nasal capsule, but this region also includes certain accessory cartilages, of which there are, in relation to the septum the anterior and superior paraseptals; in relation to the lateral wall (intracapsular) the cartilago meatus medii, and (extracapsular) the paraethmoidal and paranasal cartilages.

The nasal capsule resembles, roughly, a tent, partitioned into equal, paired, lateral rooms or cavities by the septum, or mesethmoid, which lies in the median sagittal plane of the skull. The highest point, or peak, is marked by the crista galli. The roof and sides are formed by the tectum nasi and paries nasi respectively, the posterior or subcerebral portion of the former being broken by the long, paired, irregularly-contoured fenestrae cribrosae (fig. 1), destined to become the cribriform plate. This portion of the superior surface of the capsule takes part in the formation of the median part of the anterior cranial fossa, and represents the anlage of the upper surface of the ethmoid bone.

The incomplete floor (fig. 2), or solum nasi, is formed laterally by the inwardly-turned lower edges of the side-walls, and medially by the lower border of the septum and the anterior paraseptal cartilages. Between the side-wall and the septum is the gaping and elongated basal fissure, which extends ventrally into the incisura narina and dorsally into the *cupuloseptal fissure*, the latter being a very narrow space between the dorsalmost extremities of the nasal septum and the nasal wall, almost completely filled by perichondrium. The floor is almost entirely covered in by membrane bones—the maxilla, the palatine and the vomer—these closing off the inferior nasal meatus below, and marking the upper delimitation of the oral region. The three elements, tectum, paries and solum nasi, combine to form the shell-like structure known as the ectethmoid. Laterally the dorsal portion of this is in relation to the orbit.

The nasal septum or mesethmoid (fig. 11) is a vertical and roughly pentagonal plate of cartilage, constituting the ventral end of the central stem of the chondrocranium. The dorsal border is marked above by the interrupted line of attachment of the dorsal surface of the tectum nasi, which separates the surface of the nasal from that of the interorbital septum; below this these surfaces have no definite delimitations. The cranio-dorsal border, after passing over from that of the interorbital septum, runs horizontally forward for a short distance, and then mounts rapidly and evenly to reach the highest point of the chondrocranium in the conspicuous crista galli. The latter marks the

widest part of the septum. The outer edges of this border, except in the upper portion of the crista galli, show short lateral eminences, which project into the fenestra cribrosa. These projections will later coalesce with others from the upper edge of the side-wall, and thus form the dorsal portion of the cribriform plate. In front the crista galli passes over upon the cranio-ventral border, which is straight, and sharply inclined downward, while laterally it is directly continuous throughout with the ventral portion of the tectum nasi. By reason of the fact that the tectum rises somewhat, as it springs from the septum, the upper border of the latter lies here at the bottom of a shallow furrow, the sulcus supraseptalis (fig. 1), which reaches from the crista to the ventral tip of the capsule.

The ventral border of the septum is straight and free, and marks the anterior extremity of the mesethmoid, forming the medial limit of the incisura narina, the representative of the fenestra narina of some of the lower forms. At its lower end it meets the caudal border at an angle of 113°. The caudal border is almost straight, horizontal, and thickened throughout, but much more so dorsally than ventrally, so that it resembles a cone, this similarity being rendered more striking by the fact that the transition to the thin part of the septum above is quite abrupt, thus resulting in the formation, on each side, of a shallow furrow (figs. 14 to 18). Near the ventral extremity the caudal border shows on the right side, but not on the left, a lateral connection with the cartilages of Jacobson (fig. 11), and, in front of this, bilateral unions with the ventro-lateral processes (Fawcett '11), the latter appearing immediately behind the front end. Projecting backward from the posterior of these attachments, lying parallel with and below the caudal border, in a position corresponding to about the middle of its ventral half, may be seen the cartilages of Jacobson, or the anterior paraseptal cartilages (figs. 2 and 18). Behind these the dorsal portion of the border, in its caudo-lateral aspect, is covered by the thin plates of the vomer (fig. 2).

The surfaces of the septum are for the most part smooth, but in the region below the crista galli there is a deflection to the left;

on the right side this appears as a well-marked furrow, running from above downward and forward (fig. 11). In the area just above the anterior paraseptal cartilage the furrow lying above the lower, thickened border is somewhat deepened, and in this hollow is to be found the anlage of the organ of Jacobson (figs. 11 and 18).

An interesting feature of the mesethmoid is found about the middle of its dorsal half (the part corresponding to the future lamina perpendicularis of the ethmoid bone), in the form of two paired, elongated cartilages, very small in size, which lie parallel with, and close to, the surface. These may be termed the *superior paraseptal cartilages* (figs. 11 and 16), and though mature, their cartilage is younger in type than that composing the adjacent septum. The cartilage on the right is somewhat the longer, measuring 13 mm., the left being 11 mm., and in direction the right is parallel with the caudal border of the septum, while the left runs slightly upward, as well as backward. The nasal septum, opposite the anterior part of each cartilage, and for a short distance in front of it, shows a slight swelling, and the anterior part of the paraseptal cartilage lies just lateral to and somewhat below this. So closely does the paraseptal cartilage lie to the nasal septum that it is difficult to make out a separation, but by the aid of the high power and close examination it is seen that the cartilage is separate from the septum, except at two points on the right side, and one on the left. On the right side the connection points are at the anterior extremity, and about the middle, while on the left the sole union is at the anterior end. Thus each cartilage presents a free, posteriorly projecting extremity. From the caudal edges of each cartilage there stretches downward a sheet of young connective tissue. Figure 16 shows the relationships of the superior paraseptal cartilage to this sheet, and it will be seen that, where the cartilage is free from union with the septum, as it is on each side in this figure, the relationship of the cartilage to the membrane is somewhat similar to that of a sesamoid bone to its tendon, for the real upper connection of the membrane appears to be somewhat above the cartilages, where it becomes continuous with the perichondrium

of the septum, as shown in this figure. The two sheets unite below the septum, and in this region, which marks their thickest part, they contain the slender spicules of membrane bone which represent the vomer. Though they are found throughout the extent of the vomer they disappear shortly beyond its extremities.

Fawcett ('11) in his description of the paraseptal cartilages finds a similar sheet of condensed mesenchyme, and gives to it the name "suspensory membrane," stating that it envelops the anterior and posterior paraseptal cartilages, and extends between them; further that in the interval between these cartilages the vomer is developed (following Zuckerkandl '08). I am unable to discover in my model any trace of this "suspensory membrane" in front of the ventral extremity of the vomer, so that it has, obviously, nothing to do in this stage with the support of the anterior paraseptal cartilages; moreover it is not found behind the dorsal extremity of the vomer, and hence cannot function in the suspension of the processus cupularis posterior (posterior paraseptal cartilage of Fawcett) which evidently represents the last rudiment of the posterior transverse lamina of such forms as the rabbit (Voit). Furthermore, since the cellular composition of this membrane is apparently the same as that which forms the membranous anlage of any of the membrane bones, and its situation is that which will be occupied by the future upward-growing vomer, and since the vomer is to be found within its thickened caudal portion, it would appear that it is simply the membranous anlage of the vomer. The term 'suspensory' would seem to be misapplied, since the bony elements enclosed by it cannot be said to be suspended, any more than the early osseous spicules of any other membrane bone may be said to be suspended in their membranous anlagen, and the cartilaginous elements are not enclosed by it; indeed the so-called posterior paraseptal cartilages, as Fawcett himself states, are continuous with the lateral walls of the nasal capsule (fig. 14). Fawcett evidently believes that this membrane once sustained the cartilago paraseptalis communis, of such forms as the rabbit, and that the vomer is a covering bone which surrounds and takes the place of this

cartilage when it disappears, although the vomer is present along with the cartilago paraseptalis communis in the skull of the rabbit (Voit). It appears evident from a study of my slides that the vomer attains its adult condition by advancing upward in this sheet of mesenchyme, and thus comes to enclose the septum. What part, if any, the superior paraseptal cartilages play in the development of the vomer, or indeed what their real significance is, I am unable to say.

At the ventral end of the caudal border of the mesethmoid, and lying almost parallel with it, there are to be seen, upon either side, the small, straight, rod-like ventro-lateral processes (figs. 2, 3 and 18), 9 mm. in length in the model, connected by their ventral extremities with the septum (fig. 11), but having their dorsal ends free, the greater part of their length being separated from the septum by perichondrium. The condensed mesenchyme of the ventral tip of the maxilla appears immediately beneath them (figs. 2 and 18), and their material is cartilage of the same character as that of the adjacent septum. Though their dorsal extremities come into close contact with the cranio-ventral process of the median Jacobsonian cartilage, they are not connected therewith.

The Jacobsonian or anterior paraseptal cartilages (figs. 2, 3 and 18) consist of two paired masses, medial and lateral, found immediately dorsal to the ventro-lateral processes. The medial mass is a quadrangular, inwardly concave plate, 28 mm. long, whose long axis is parallel with the lower border of the mesethmoid, with which its upper edge is in close apposition, being, for the most part, only separated by perichondrium. It is much the larger of the two, and lies at a lower level than the lateral mass. The ventral extremity of the plate is drawn out to a rather sharp free point, known as the *ventral process* (fig. 2), its tip lying just below the septum. The lower border is marked, rather nearer the ventral than the dorsal extremity, by a projection, directed downward, which, however, is terminated by a sharp, backwardly turned point of cartilage, this structure being known as the *caudal process* (figs. 2 and 18). The dorsal termination is very blunt; it may be described as the dorsal bor-

der. The cranial border, almost parallel with the caudal border of the mesethmoid, presents near the ventral process a long, slender limb 1 cm. in length, which curves upward and forward, to come into close contact with the dorsal tip of the ventro-lateral process, and thus to reach the most ventral extremity of this cartilaginous mass. On the left side this off-shoot, which may be known as the *cranio-ventral process* (figs. 2 and 18), is disconnected from the septum, though only separated therefrom by a thin sheet of perichondrium; but on the right side a connection to the septum appears near the ventral end of the process. This connection, however, is very meager, the surrounding perichondrium almost cutting it off, and it would seem to be secondary. The cartilage of which the plate is composed is similar to that of the septum within. The two plates enclose a space, open below, which is filled with dense connective tissue, and at the dorsal border of the cartilages the ventral tips of the vomer are seen in it. The ventral process is connected laterally with the lateral Jacobsonian cartilage by cells of procartilage.

The lateral member of the anterior paraseptal cartilages (figs. 2–3) is a short, curved rod, 1 cm. in length, whose concavity is directed downward, forward and slightly inward, lying almost parallel with the cranio-ventral process of the medial mass which is to be found immediately internal to it. The entire lateral mass is of a younger type of cartilage than that composing the larger Jacobsonian cartilage, and upon examining the sections it is seen that it is connected with the latter at a point near the ventral process by procartilage. Otherwise the lateral mass is quite free. The adjacent portion of the lateral wall is marked by the prominent paraseptal process (fig. 2), whose tip is composed of young cartilage, and between this and the lateral Jacobsonian cartilage there is a zone of loose tissue which suggests an earlier connection between these points such as exists in the rabbit (Voit) in the form of the anterior transverse lamina. The ectethmoid would then be united with the medial Jacobsonian cartilage, the lateral member being probably a rudiment of this lamina.

In the ectethmoid (fig. 12), as we have seen, there may be recognized a roof, or tectum nasi, a lateral wall, or paries nasi, and a floor, or solum nasi. Its only connections are made medially with the septum (figs. 11 and 12) and laterally with the cartilago sphenoethmoidalis (fig. 1), both unions being through the roof. The posterior, or subcerebral portion of the tectum nasi is as yet imperfectly developed, and is concerned principally in the formation of the lateral delimitation of the fenestra cribrosa, the representative of the future cribriform plate. Dorsally this subcerebral portion is wide and flattened, and forms part of the ventral boundary of the fissura orbitonasalis. Medially it is connected with the nasal septum by a short line of attachment, interrupted by small foramina (fig. 12) while laterally it is bounded by the broken line of union with the cartilago sphenoethmoidalis. This portion narrows as it is followed ventrally, and forms the rather uneven lateral boundary of the fenestra cribrosa.

The ventral border of this fenestra is formed by the dorsal edge of the prominentia superior (fig. 1), which is a medial continuation of the sphenoethmoidal commissure connecting this to the nasal septum in front of the crista galli. Projecting backward into the fenestra cribrosa from the point of union of the sphenoethmoidal commissure with the superior prominence is a short spicule of cartilage, known as the *processus cribroethmoidalis* (fig. 1), also present in the model of Hertwig. It forms the median boundary of a small incisure, known as the *incisura cribroethmoidalis* (fig. 1) and appears to be the representative of the foramen cribroethmoidale of the rabbit (Voit), through which the anterior ethmoidal branch of the ophthalmic division of the 5th nerve passes into the nasal from the cranial cavity, to emerge, as we shall see, through the foramen epiphaniale as the external nasal ramus. In the model of Hertwig the incisure is still unclosed dorsally. It represents the ethmoidal fissure of the mature bone.

The ventral, or precerebral, portion of the roof is attached, throughout its entire extent, to the nasal septum (fig. 12). It

is almost straight, in the sagittal plane, there being a slight depression between the superior and the supraconchal (Sakterwulst—Voit) prominences. In the coronal plane the tectum is convex upwards, and, when regarded from above, it is seen to be widened by the afore-mentioned prominences.

The paries nasi may be divided into a smooth dorsal portion, the planum antorbitale (fig. 3), which forms the ventro-medial wall of the orbit, and a ventral portion, which presents a much more uneven surface, the two grading into one another in the region of the lacrimal duct. Mead states that "in the reptiles a line joining the corresponding place (commissura sphenoethmoidalis) with the processus maxillaris posterior would separate the paries nasi from the planum antorbitale. The same is true also of the mammals, although here the planum antorbitale is usually oblique instead of transverse." Upon comparison with such forms as the pig the paries nasi (sensu stricto) of man, comprising the part ventral to this line, is very rudimentary. Dorsally the planum antorbitale terminates in a rather sharp point, and upon examining the inner surface of the ectethmoid it is seen that this tip is turned inward and forward, the cartilage being directly continuous, to form the *processus cupularis posterior* (figs. 12 and 14). The border above this extends upward to the bridge of cartilage joining the dorsal portion of the tectum with the septum; it presents near its cranial extremity a small notch (fig. 12), and below this it is fitted closely to the contour of the septum within, the narrow space between being known as the cupulo-septal fissure (figs. 2 and 14) completely filled with connective tissue. This fissure marks off, upon the septum, the delimitation between its interorbital and nasal portions. The upper portion of the planum antorbitale is in close relationship to the ventral root of the ala orbitalis on account of the very rudimentary condition of the interorbital septum in the mammals. A theory accounting for the shortening of the latter is given by Mead who states: "In the evolution into the nasal capsule of the mammals the posterior part of the capsule of the reptiles has been expanded by the backward rotation of the posterior wall (reptilian planum antorbitale), the pivot being the more solid lateral side."

Below the dorsal extremity of the planum antorbitale is a wide notch, the *dorsal palatine notch* (fig. 12), partly filled by the developing upper portion of the palate bone; below this is a rounded angle, from which the sharply-marked lower border runs forward and outward, with a slight concavity downward, to end, by an upward and inward bend, upon the posterior prominence (fig. 3). When the capsule is looked at from below it is seen that the ventral two-thirds of this lowermost border is concerned with the attachment of the solum nasi (fig. 2). Above, the line of attachment of the sphenoethmoidal cartilage marks off the upper surface of the paries nasi from the tectum, and just beneath this line, and close to the surface of the planum antorbitale, but separated therefrom by connective tissue, there is to be seen a small nodule of cartilage, the cartilago paraethmoidalis (figs. 3 and 16) apparently of the same age as that of the adjacent wall. It is oval in shape and bears no apparent important relationship to the neighboring structures. Within the capsule the superior nasal meatus corresponds to the dorsal area of the planum, while the middle meatus is medial to its anterior portion.

The ventral portion of the paries nasi (fig. 3) (paries nasi *sensu stricto*), is thrown into a number of eminences, between which lie corresponding hollows. In its dorsal area is to be seen the prominentia posterior, a small swelling upon which the posterior maxillary process appears. The prominence does not extend so far laterally as the lower border of the antorbital plane behind and below it; the latter is continued upward and inward, curving over the summit of the prominence to enclose, in the downward concavity thus formed, the posterior maxillary process. The latter is wide and flat, projects ventrally and is cut off in front and above by a sharply marked furrow, being unbounded below and behind (fig. 17). The slender lacrimal bone lies along its upper border, and a short distance lateral and below is an elongated nodule of cartilage, the anlage of the processus paranasalis, which may be known as the cartilago paranasalis. This presents a free ventral extremity and a dorsal extremity closely applied to, but not continuous with, the lower aspect of the posterior prominence. It is separated from the

underlying cartilage by a thin sheet of perichondrium, and between it and the processus maxillaris posterior the anlage of the lacrimal duct may be seen. The lower surface of the prominence is rounded, and thus contrasts sharply with the lower border of the planum antorbitale immediately dorsal to it, which is sharply marked, and projects outward and downward beyond the prominence.

The cranial area of the ventral surface presents a smaller eminence, the prominentia superior (figs. 1, 3 and 12), to whose dorso-lateral edge the sphenoethmoidal commissure is attached and which medially goes over into the septum. It is to be found just ventral to the fenestra cribrosa, and the small foramen epiphaniale (fig. 3) is to be seen piercing its ventro-lateral edge. It represents a small cavity, found in the inner capsular wall. This prominence is separate from a larger one, situated upon the lateral wall, some distance in front and below, which I regard as the structure called by Voit the Sakterwulst in the skull of the rabbit. Between these prominences a shallow furrow may be observed, and this opens below into a prominent pit, delimited by the Sakterwulst, and the superior and posterior prominences. This pit corresponds, I believe, to the sulcus lateralis anterior which Voit describes in the skull of lepus, and it follows that the region dorsal to it must represent the wall of the recessus lateralis. The latter is, however, very rudimentary in man, and the corresponding area of the lateral wall in my model appears to be collapsed, when compared with the condition in the rabbit as shown by Voit's illustrations. The anterior prominence of Voit is not to be seen.

The Sakterwulst (supraconchal prominence) is the most conspicuous of all the prominences in the human ectethmoid at this stage, and presents a sharply-marked summit. Behind the latter may be seen an undulating ridge, which passes successively backward, across the sulcus lateralis anterior, over the ridge of the posterior prominence, to reach the lower border of the planum antorbitale (fig. 3). The Sakterwulst corresponds to the ventral extremity of the middle meatus of the nose; below it is a groove leading downward and backward to an incisure in the lower

border of the ectethmoid, the incisura post-transversalis (figs. 3 and 12), behind the processus paraseptalis, the latter being the representative of the anterior transverse lamina of the rabbit (Voit). The ventral surface of the Sakterwulst slopes downward, forward and inward to the upper part of the incisura narina. Upon the edge of this there is, at this point, a small projection, the representative of the cartilago cupularis of the lower forms (fig. 12).

The ventro-caudal portion of the paries nasi is raised into a slight eminence, and upon the ventral edge of this, which bounds the incisura narina, the processus alaris superior appears (figs. 2 and 12) this being, however, but rudimentary in man when compared with such forms as the rabbit. The most prominent feature of the lower edge is the elongated and slender paraseptal process, which points inward, backward and downward.

The solum nasi is formed mainly by the inferior nasal concha, which appears as the inturned lower edge of the paries nasi, and in part by the rudiments of the laminae transversales anterior and posterior, represented respectively by the processus paraseptalis and the processus cupularis posterior. The dorsal portion of the inferior concha is corrugated, and presents a free posterior edge, which meets its median border at a right angle. This dorsal edge is inwardly continuous with the lower extremity of the middle concha (fig. 12), where it joins the inner aspect of the planum antorbitale; with the latter it forms a notch, lodging the ventral portion of the upper border of the palate bone, and known as the *ventral palatine notch* (figs. 2 and 12). A rounded ridge, directed backward and inward, appears upon the lower surface, and separates two grooves, the medial being the more well-marked. This ridge is represented in the floor of the middle meatus by a wide groove which runs backward and inward to terminate by passing over the dorsal edge of the inferior concha, which thus shows a marked concavity upward.

The ventral portion of the solum is narrow and more sloping than the dorsal, and is also smoother. It terminates ventrally at the post-transverse incisure. The medial border of the inferior concha is thickened except at its extremities, and forms the lateral boundary of the basal fissure (fig. 12).

The medial surface of the ectethmoid is complicated, but is, in a general way, concave. Dorsally may be seen (figs. 12 and 14) the processus cupularis posterior projecting forward freely into the mesenchyme. This is the last remnant of the lamina transversalis posterior which is found in the rabbit (Voit), in which animal it connects ventrally with the paraseptal cartilage, but in my model there is no such connection. This is the only part of the dorsal border which turns inward, and is thus the sole representative of the median part of the cupola posterior, described for many of the lower forms. A portion of the dorsal border, a little below the lower margin of the bridge of cartilage which joins the tectum nasi to the septum is partially cut off by a thin sheet of perichondrium, and it also presents a slight thickening. Its cartilage at the ventro-cranial edge is slightly younger than that found in the adjacent wall. This may be the homologue of one of the ethmoidal conchae of the lower forms (fig. 12). Below the dorsal portion of the tectum is to be seen a small fossa, probably the representative of the spheno-ethmoidal recess of the adult condition, and this is bounded below by the anlage of the superior nasal concha (fig. 16). The latter is a small ridge of cartilage which stretches across from the medial surface of the planum antorbitale behind to the attachment of the middle concha with the wall, in front.

Below and behind the superior concha is to be seen the superior meatus of the nose (fig. 12), and it may be noted that this narrows below by reason of the fact that the line of attachment of the middle concha, which forms its lower and anterior boundary, runs from above downward, as well as backward.

The middle nasal concha (figs. 12 and 16) is somewhat larger than the superior, and presents an irregular lower edge which may be followed from a swelling of the lateral wall (which corresponds to the antero-lateral sulcus of the outer surface) backward and downward to terminate at the apex of the ventral palatine notch by running over upon the dorsal edge of the inferior concha. The edge of the middle concha is composed of very young cartilage. The middle concha is perforated, near its upper end, by a small foramen, filled by connective tissue. Its

medial surface, in its ventral and upper portion, looks inward, but as it is followed dorsally it is seen to become directed backward, and also to become much narrower, so that the dorso-caudal extremity even looks slightly outward, being separated from the adjacent medial wall of the planum antorbitale by a perceptible interval, the lower limit of the superior meatus, while its dorsal edge shows a slight prominence projecting backward a short distance before the lower end is reached.

The middle meatus (figs. 12 and 16) is quite capacious—almost cavernous—in appearance. Above, it is roofed in by the overhanging middle concha, and below it is delimited by the shelf-like inferior concha, these two conchae meeting dorsally to bound its dorsal extremity, this latter being a deep recess. Ventrally the deepest portion of the meatus is marked by a furrow, which corresponds to the Sakterwulst on the lateral surface. At approximately the center of the middle meatus, close to the lateral wall, but separated from it by a layer of connective tissue, is a small nodule of very young cartilage, surrounded, by a shell of procartilage, the latter connecting the nodule dorsally with the wall of the ectethmoid, which shows a prominence at this point. This nodule, which is known as the *cartilago meatus medii*, is situated at a point of the lateral wall just opposite to the posterior maxillary process of the lateral surface (fig. 17), and is surrounded by loose connective tissue. It occurs on both sides, but what its significance may be is uncertain.

At the root of the paraseptal process there may be seen a small hollow, corresponding to the eminence upon the outer surface. The under surface of the ventral portion of the tectum nasi is smooth, concave, and presents, laterally and above, the foramen epiphaniale, aforementioned (fig. 12).

VISCERAL ARCHES

Only the upper two visceral arches, representing Meckel's cartilage with the auditory ossicles and Reichert's cartilage, are shown in the model.

Meckel's cartilages (figs. 3–4) comprise two irregularly curved rods, each of which passes from the ventro-lateral recess of

the otic region to the site of the future mandibular symphysis, and form by the approximation of their ventral, upturned extremities the apex of an angle, the sides of which enclose the triangular area occupied by the structures composing the floor of the mouth. In cross-section each rod is seen to be of the mature type of cartilage and shows an almost uniform diameter, although the middle of the shaft is characterized by a slight but elongated spindle-shaped thickening, while the ventral upturned extremity is thickened and flattened ventro-dorsally. The dorsal extremity of the shaft, too, just before it becomes continuous with the malleus, shows a short fusiform expansion.

After leaving the ventro-lateral recess of the otic capsule, where it is directly continuous with the malleus, the cartilage proceeds forward, inward and downward, lying quite close to the pars cochlearis of the otic capsule (4 mm. in the model). It then changes its direction, passing almost directly forward, and only slightly downward and inward, thus forming, in the portion below the ala temporalis of the sphenoidal anlage, a wide curve with its concavity directed outward, forward and upward. This direction is maintained until the cartilage reaches a point a short distance in front of its termination, when it turns rather abruptly upward, and its tips become flattened, their medial edges being approximated in the midline, but being separated by a thin sheet of connective tissue, as is usual in homo. Thus a second curve, with its concavity upward and slightly outward, is formed. Upturning, enlargement and flattening of the anterior end is noted by Low first in the 18 mm. stage, and is persistent, the tip becoming later constricted off, and appearing in the 95 mm. stage of Low as a small nodule above the symphysis.

Excepting the small portion made up of the posterior fusiform expansion the shaft is flanked laterally by the covering membrane bone of the mandible, which also overlaps the ventral extremity in the manner shown in the Hertwig model, and which was noted by Low as early as the 18 mm. stage. The terminal upturned portion of the cartilage shows a general enlargement of the cells, and to the lateral surface of this the covering bone is applied very closely—indeed it would appear that this area is encased by a thin plate of perichondral bone. Within this the

cells are still larger and vacuolated, and where it fuses with the mandibular bone there is what appears to be a beginning center of endochondral ossification. Here the ground substance is much more deeply staining, and at one point a bud of osteoblastic tissue appears to be invading the cartilaginous mass. Elsewhere, however, the cartilage and covering bone are separated by a narrow interval, containing connective tissue, and nowhere else in the cartilage are there any indications of ossification.

Just beneath the posterior expansion of the shaft is seen the small, flattened tympanic bone (fig. 2), while medial and above the latter, lying with its long axis parallel to that of the Meckelian cartilage, and immediately applied to it, is the slender goniale. Above and lateral to the posterior extremity of the shaft is to be seen the squamo-temporalis.

Ventrally the mylohyoid muscle is attached to the perichondrium of Meckel's cartilage, but in the middle third its attachment is to the inner table of the mandible and its dorsal prolongation, this connection being established just above the cartilage. Hence it would appear that the mylohyoid ridge of the mature bone indicates the original position of Meckel's cartilage.

By reference to the Hertwig model it is seen that in the interval between the 40 mm. and 80 mm. stages there has been a modification of the curve of the cartilages, the dorsal curvature having been eliminated in the older stage, so that the proximal portion of the cartilage is forced away from the cochlea and the angle at the symphysis considerably widened. It would appear that in the process of development the cartilage grows more rapidly in length than in thickness, and hence with advancing age it becomes progressively more slender. This is brought out clearly when my model is compared with the earlier Low ('09) models on the one hand and with the Hertwig model on the other, the cross-section of the rod in the latter being less when compared with its length than is the case in my model, and much less than that of the earlier Low models.

Evidence of beginning ossification and resorption of the cartilage opposite the interval between the lateral incisor and canine tooth germs is first noted by Low ('09) in the 31 mm.

stage, in the form of enlargement of the cells, while in the same region, in the 36 mm. stage, he mentions ossification of the perichondrium with vacuolization and enlargement of the cells. Again, in the 55 mm. stage, he figures this region of Meckel's cartilage almost surrounded by bone, and undergoing resorption. Hertwig's model shows a complete investment of covering bone in this region. My model is intermediate between the 36 and 55 mm. stages of Low, the cartilage being only half surrounded by bone, and ossification just commencing within.

Of the auditory ossicles all are represented in the model (figs. 2 and 3). The malleus, as has been stated, is directly continuous ventrally with the shaft of Meckel's cartilage. Dorsally it is cut off from the incus by perichondrium, though in the model the two are represented as continuous, a lateral furrow marking the intervening boundary. The head of the malleus is large and rounded, and lies just lateral to the tegmen tympani, being separated by connective tissue; its manubrium is long, thickened proximally, and its tip is closely applied to the promontory of the cochlea, a condition which is strikingly different from that found in the model of Hertwig, where there is a considerable interval between these parts, caused apparently by the expansion of the middle ear region, which has thrust the upper end of Meckel's cartilage, with its affixed structures, outward. In the angle between the manubrium and Meckel's cartilage the tympanic and goniale are seen. The goniale, which represents the future anterior process, is at present unattached to the malleus, and remains so till the end of the fifth month (Broman '99).

The incus is completely separated from the malleus, in front, and from the otic capsule, behind, by perichondrium, and presents a body to which is attached a long and a short limb, morphologically resembling the adult condition. The incudostapedial articulation is formed of condensed mesenchyme, and marks the apex of a right angle, open upward, outward and backward, formed by the long limb of the incus and the two limbs of the stapes, and in this angle the facial nerve is to be found.

The stapes at this stage is circular in form, the base being imperfectly developed. The limbs are represented by well-defined, round cartilaginous rods.

Reichert's cartilages (figs. 2 and 4) are the paired cartilaginous rods, lying below the posterior half of Meckel's cartilage, which form the posterior part of the hyoid arch. Each is roughly the shape of a walking cane with a curved handle and a somewhat bent shaft. The handle-like portion is found between the lower end of the crista parotica and the lateral extremity of the jugular foramen, the fenestra perilymphatica being above it, and the paracondyloid process below. It lies quite free in the mesenchyme, separated by that tissue from the otic capsule, a condition agreeing with that described by Jacoby for an earlier stage, in which the cartilages were in contact with the otic capsule, but not fused with it, as they are shown to be in the Hertwig model of a later stage. Each cartilage is of almost uniform diameter throughout, and its direction is from behind forward, inward and slightly downward, the shaft presenting a slight outward and downward bowing, where it sweeps around the promontory of the cochlea, and a gradual inturning toward the distal extremity. As it passes forward the shaft gradually separates from the promontory, to which it is closely approximated, without being actually in contact, and at the same time draws closer to Meckel's cartilage. The terminal anterior tip lies just medial to the angle of the mandible (fig. 2), and above the greater cornu of the hyoid cartilage, which it overlaps for a short distance, without actually becoming contiguous, and it shows a rather younger type of cartilage than the rest of the shaft. The latter differs from that of the chondrocranium in being more reddish in stain.

MEMBRANE BONES

All of the purely membrane bones of the skull are represented in my embryo, though they are as yet but imperfectly developed. The interparietal appears, as has been noted, just lateral to the dorsal occipital prominence as a faintly staining spicule of osseous matter, but owing to the lack of the dorsal sections the extent of the bone could not be ascertained, and hence it was not shown in the model. Though this bone does not appear in the model of Hertwig it must have been present, as this embryo was con-

siderably older than mine. According to Mall ('06) the centers for the interparietal (one on each side) appear on the 57th day and unite on the 58th day.

Situated some distance above the otic capsule, and forming a part of the side wall of the cranial cavity, is the network of bone which is the anlage of the future parietal (fig. 4). It is roughly of diamond shape, with the long axis directed cranio-caudally, and medial to its lower border is the disappearing parietal plate, the two layers, cartilage and bone, being separated by a slight interval filled with connective tissue. There is a considerable area separating this bone from the frontal, and it is also widely separated from the interparietal, there being a very large area at the back of the cranium, behind the parietals and above the tectum posterius, uncovered by bone or cartilage.

The parietal bone is not so dense as the frontal, showing that it is probably later in appearing. Its structure presents no definite center, it being a fine reticulum throughout, though, for technical reasons, it has been represented in the illustrations as a solid plate.

The frontal bone (fig. 4) is similar in structure to the parietal, and encloses the lateral and ventral parts of the anterior cranial fossa. In it two main parts may be distinguished, a vertical portion, convex antero-laterally, and a horizontal portion, which is slightly arched upwards for the accommodation of the structures of the orbit; these being the anlagen of the corresponding parts of the adult bone. Joining these portions is a well-marked, rounded ridge, the representative of the future supraorbital ridge, and here the bone is most densely deposited, especially in the central part of its extent, indicating, probably, that in this position the first masses of osseous tissue were laid down, and not in the region where the frontal eminences will later appear, as is stated in the textbooks. The entire margin of the bone, as well as the greater area of the posterior half, is but a tessellated plate composed of intercrossing osseous spicules. The anterior extremity is rounded, and shows no definite resemblance to the mature condition; it is separated by a considerable interval

from the nasal bone, and almost touches its neighbor of the opposite side, this being the part of the bone which most nearly reaches the median plane. Posteriorly it gradually recedes from this plane, the entire medial edge of the horizontal portion underlying the outward-slanting ventro-lateral edge of the sphenoethmoidal cartilage. Its dorsal extremity is separated by a considerable interval from the parietal bone. It also, for technical reasons, is figured as a plate.

The squamosal (figs. 2, 4 and 13) is a somewhat fan-shaped bone, in which two distinct portions may be recognized; a posterior flattened plate, covering laterally the auditory ossicles and the upper part of Meckel's cartilage, and a ventral, elongated spicule of bone, the zygomatic process, whose tip is found just above the dorsal tip of the zygomatic bone. The upper edge of the flattened portion is convex upward, and is somewhat serrated, the lower border being slightly concave, and passing directly into the zygomatic process. The latter, owing to its lying parallel with the sagittal plane, meets the flattened portion at an angle, as the latter looks outward and forward (fig. 2).

The zygomatic bone (figs. 2 and 4) is somewhat quadrilateral in shape, and thus bears a resemblance to its adult condition. It already shows a body, with four angles, three of which terminate in marked projections. The body is flattened and thin, and the ventral part of its medial surface is in close apposition, though not in union, with the zygomatic process of the maxilla. From the dorso-caudal angle there projects backward a spicule of bone, whose dorsal extremity underlies the ventral extremity of the zygomatic process of the squamosal, thus identifying it with the zygomatic process of the zygomatic bone; the zygomatic arch is, accordingly, incomplete. From the cranial angle there projects upward and slightly backward the rather blunt, but strongly marked, frontal process, lying somewhat ventro-lateral to the upper extremity of the ala temporalis, and a slender elongated and inwardly curved infra-orbital process overlies the outer border of the zygomatic process of the maxilla. The caudo-ventral angle of the body is well-marked, and represents the anlage of the future malar tubercle.

The lacrimal (figs. 4 and 17) is a slender spicule of membrane bone lying along the upper and lateral part of the cartilaginous posterior maxillary process, its long axis being directed from behind forward, inward and slightly upward. Its middle part presents a slight thickening, and the naso-lacrimal duct lies immediately lateral to it.

The nasal bone (figs. 1 and 4) is represented in the model as a thin plate, rounded in outline, flattened, and about 1 cm. in diameter, lying upon the part of the upper surface of the tectum nasi which represents the medial surface of the supraconchal prominence. Behind this plate, and lying close to it, are several minute nodules of membrane bone, which also contribute to the formation of the adult bone. The nasal anlagen lies in a mass of dense mesenchyme, which overlies the entire nasal capsule, similarly to the formation described by Fawcett ('10 a and '10 b) in a 30 mm. human embryo.

The tympanic (figs. 2 and 4) is a short, flat plate of membrane bone, lying beneath the posterior extremity of Meckel's cartilage, and in front of the malleus. Its anterior part is slightly wider than the posterior, and its long axis lies parallel with that of the cartilage, its flattened surface being applied to the latter. The bone is found in an isolated anlage of condensed osteogenic mesenchyme, and is placed lateral to and below the goniale. When compared with the Hertwig model it is seen that the only part which is as yet laid down is the anterior widened extremity, there being no evidence of the ring-like form of the later bone.

By the subsequent outward swinging of the ossicles and attached Meckelian cartilages consequent upon the expansion of the region of the middle ear the plane bordering upon Meckel's and Reichert's cartilages is changed in direction, so that its outer surface looks almost directly downward, as shown in the model of Hertwig, instead of outward, as is the case in my model, and at the same time the interval between these two cartilages is relatively narrowed. This interval the tympanic bone comes to occupy, its dorsal half, as yet undeveloped in my embryo, being applied to the cartilage of Reichert in the Hertwig model, the long process of the malleus occupying a position within the ring.

The goniale (figs. 1-2) is a short, somewhat flattened, rod of membrane bone, lying immediately below and medial to the posterior fusiform enlargement of Meckel's cartilage, and so close to the latter that it appears to be developed from the perichondrium covering its surface. Its long axis is parallel with that of Meckel's cartilage, and its anlage is quite separate from that of the tympanic, which lies on a lateral and caudal plane. Its posterior end approaches close to the neck of the malleus, but does not actually become continuous therewith until the end of the fifth month (Broman '99), when it becomes the anterior or Folian process of that ossicle, a fact which was demonstrated by Dreyfuss ('93). Gaupp ('05 and '11) has given strong reasons for the identification of the processus Folianus with the goniale of the reptiles, and it is on his authority that I have used that name for it here. The bone is shown in the Hertwig model, and also appears in Low's illustration from a 95 mm. human embryo under the name of 'processus folianus.'

The vomer (figs. 2, 16, 17 and 18) is represented by two slender strips of bone lying one on either side, immediately caudo-lateral to the lower border of the mesethmoid, the two almost enclosing this border excepting for a narrow strip between their lower edges. The dorsal extremity of each strip is blunt, but the ventral is drawn out to a fine point, and near the latter there is a bridge between the two bones. The ventral point projects only a short distance in front of the dorsal border of the larger Jacobsonian cartilage.

The maxilla (figs. 2, 4, 16 and 17) is an irregular mass of cancellous bone which lies in a notch on the ventro-lateral aspect of the ectethmoid, and it already shows the frontal, alveolar, palatal and zygomatic processes. The central mass of the bone is irregularly triangular in form upon coronal section (fig. 17), the longest side of the triangle being applied to the ethmoidal cartilage, while the medial angle represents the palatal process, the upper angle the frontal process, and the remaining angle, which is a right angle, the alveolar process. The pointed, upwardly-directed frontal process reaches a level somewhat above

that of the lacrimal; its posterior surface forms the anterior wall of the space containing the naso-lacrimal duct (fig. 4). The palatal process does not quite reach to the median plane and anteriorly it is separated by a notch from the extremity of the alveolar process: its medial border is below and lateral to the vomer, and its posterior border underlies the palatine bone for a considerable distance.

The alveolar process is a very irregular ridge of bone, occupying the inferior and lateral edge of the maxilla, and its anterior end extends medially almost to the mid-line, coming to lie in advance of the palatine process. In its lower aspect may be seen the depressions for the future dental alveoli. The zygomatic process is a more lateral coarse spicule of bone, which projects backward and outward until its extremity almost touches the inner surface of the zygomatic bone. It is perforated from above downwards by foramina, and just before it joins the body of the bone it sends up a small process, which marks off a groove occupied by the second branch of the trigeminal nerve (fig. 17). There is as yet, therefore, no foramen for this nerve trunk. The posterior edge of this process is continuous inwardly with the posterior edge of the palatal process. Anteriorly a spicule from the upper part of the anterior extremity of the alveolar process projects forwards, and lies lateral to and below the anterior part of the anterior paraseptal cartilage, to which it is closely applied. This is the anlage of the anterior nasal spine.

The palate bone (figs. 2, 3, 14, 15 and 16) is a thin, delicate lamella of osseous tissue, strongly concave inward, which walls in the dorsal portion of the nasal cavity. Its borders are serrated; the upper being fitted into the dorsal palatine notch of the ectethmoid, and ventrally to this into the ventral palatine notch. The incurled lower edge (fig. 2) which becomes the palatal plate, approaches but does not meet its fellow of the opposite side, being separated from it in the model by a space of 15 mm. Dorsally the anlage of the pyramidal process is represented by a thickened and irregular projection which lies ventral to the medial pterygoid lamina.

The medial pterygoid plate (figs. 2, 3 and 10) is represented by an elongated and somewhat spiral rod, lying behind the palate bone and medial to the lateral portion of the ala temporalis. Two distinct portions may be recognized in it, the upper part being osseous and the lower cartilaginous. The former is bent dorsally and from its most posterior extremity, which is about 3 mm. from the medial angle of the lateral portion of the ala temporalis, a short but stout process projects cranio-medially, marking the highest part of the rod. Below it terminates in the cartilaginous hamular process, which points almost straight downward.

The membrane bone of the upper portion is typical in structure, and when followed downward shows a gradual transition into the cartilage of the hamular process. The cells of the membrane bone enlarge, their capsules swell, and at the same time the ground substance becomes lighter in color. Nearer the cartilage which forms a cap to the extremity of the osseous rod the capsules become smaller, the ground substance increased in amount, and the line of transition is not sharply marked. Though the tip of the cartilage partakes of many of the properties of normal cartilage—staining lightly, having a homogeneous matrix, the nuclei surrounded by capsules, and the whole being enveloped by a closely-fitting, sharply defined, thin sheet of perichondrium —yet there are several points of difference which mark out this mass of cartilage as different from that found elsewhere in the primitive skull. The matrix stains slightly more darkly, the nuclei are larger and lighter in color, and the capsules surrounding them are relatively smaller, when compared with the size of the nuclei. Altogether the cells resemble those of membrane bone more than they do those of typical cartilage.

The mandible (figs. 3–4) is a plate of membrane bone lying immediately lateral to Meckel's cartilage, and separated from this throughout its extent by connective tissue, except in a small area in the region of the lateral incisor and canine tooth germs, where, as has been noted, the bone is directly applied to the cartilage, appearing like ossified perichondrium. The posterior part of the bone is wider than the anterior, and is marked

cranially by a distinct indentation, the representative of the future sigmoid notch, which separates the anlagen of the condylar and coronoid processes. Just external to the latter is the zygomatic bone, and internal to it is the cartilaginous pars temporalis of the sphenoid. The lateral surface of the plate shows, about the junction of the anterior and middle thirds, a distinct opening, the mental foramen, and at this point there is a bend in the bone, the direction of the long axis changing from downward and forward to upward, inward and forward. A short distance above the lower border of the bone, and parallel with it, a groove may be seen upon the lateral surface, more distinct posteriorly than anteriorly. This is also shown in the illustrations of Low's older specimens, and appears to represent the line of insertion of the masseter.

The anterior half of the bone shows an inner table, regarded by some authors as the splenial element, which separates the vessels and nerves from Meckel's cartilage, becoming continuous anteriorly with the ossified perichondrium immediately surrounding the cartilage. About the center of the long axis of the bone the so-called splenial element dwindles in height, and terminates as a thin, backwardly projecting spindle of bone, to which the mylohyoid muscle is attached. Anteriorly the membrane bone overlaps the termination of the cartilage of Meckel, and thus shows the condition observed by Low as early as the 18 mm. stage.

On the whole, the shape of the mandible suggests the adult condition, though it is considerably more slender, and the angle is more obtuse. Immediately caudo-medial to the latter is the tip of Reichert's cartilage. There are no accessory cartilaginous nuclei observable, as Low describes in an older model.

Low ('05) has held that each half of the mandible is laid down as a single skeletal element, the dentary, the so-called splenial element being simply an extension of this. The condition in my embryo supports this finding, the main portion of the bone being formed of the dentary, the splenial element being but a thin lamella of osseous tissue, directly continuous below with the

anterior portion of the dentary, and posteriorly terminating in a slender process, as described. Within this medial plate the tooth gutter is well-marked. The condition is very similar to that shown by Low ('09) in his text figure 4.

CONCLUSION

From the foregoing brief account of the morphology of the human fetal skull of 40 mm. it will be seen that it presents, at this stage, several unique features. The structure of the parts surrounding the foramen magnum is significant in casting, perhaps, some further light upon the genesis of this interesting region. The presence of a fairly clearly defined neural arch of the occipital vertebra has been dwelt upon, and its interpretation discussed. The finding of a small nodule of cartilage above and in front of the cochlea is, so far as I am aware, a contribution to our knowledge of the parts in this area. Other new features are the cartilagines paraethmoidalis, meatus medii and paraseptalis superior, all of which have been briefly described; in addition may be mentioned the lateral and dorsal cranial cartilages, and the paranasal cartilage, lying lateral to the lacrimal duct.

Finally, I wish to express to Professor McMurrich my sincere appreciation of his kindness in placing at my disposal the material for this research, and the freedom of the Anatomical Laboratory of the University of Toronto, as well as of his abundant advice and encouragement.

Anatomical Laboratory, University of Toronto
September, 1913

BIBLIOGRAPHY

BARDEEN, C. R. 1901 Born's method of reconstruction by means of wax plates as used in the Anatomical Laboratory of the Johns Hopkins University. Johns Hopkins Hospital Bulletin, vol. 12.

1905 The development of the thoracic vertebrae in man. Amer. Jour. Anat., vol. 4.

1908 Early development of the cervical vertebrae and the base of the occipital bone in man. Amer. Jour. Anat., vol. 8.

1910 Morphogenesis of the skeletal system. Human embryology, by Keibel and Mall.

BOLK, L. 1904 Entwicklungsvorgänge in der occipitalen Region des Primordial-Craniums beim Menschen. Petrus Camper 2.

BROMAN, I. 1899 Die Entwickelungsgeschichte der Gehörknochelchen beim Menschen. Anatomische Hefte, Bd. 11.

DECKER, FRIEDRICH 1883 Über den Primordialschädel einiger Säugethiere. Zeitschrift für wissenschaftliche Zoologie, Bd. 38.

DREYFUSS, ROBERT 1893 Beiträge zur Entwicklungsgeschichte des Mittelohres und des Trommelfells des Menschen und der Säugethiere. Schwalbe, Morphologische Arbeiten, Bd. 2.

FAWCETT, E. 1906 On the development, ossification and growth of the palate bone of man. Jour. Anat. and Physiol., vol. 40.

1910a Notes on the development of the human sphenoid. Jour. Anat. and Physiol., vol. 44.

1910b Description of a reconstruction of the head of a thirty-millimeter embryo. Jour. Anat. and Physiol., vol. 44.

1911 The development of the human maxilla, vomer and paraseptal cartilages. Jour. Anat. and Physiol., vol. 45.

FISCHER, EUGEN 1901 Das Primordialcranium von Talpa europaea. Anat. Hefte, Bd. 17, Abth. 1.

1903 Zur Entwicklungsgeschichte des Affenschädels. Zeitschrift für Morphologie und Anthropologie, Bd. 5.

FRORIEP, A. 1886 Zur Entwicklungsgeschichte der Wirbelsäule, insbesondere des Atlas und Epistropheus und der Occipitalregion. Archiv. für Anat. und Physiol., Anat. Abth.

FUCHS, HUGO 1910 Ueber das Pterygoid, Palatinum und Parasphenoid der Quadrupeden, insbesondere der Reptilien und Säugetiere, nebst einigen Betrachtungen über die Beziehungen zwischen Nerven und Skeletteilen. Anat. Anzeig., Bd. 36.

GAUPP, E. 1900 Das Chondrocranium von Lacerta agilis. Ein Beitrag zum Verständnis des Amniotenschädels. Anat. Hefte. Abt. 1, Bd. 14, H. 3.

GAUPP, E. 1905 Neue Deutungen auf dem Gebiete der Lehre vom Säugetierschädel. Anat. Anzeig., Bd. 27, Nr. 12–13.

1906 Die Entwickelung des Kopfskelettes. Hertwig's Handbuch der Entwickelungslehre der Wirbeltiere.

1908 Zur Entwickelungsgeschichte und vergleichenden Morphologie des Schädels v. Echidna aculeata, var. typica. Semon's Zool. Forschungsreisen, Bd. 3 (Jenaische Denkschr., Bd. 6).

1910 Das Lacrimale des Menschen und der Säuger und seine morphologische Bedeutung. Anat. Anzeig., Bd. 36.

1911 Beiträge zur Kenntnis des Unterkiefers der Wirbeltiere. Anat. Anzeig., Bd. 39.

GREGORY, WM. K. 1913 Critique of recent work on the morphology of the vertebrate skull, especially in relation to the origin of mammals. Jour. Morph., vol. 24.

JACOBY, M. 1894 Beitrag zur Kenntnis des menschlichen Primordialcraniums. Archiv. für mikrosk. Anat., Bd. 44.

LEVI, G. 1900 Beitrag zum Studium der Entwickelung des knorpeligen Primordialcraniums des Menschen. Archiv. für mikrosk. Anat., Bd. 55.

LOW, A. 1905 The development of the lower jaw in man. Proc. Anat. Soc. of Great Britain and Ireland, p. 26.

1905 The development of the lower jaw in man. Proc. Anat. and Anthrop. Soc. of Univ. of Aberdeen.

1909 Further observations on the ossification of the human lower jaw. Jour. Anat. and Physiol., vol. 44.

LUSCHKA, H. 1862 Die Venen des menschlichen Halses. Denksch. der K. Akad. Wien, Bd. 20.

MALL, F. P. 1905 On the development of the blood-vessels of the brain in the human embryo. Amer. Jour. Anat., vol. 4.

1906 On ossification centers in human embryos less than one hundred days old. Amer. Jour. Anat., vol. 5.

MEAD, CHARLES S. 1909 The chondrocranium of an embryo pig, Sus scrofa. Amer. Jour. Anat., vol. 9.

NOORDENBOS, W. 1905 Über die Entwickelung des Chondrocraniums der Säugetiere. Petrus Camper, Deel, Bd. 3, Afl. 3 u. 4.

PETER, K. 1902 Anlage und Homologie der Muscheln des Menschen und der Säugetiere. Archiv. für Mikrosk, Anat., Bd. 60.

SALZER, H. 1895 Über die Entwicklung der Kopfvenen des Meerschweinchens. Morphol. Jahrbuch, Bd. 23.

VAN NOORDEN, W. 1887 Beitrag zur Anatomie der knorpeligen Schädelbasis menschlicher Embryonen. Archiv. für Anat. und Physiol. Anat. Abth.

VOIT, MAX 1909 Das Primordialcranium des Kaninchens unter Berücksichtigung der Deckknochen. Anat. Hefte, Bd. 38.

ZUCKERKANDL, C. 1908 Über den Jacobsonschen Knorpel und die Ossification des Pflugscharbeines. S.B. d. Wiener Akad. Wiss. Math.-naturw. Kl., Bd. 117, Abt. 3.

ZUCKERKANDL, E. 1892 Die Siebbeinmuscheln des Menschen. Anat. Anzeig., Bd. 7.

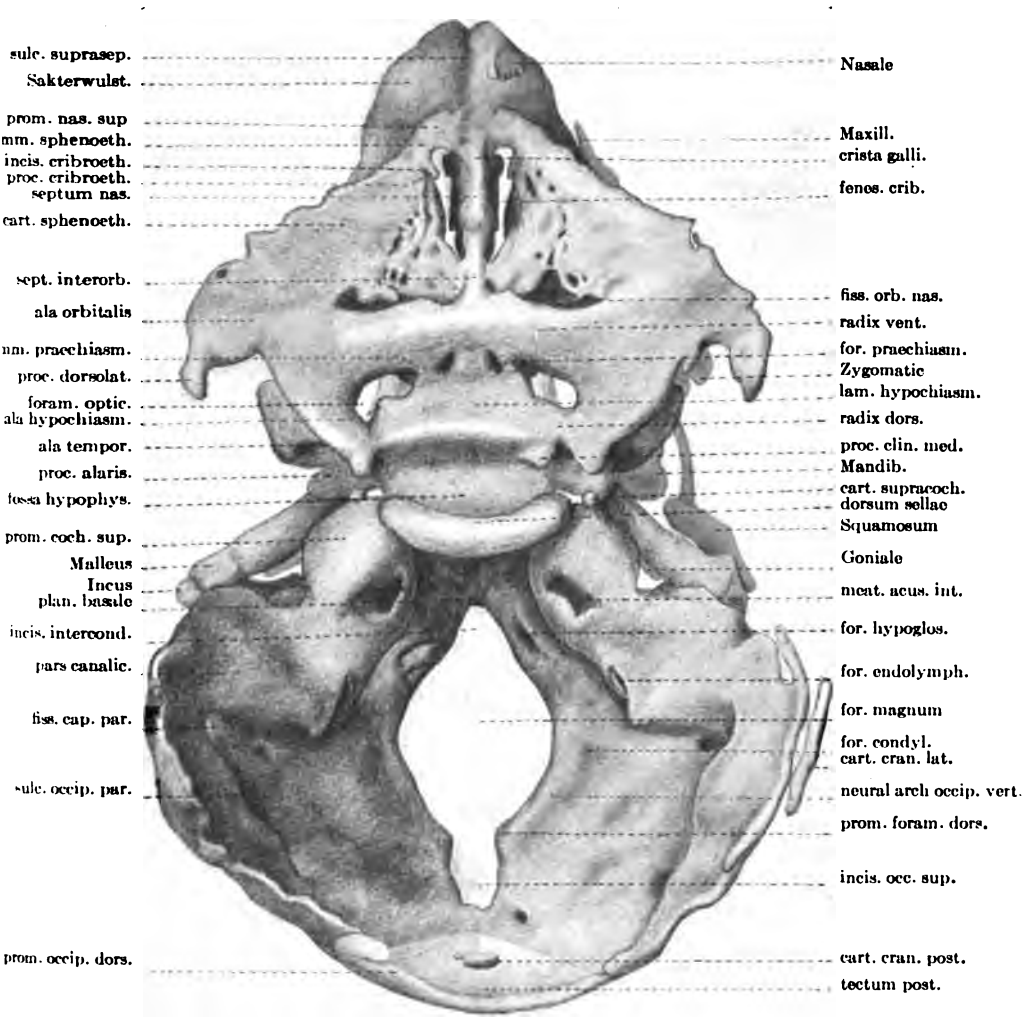

1 Wax plate reconstruction of the chondrocranium of a 40 mm. human fetus, seen from above.

SKULL OF A HUMAN FETUS

CHARLES CLIFFORD MACKLIN

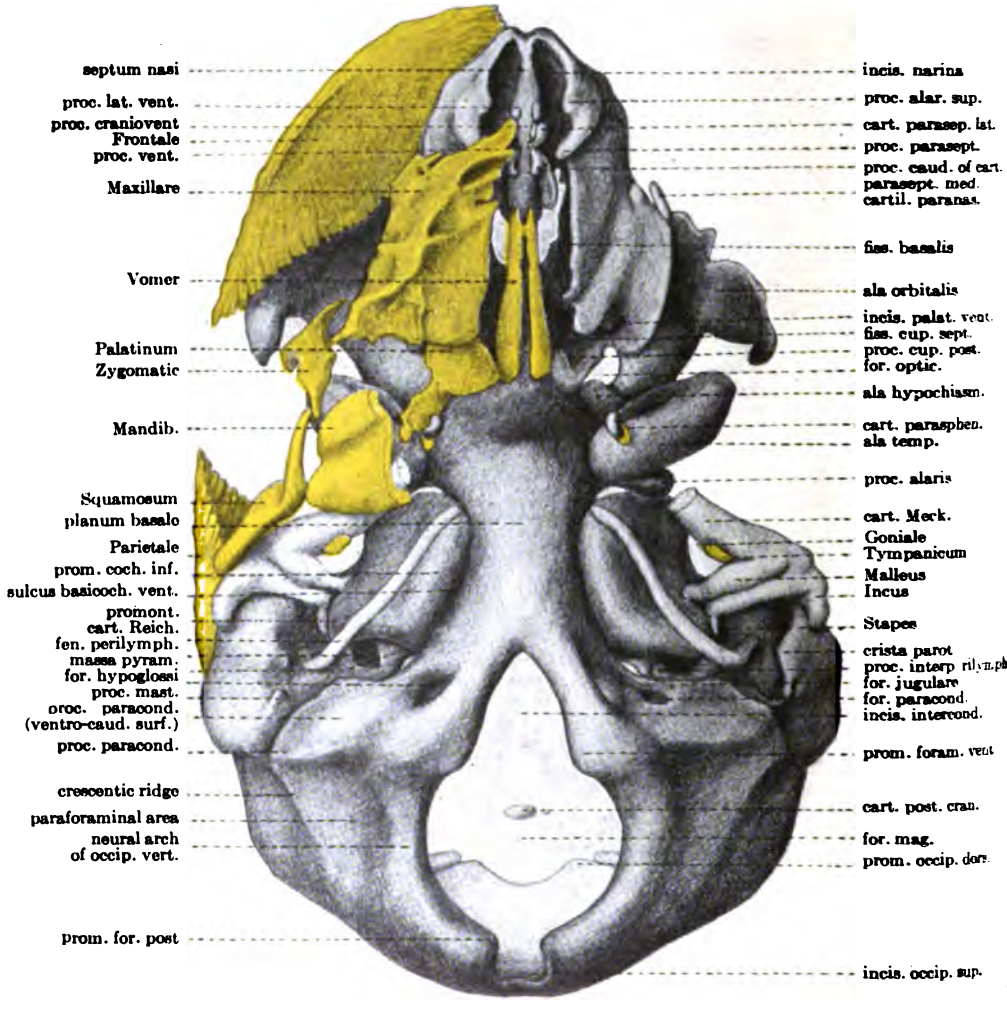

2 Skull seen from below.

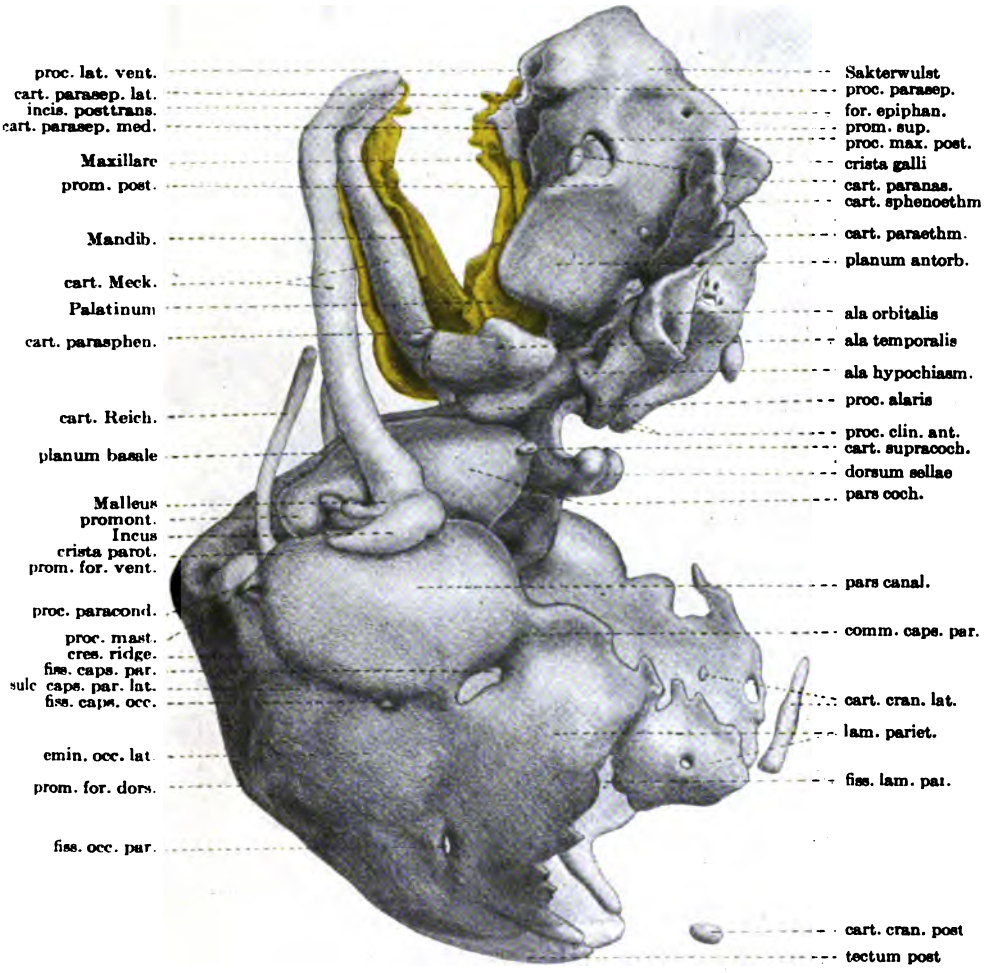

3 Skull seen from left side.

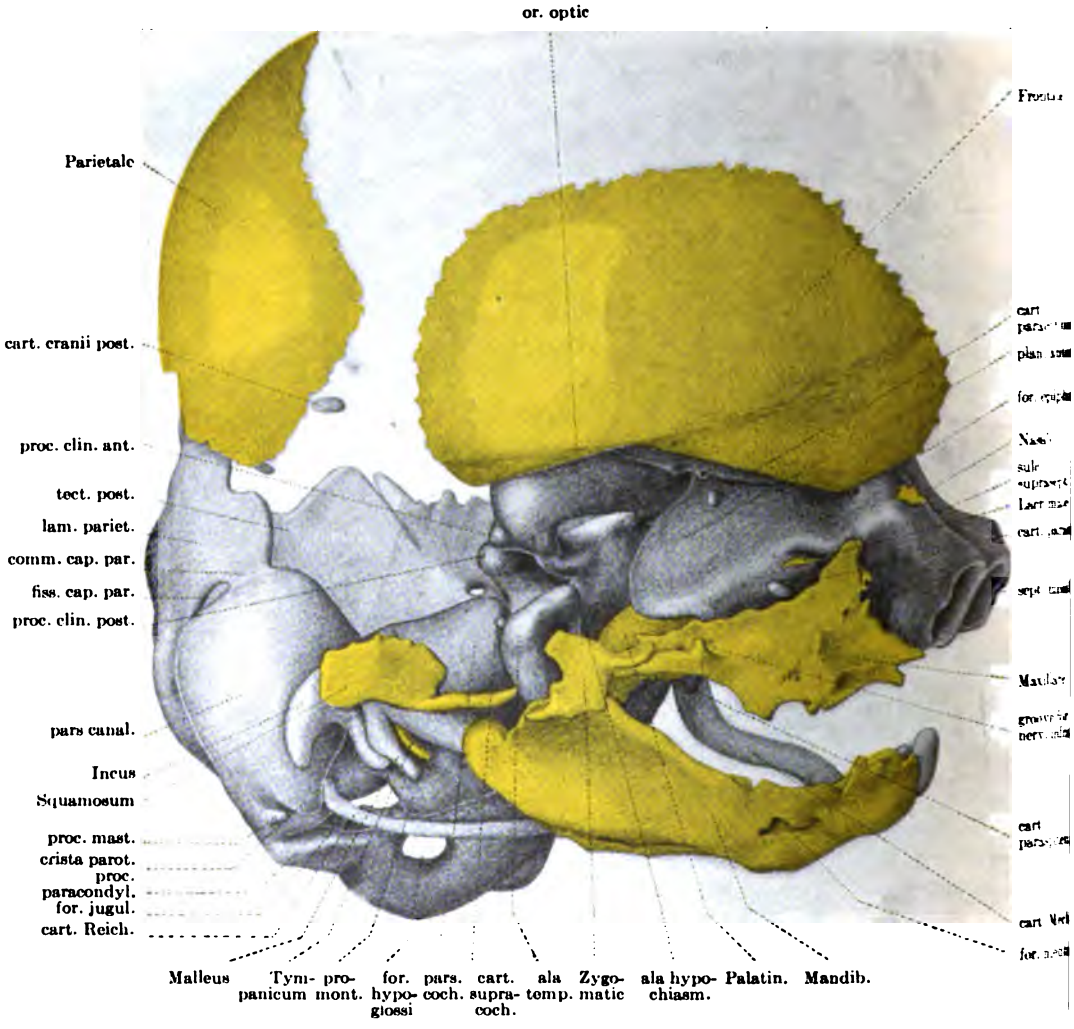

4 Skull showing the right anterior aspect.

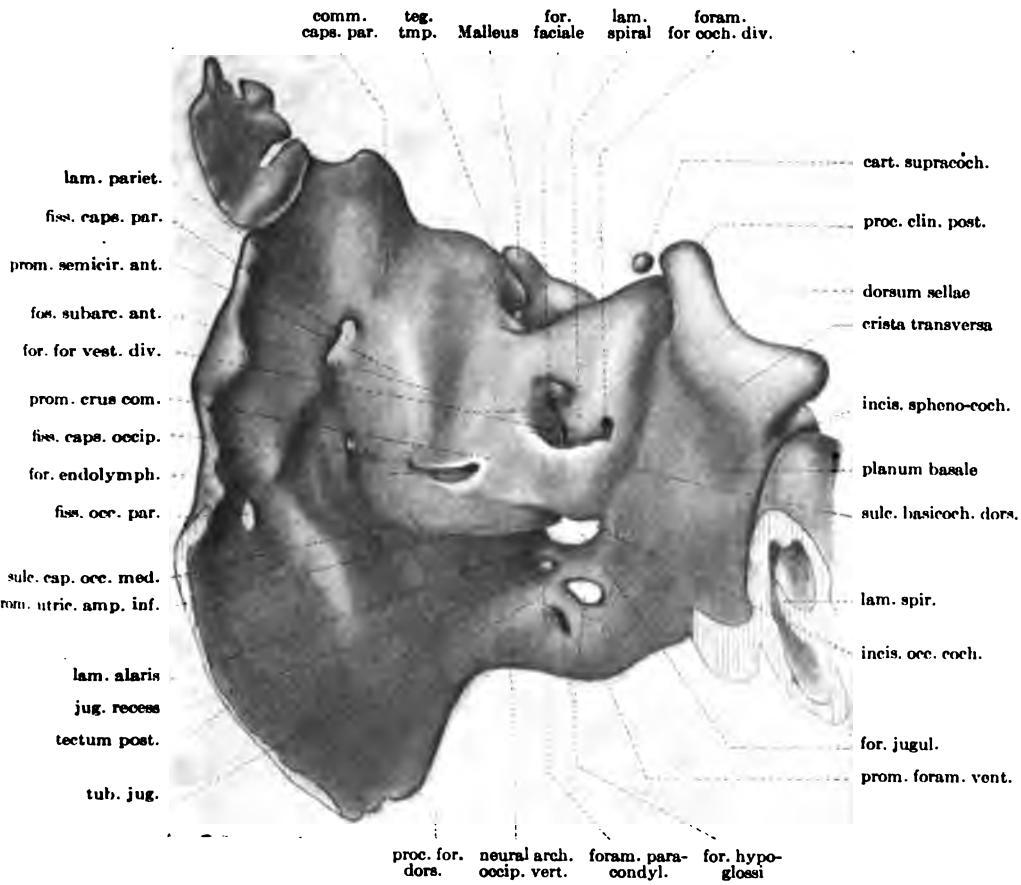

5 The left otic and occipital regions, viewed from within.

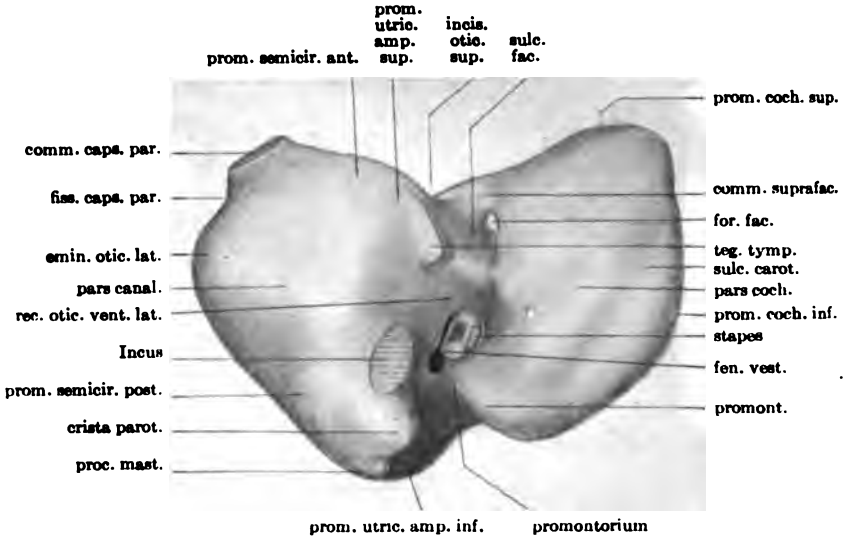

6 Lateral aspect of right otic capsule.

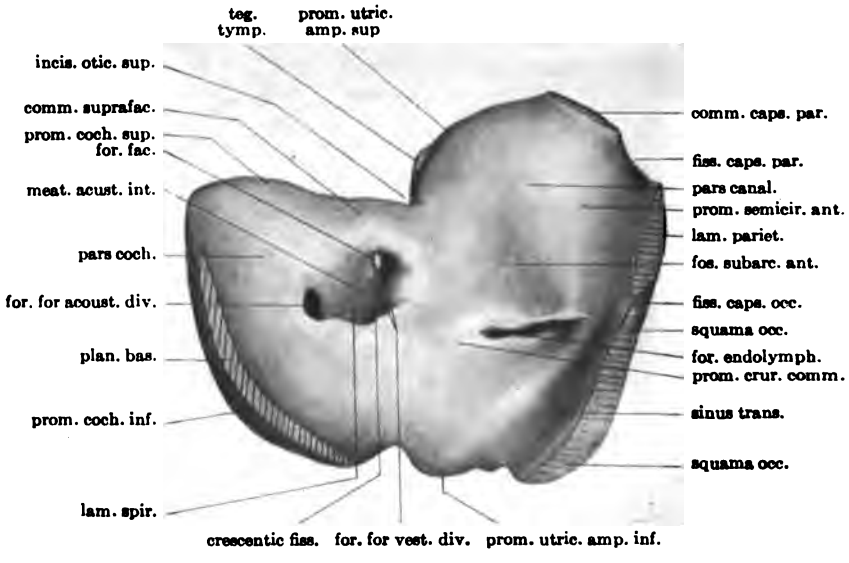

7 Medial aspect of right otic capsule.

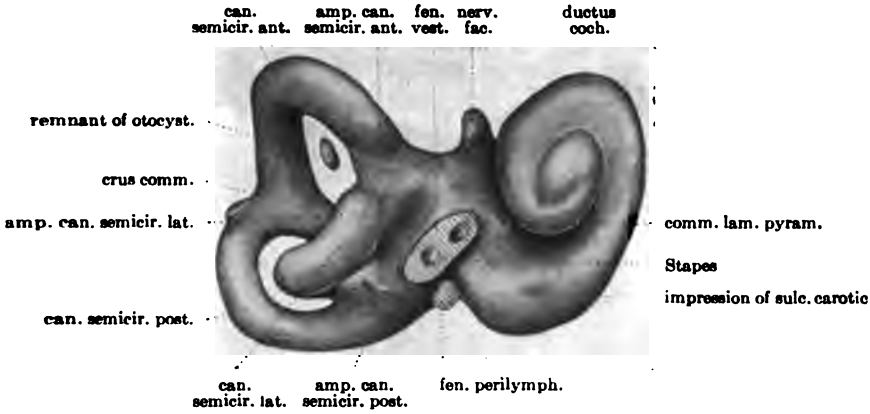

8 Lateral aspect of cast of cavity of the right otic capsule.

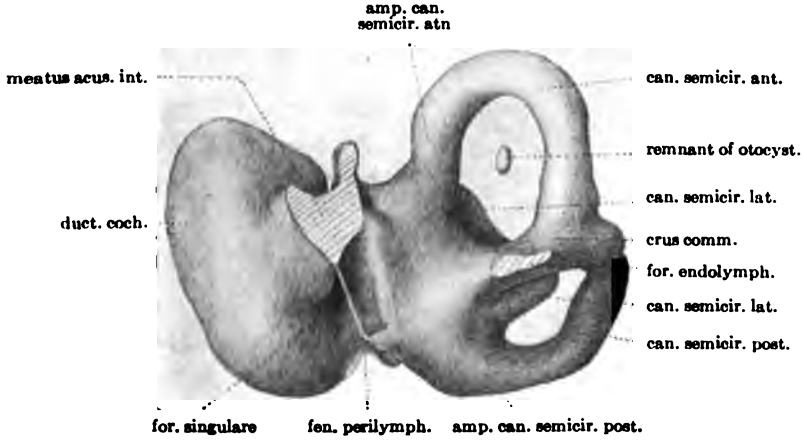

9 Medial aspect of cast of cavity of the right otic capsule.

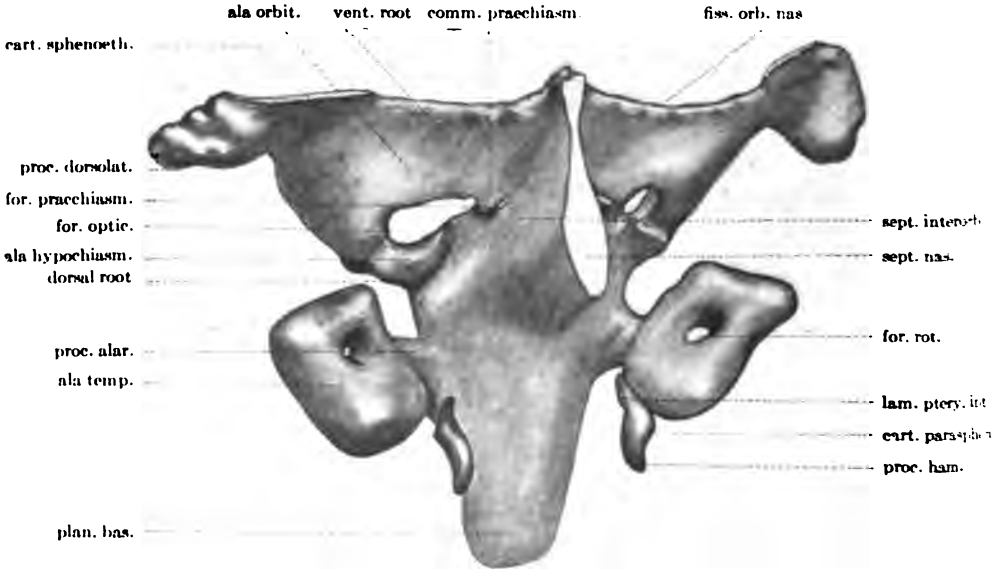

10 Antero-lateral aspect of detached sphenoidal region.

11 Shows the nasal and interorbital septa from the right side. Unions with ventral root of ala orbitalis, tectum nasi of ectethmoid, ventro-lateral process, and anterior paraseptal cartilage are seen. The superior paraseptal cartilage appears in the more dorsal area. The dorsal cut surface of the interorbital septum could not be represented from this position, but it begins above a little below the level of the lower edge of the ventral root of the ala orbitalis. Dorsal to this root the posterior edge of the illustration represents the dorso-cranial border of the septum interorbitalis.

12 Medial aspect of left ectethmoid. Unions with the nasal septum are shown.

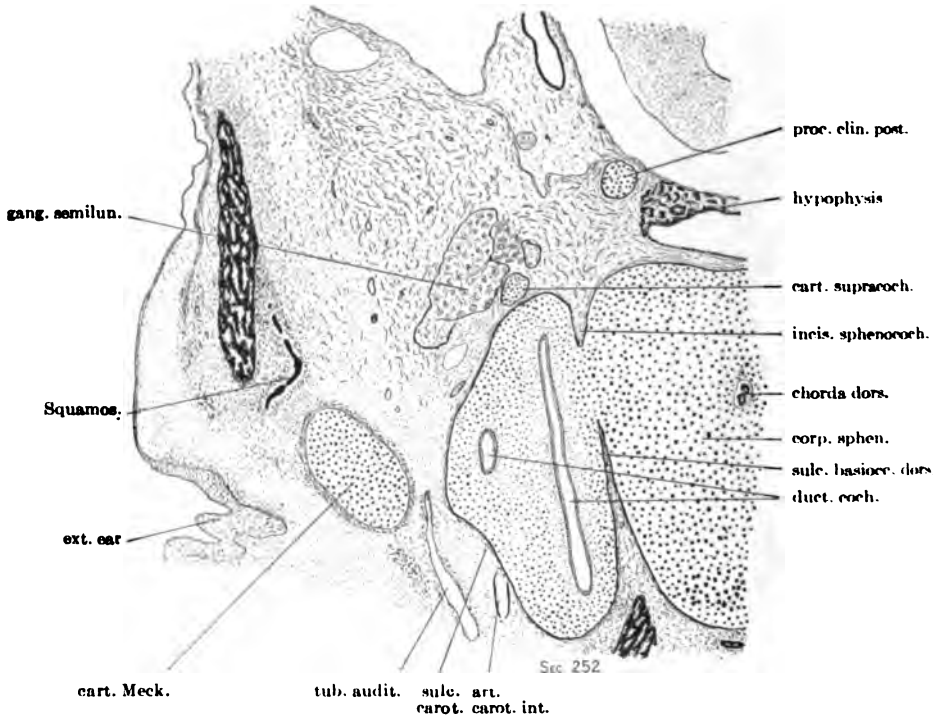

13 Coronal section through head at level of hypophyseal fossa, showing the cartilago supracochlearis overlaid by the semilunar ganglion.

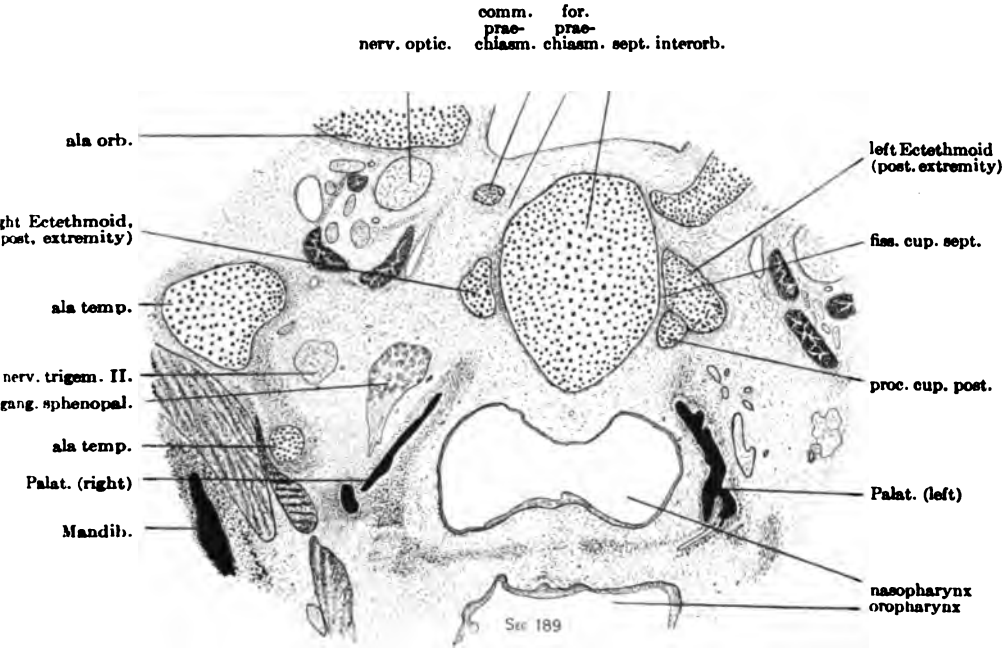

14 Coronal section through head showing dorsal part of ethmoidal and ventral part of orbitotemporal region. Asymmetry is due to obliquity of section. The posterior cupular process on the left side (right side of illustration) is shown joining with the side wall; on the other side, in which the plane of section is posterior, the process is completely joined to the ectethmoid.

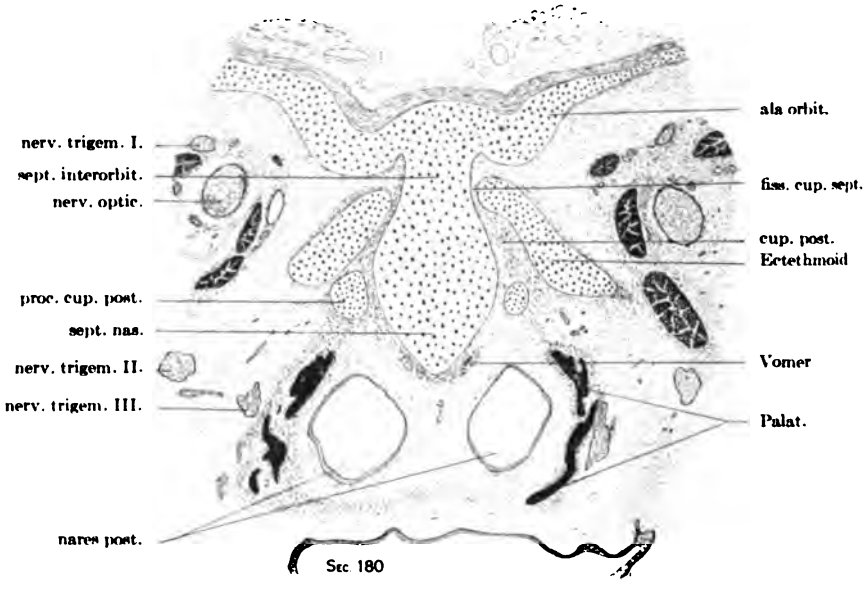

15 Coronal section through the dorsal part of ethmoidal region, showing posterior cupular process, the nasal septum, the interorbital septum with attached alae, and the palatine and vomer.

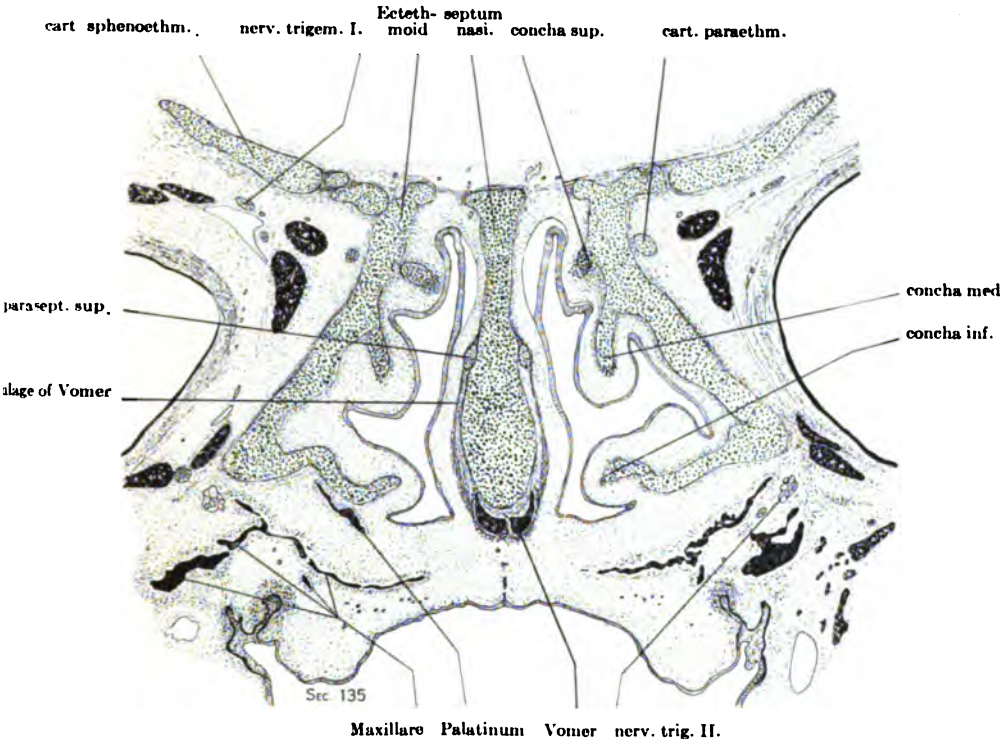

16 Coronal section through the ethmoidal region, showing superior paraseptal cartilages, paraethmoidal cartilages, the vomer, maxilla, and palate bones.

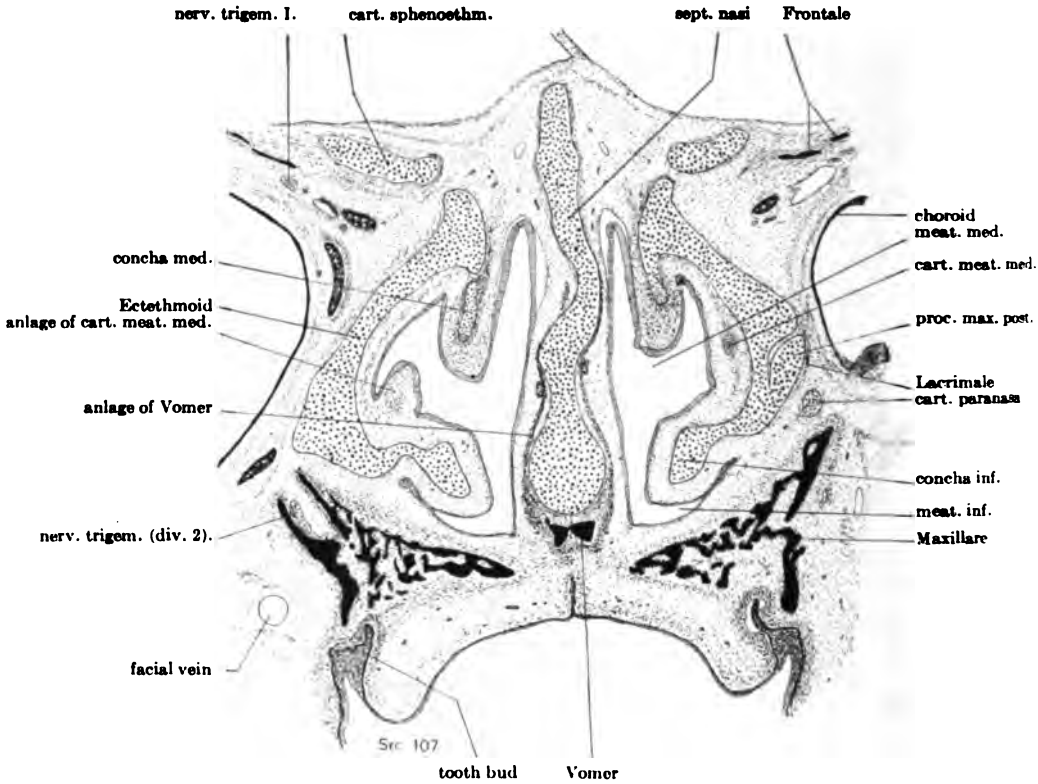

17 Coronal section through ethmoidal region, showing nasal septum, ectethmoid, with attached conchae, cartilago paranasalis, and vomer, maxilla and lacrimal bones.

AM—Anlage of the maxilla
CP_1—Cranio-ventral process of medial lamina of anterior Jacobsonian cartilage
CP_2—Lateral lamina of anterior Jacobsonian cartilage
CP_3—Body of medial lamina of anterior Jacobsonian cartilage
CP_4—Caudal process of medial lamina of anterior Jacobsonian cartilage
CP_5—Dorsal extremity of lamina of medial anterior Jacobsonian cartilage
Ep—Epithelium of nasal cavity
J—Organ of Jacobson (right)
Jd—Duct of left organ of Jacobson
Jm—Meatus of duct of right organ of Jacobson
M—Mesèthmoid
MS—"Suspensory membrane" of Fawcett, the anlage of the vomer
OM—Maxilla
OV—Vomer
PV—Ventro-lateral process

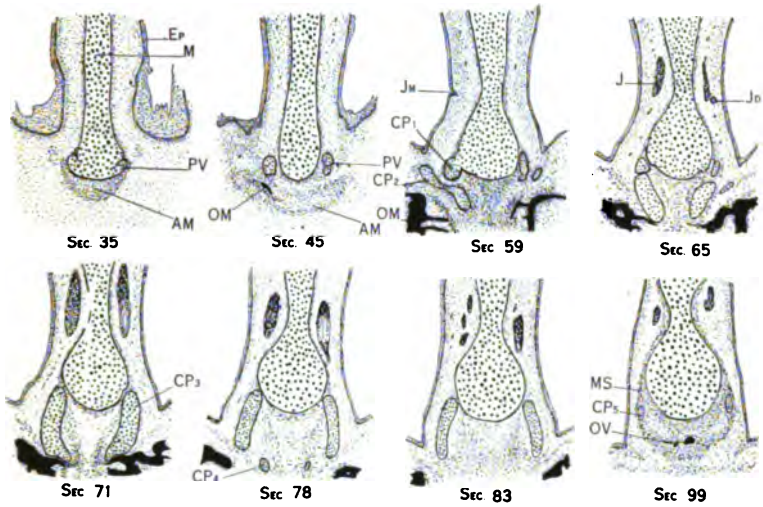

18 Series of eight coronal cross-sections, through caudal portion of mesethmoid, in the region of the anterior paraseptal cartilages. Sections numbers 35, 45, 59, 65, 71, 78, 83, and 99. Magnif.

Section 35 shows the ventral end of the ventro-lateral process, *PV*, and its connection with the caudal border of the mesethmoid. In section 45 the dorsal ends of these processes are shown in cross section, with the ventral extremity of the maxilla *OM*; the membranous anlage of this bone appears in sections 35 and 45—*AM*. Part of the epithelium of the nasal cavity is represented in all the sections *Ep*. Section 59 is through the ventral end of Jacobson's cartilage and shows the cranio-ventral process of the medial lamina CP_1 on the right side attached to the mesethmoid, while the outer lamina, CP_2 lies free in the mesenchyme. Owing to the section having been cut somewhat more deeply on the right than on the left side, the left side of the illustration shows a somewhat more dorsal plane than does the right. The meatus of the right Jacobsonian duct opens at *Jm* in section 59. Section 65 shows, on the right side the dorsal tip of the left outer lamina of Jacobson's cartilage, and medial to this the main part of the inner lamina below, and the cranio-ventral process above. The organ of Jacobson appears in this and following sections, and it will be observed that the mesethmoid has become quite thin in its vicinity, the organ lying in a concavity of the cartilage. In section 71 the main lamina of Jacobson's cartilage is seen CP_3, and it will be noted that at its caudal extremity the relationship to the maxilla is very intimate. In the next section, No. 78, the caudal process is seen separated from the main mass of the cartilage, and in the next section, No. 83, this process has disappeared. In No. 99 the dorsal tips of the Jacobsonian cartilages are seen CP_5, and below the mesethmoid, lying in a mass of condensed mesenchyme, the anterior tips of the vomer are seen as two small spicules of bone.

UNIVERSITY OF TORONTO STUDIES

ANATOMY

No. 1: The anatomy of the orang-outang, by Professor A. Primrose . . . . . 25p.

No. 2: The skull of a human fetus of 40 mm., by Charles Clifford Macklin. . . . . 15p.

EXCHANGE
MAY 14 1919

UNIVERSITY OF TORONTO STUDIES

ANATOMICAL SERIES

No. 3: ANATOMY OF A SEVEN MONTHS' FOETUS EXHIBITING BILATERAL ABSENCE OF THE ULNA ACCOMPANIED BY MONODACTYLY (AND ALSO DIAPHRAGMATIC HERNIA), BY JAMES CRAWFORD WATT

(REPRINTED FROM THE AMERICAN JOURNAL OF ANATOMY, VOL. 22)

THE UNIVERSITY LIBRARY: PUBLISHED BY
THE LIBRARIAN, 1918

University of Toronto Studies

COMMITTEE OF MANAGEMENT

Chairman: SIR ROBERT ALEXANDER FALCONER, LL.D., K.C.M.G.
President of the University

PROFESSOR W. J. ALEXANDER, PH.D.

PROFESSOR W. H. ELLIS, M.A., M.D.

PROFESSOR J. J. MACKENZIE, B.A., M.B.

PROFESSOR J. P. MCMURRICH, PH.D.

PROFESSOR G. H. NEEDLER, PH.D.

PROFESSOR GEORGE M. WRONG, M.A.

General Editor: H. H. LANGTON, M.A.
Librarian of the University

AUTHOR'S ABSTRACT OF THIS PAPER ISSUED BY THE BIBLIOGRAPHIC SERVICE OCTOBER 20.

Reprinted from THE AMERICAN JOURNAL OF ANATOMY, Vol. 22, No. 3, November, 1917

ANATOMY OF A SEVEN MONTHS' FOETUS EXHIBITING BILATERAL ABSENCE OF THE ULNA ACCOMPANIED BY MONODACTYLY (AND ALSO DIAPHRAGMATIC HERNIA)

JAMES CRAWFORD WATT

Department of Anatomy, University of Toronto

FOUR TEXT FIGURES AND FOUR PLATES

CONTENTS

Introduction 385
Preservation 386
Parental history 386
External appearance 386
Radiographs 391
Dissection of left arm 395
  Muscles 395
  Nerves 409
  Vessels 411
Embryological and general considerations 413
Diaphragmatic hernia 425
Bibliography 428

INTRODUCTION

The foetus forming the subject of description in this paper exhibits the rare deformity of complete absence of the ulna in each arm, accompanied by the still much rarer condition of monodactyly (figs. 1 to 4). This latter condition is not to be confused with the relatively common condition of syndactyly, where more than one digit is present, but they are united by a web of skin and other tissues. Monodactyly, the presence of only one digit, is very uncommon, and in a search through the literature only one case was found that resembles the present one, and that was presented as a freak exhibit at a medical society, no anatomical investigation of it having been made.

I have, therefore, undertaken to work out the special anatomical details of muscles, vessels and nerves in one of the deformed limbs, in the hope that light might be thrown on some of the primitive conditions of these parts, and also with the purpose of adding a definite and exact contribution to the present inadequate knowledge of this abnormal condition. "Indeed the inquiry into several types of malformation and structural anomaly has repeatedly thrown light not only on the malformation or anomaly itself but also upon the normal process of development the disturbance of which it represents."—(Ballantyne).

PRESERVATION

This specimen was not obtained until about one week after its birth, and in the meantime had been kept immersed by the undertaker who sent it to us, in an embalming solution which, as far as can be ascertained, was practically a 10 per cent formalin solution. In the laboratory it has been kept in 80 per cent alcohol. No injection of the blood vessels was attempted, and though this has added somewhat to the difficulty of dissection, good results have been obtained.

PARENTAL HISTORY

The parental history, as far as could be ascertained, is practically negative concerning the deformity in this foetus. The parents are about twenty-five years of age, in comfortable circumstances, have good mentality and are free from venereal diseases as far as known. There have been two miscarriages previous to this one, with no deformities.

EXTERNAL APPEARANCE

The body of the foetus (figs. 1 and 2) is that of a well developed child born at the end of the seventh calendar month of pregnancy. It is well formed, healthy looking, and apart from the upper limbs has no superficial evidence of abnormality. The sex is male, and no aberrant development of the external genitals is present. The back is strongly curved, the head bent forward,

and the legs strongly flexed and drawn up against the abdomen. On following the line of the vertebral column, a slight scoliosis is observed in the thoracic region convex to the right.

The whole body is covered with a well developed lanugo moderately dark in color, and on the head is abundant fine black hair about 2 cm. in length. Nails are present on all the digits of both upper and lower limbs, but are yet some distance from the extreme ends.

The weight of the child is 1280 grams, and the length from the vertex of the skull to the ischial tuberosity, measured over the back, is 325 mm. These measurements correspond fairly well with figures given by Keibel and Mall ('10) and by McMurrich ('15) for the seventh month.

The deformed upper extremities show an upper arm segment with the forearm flexed upon it and united to it by a web of skin, a narrow carpal region and a single digit. On the right arm there is also a single digit located at the inner side of the elbow. The general resemblance to the wing of a chicken plucked for cooking is strong, and led to the assertion that the mother's fondness for visiting the zoological gardens and watching the birds was responsible for this deformity, because she had spent much time in this way during the spring and summer months of her pregnancy. Maternal impressions have been credited with many strange and miraculous powers without any rational basis, and this is surely an example where a credulous imagination has been led far astray. A mere coincidence has been used to work out a sequence of cause and effect, and, like much circumstantial evidence, there is here no basis for the assumption that the two facts have in truth any association whatever. Only a very slight knowledge of human embryology is necessary to shatter the theory in this case. The bird impression, if it may be so called, seized the mother during the spring and summer when she had a strong desire to be out of doors. It may be assumed that the deformity in the limbs was an accomplished fact when the limb skeleton was laid down and so was present at the time of the appearance of ossification in the limbs in the seventh week of development. Indeed it may even be

assumed that the deformity was already established at the time when chondrification began and its origin is thus carried back to at least the fifth week and to a time when the mother would just begin to suspect that she had become pregnant, as her expected menstrual period would then be a week overdue. No visits to the zoo were yet thought of, as this was in midwinter, and yet the deformity was even then an accomplished fact which future development could not alter, but only make more clear and accentuated.

The deformed limbs will now be described in more details In each arm (figs. 3 and 4) the shoulder and scapular regions appear normal, but slightly flattened, as though from pressure from the body lying on its side. The upper arm segment lies parallel to the long axis of the body, close in at the side, and appears flattened from side to side so that its mediolateral transverse diameter is only two-thirds that of the dorsoventral. It is gently tapering in outline, narrowing as the elbow is approached. The elbow is fairly well rounded, and from it the forearm runs forward in the same plane as the upper arm and flexed on it at an acute angle, being maintained in the position by a thick web of skin extending across the interval between arm and forearm. The part of the forearm beyond the attachment of the web is rounded, with its transverse diameters about equal, and tapers gradually distally. The carpus, metacarpus and the single digit also taper continuously distally, and are all in a position of partial flexion, showing marked creases or folds on the volar surface at the line of the joints. There is a well developed nail on the digit, but it does not yet reach to or project beyond the end of the finger,, as is the case in a child born at full term.

The left forearm and hand (fig. 3) are in the same plane as the upper arm and in a position of complete pronation. The hand lies against the side of the cheek, the palm facing directly ventrally. Flexion in this hand is gradual.

The right forearm and hand (fig. 4) are in a position midway between pronation and supination, a position identical with that normally assumed when the limb skeleton is first defined (Lewis, Keibel and Mall's Human Embryology). The distal end of the

forearm curves somewhat inward and the carpus is sharply flexed upon it and the hand thus comes to lie across the body under the chin, with the palm facing caudally.

The left arm has no accessory appendages or indications of any of the missing parts, but on the right one (fig. 4) there is a flattened appendage attached by a very short narrow circular stalk to the medial surface of the forearm almost at the elbow. This structure widens immediately beyond its attachment, being much compressed and running back applied against the surface of the arm, and from the distal part of this broader portion a narrow finger-like process extends at right angles up in the line of the limb, pointing toward the hand. This appendage strongly resembles another digit arising at the elbow.

Measurements of the foetus, and especially of the deformed limbs are here appended in tabular form:

Weight of foetus	1280 grams
Length from vertex to ischial tuberosity	325 mm.
Ischial tuberosity to bend of knee	80 mm.
Bend of knee to tip of heel	75 mm.
Ischial tuberosity to tip of heel	155 mm.
Tip of heel to distal end of digit I	63 mm.

Deformed upper extremities

LENGTHS	RIGHT	LEFT
Acromion process to point of elbow	82 mm.	74 mm.
Point of elbow to distal end of radius	57 mm.	52 mm.
End of radius to finger tip	35 mm.	25 mm.
Skin web		
From point of elbow to free edge	35 mm.	37 mm.
Angle of divergence of axis of arm and forearm		
At rest	28 degrees	24 degrees
Extended to utmost	50 degrees	45 degrees
Extra digit		
From pedicle to outer edge of broad portion	12 mm.	
Outer edge of broad portion to tip of digit	18 mm.	
From pedicle straight to tip of digit	20 mm.	

WIDTHS	RIGHT		LEFT	
	Dorso-ventral	Transverse	Dorso-ventral	Transverse
	mm.	mm.	mm.	mm.
Arm at axilla	33	19	30	20
Arm at free edge of skin fold	29	16	25	17
Arm one centimetre above elbow	27	18	23	17
Forearm where first free	14	15	14	13
Carpus	12	12	10	8
Digit at middle phalanx	6	5	6	4
Extra digit				
Pedicle	7	4		
Proximal third (metacarpal region)	12	6		
Middle third (proximal phalanx)	7	5		
Distal third (distal phalanx)	5	4		

The only case recorded that closely resembles this one is one reported by Barabo ('00). The complete description as given by him follows:

Ferner berichtet Herr Barabo über eine eigenartige Missbildungen an den Armen und Händen eines nicht vollständig ausgetragenen Kindes. Das Kind, 2800 gm. schwer, 46 cm. lang, war mit Wolfsrachen behaftet. Der rechte Oberarm von der Schulter bis zur Ellbogenspitze war 7 cm. lang; der Vorderarm bis zum Handgelenk 4 cm. Am Vorderarm war nur ein Vorderarmknocken vorhanden. Von der Beugeseite des rechten Oberarmes ausgehend lief eine Hautfalte auf den Vorderarm, die 1 cm. unterhalb des Ellbogengelenks inserirte und den Vorderarm in spitzwinkeliger Beugestellung hielt. An der rechten Hand war nur ein vollkommen entwickelter Finger und Mittelhandknocken vorhanden. Die übrigen Finger und Mittelhandknocken fehlten.

Der linke Oberarm zeigt ebenfalls ein Längenmaass von 7 cm.; der Vorderarm war 5 cm. lang; die beiden Vorderarmknocken waren normal entwickelt. Es fehlt ebenfalls die ganze mittelhand. Der Daumen, rudimentar entwickelt, sass direct auf dem Handgelenk auf und war 1 cm. lang und mit dem 4 cm. langen Zeigefinger durch Syndaktylie verbunden. Mittel- und Ringfinger fehlten. Der Kleinfinger war vorhanden und 4 cm. lang.

Der Vortragende lässt die Frage offen, ob die Missbildunge auf abschnürung durch amniotische Fäden oder Hypoplasie zuruckzuführen sei.

From the above account it will be seen that the right arm in Barabo's case shows exactly the same condition of a webbed

elbow, single bone in the forearm and monodactyly, as is shown in both arms of the foetus described by me. This is an important point as it leads to the assumption that this condition is a very definite one, which although very rare is not purely a chance occurrence but may have some definite cause. Thus it would be the concrete indication of the previous working at a certain particular period of development of some definite vicious or teratogenic influence.

RADIOGRAPHS

Four radiographs were made of the foetus in the X-ray department of the Toronto General Hospital. Plates were made of the whole body from the front and from the side, and also special ones of each arm from the side. The definition of structures in the plates was excellent and identification of various parts was an easy task. Prints made from these plates, however, were unsatisfactory, since heavy prints intended to show structures with light shadows made heavier parts a solid mass of shadow without detail, while light prints did not bring out distinctly the lighter parts. Three prints of each plate were made, a heavy, a medium, and a light, and from these and the plates, the following description has been pieced together. The illustrations are from actual tracings from the plates and are designed to show only essential structures.

The radiograph of the left arm (text fig. A and fig. 6) shows a well-developed scapula of normal proportions, and articulating with it the humerus, which is fairly heavy and of typical shape. The upper end is well expanded as is also the lower, but as might be expected no ossification is yet present in the epiphyses. The lower end extends almost to the end of the bend of the elbow, and coming off in front of it is a single bone lying in the forearm. Owing to the cartilaginous condition of the epiphyses, no articulation can be demonstrated, only the osseous tissues showing. That this bone in the forearm is the radius is quite evident from its shape, the upper end being narrow and the shaft round above and gradually broadening as it proceeds distally, the entire bone being also slightly curved in

its length. Beyond the radius is a considerable clear interval including all the carpal and metacarpal region where there is yet no ossification, but in the single digit a small rectangular ossification is seen proximally and another occurs distally, these representing the shafts of the proximal and distal phalanges. Between the two is a clear space where the still unossified cartilage of the middle phalanx lies.

The right arm (text fig. B) presents a few differences from the left. The scapula and humerus are both typical. The humerus does not, however, reach as near the point of the elbow as does

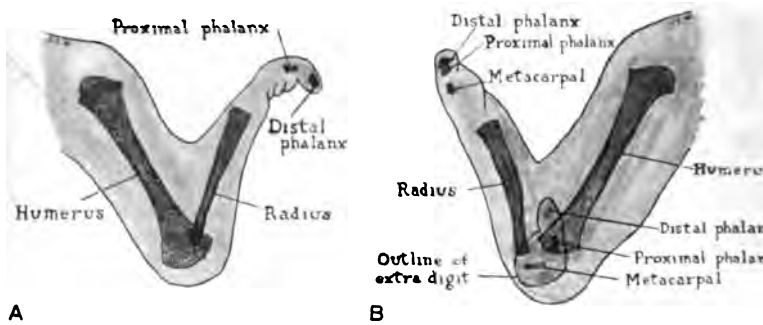

Text fig. A Sketch from a radiograph of the left arm showing the ossified portions of the skeleton.

Text fig. B Sketch from a radiograph of the right arm showing the ossified portions of the skeleton. Note the extra digit at the elbow.

that of the left arm, the end of the radius lying under it instead of in front of it. The radius is more curved than in the left arm. No carpal bones yet appear, but in the metacarpal region there is a small ossification representing the shaft of a single bone. As on the left side ossifications for the proximal and distal phalanges are present in the digit, while no middle phalanx yet shows. The proximal phalanx is not as well developed as on the left side.

The appendage at the elbow on the right limb (text fig. B) is interesting. Its pedicle appears in the interval between the humerus and radius and running dorsally in its broad part

is a well marked metacarpal ossification, and at right angles to this and lying in the narrow digital part of the appendage is the ossification representing the first phalanx. In the region of the second phalanx there is yet no bone, while the distal phalanx is represented by an extremely small centre of ossification.

Some delay is thus evident in the processes of ossification in these limbs since the appearance of the primary center in a metacarpal is usually in the ninth week and for a middle phalanx about the twelfth week. (Keibel and Mall.)

The skeleton of the lower limb (fig. 5) appears to be normal except that no middle phalanges yet show ossification. Metatarsals, proximal and distal phalanges are all ossified as are also the talus and calcaneus. The long bones are normal. Delay in ossification in the middle phalanges is again evident in these limbs.

The skull shows no abnormalities, although ossification is very heavy in the base, especially in the petrous regions and body of the sphenoid, but the vertebral column and ribs show some interesting features. The vertebral body (fig. 6) shows as a transversely oval patch with a small clear spot in the center, indicating the position of the notochord. The appearance of the body indicates the occurrence of ossification from bilateral centers or else from a center indicating a bilateral origin. The ossified part of the neural arch is still divided into its two halves, no fusion having yet occurred either with the bodies or dorsal to the spinal cord. The center in each half of the arch (fig. 5) is quite distinctly seen lying to the side of the body and on the thoracic vertebrae well marked transverse processes can also be seen. In the sacral region the centers for the neural arches are very insignificant and none are to be seen for the coccyx. The first three sacral vertebrae show a well marked center of ossification (fig. 6) on each side in the lateral mass. There are seven well marked cervical vertebrae, thirteen thoracic, five lumbar, five sacral and one coccygeal. The first sacral may be identified by the presence of the centers in its lateral masses, so that it is evident that the presacral vertebrae are twenty-five in number instead of the normal twenty-four. That the supernumary

vertebra is a thoracic one is assumed from the fact that there are the normal number of lumbars and cervicals, all typical of their region in appearance, and all free from ribs, while between these regions lie thirteen vertebrae, all of which bear ribs.

All the thirteen ribs (figs. 5 and 6) are well marked, though the first and the last are very short. It is unlikely that the rib at the upper end is cervical, or the lower one lumbar in origin in view of the fact that these regions have their full number of vertebrae without ribs.

The cause of the scoliosis mentioned previously is shown in the radiograph. The body of the third thoracic vertebra (fig. 6) is imperfect on the left of the mid-line. It shows ossification but is only half the size of the right half, and this center of ossification has remained separate from its fellow on the right side. The fourth body is slightly tilted up on the left to make up for the deficiency. The seventh thoracic vertebra on the left side of its body again exhibits the same deformity, with lack of fusion of the two centers of ossification in the body, and in this case the eighth, ninth, tenth and eleventh vertebrae, lying below it, are all tilted up to compensate for the deformity. Both defective vertebrae show good neural arches with well developed ribs articulating with them.

The only points in regard to the skeleton, which are not brought out by the radiographs, but become evident on dissection, are that eight costal cartilages articulate with the sternum, and that there are only two carpal bones. The carpal bones are not yet ossified, and so do not show in the radiographs. The proximal one is long and cylindrical, with a convex head proximally articulating with the lower end of the radius, and a concave facet distally for the other carpal. The second carpal is an irregular wedge, broad dorsally, narrow ventrally, with a proximal convex articulation for the other carpal, and a concavoconvex facet distally for the metacarpal. It is impossible to identify either of these bones with any one of the normal carpal bones, but they resemble the navicular and lesser multangular more closely than any others.

DISSECTION OF LEFT ARM

MUSCLES

In describing the muscular system in this limb frequent reference to variations and to comparative anatomy are made, where it would be tiresome to keep repeating the authority for such statements. In such cases it is to be considered that Le Double's book "Variations du Systeme Musculaire de l'Homme" has been followed.

Where no comments are offered regarding the variations of origin or insertion, or additional attachments of any muscle noted here, it is to be inferred that such departures from normal have been frequently noted before by others, and are not of great significance.

As is to be expected, there is little change and abnormality in the muscles belonging to the upper part of the limb, but great structural differences become increasingly evident as one proceeds distally.

MUSCLES FROM AXIAL SKELETON TO SHOULDER GIRDLE AND HUMERUS

All the following muscles are present and exhibit normal origins and insertions (figs. 7 to 10).

Sternocleidomastoid.
Subclavius.
Trapezius. Muscle fibers end at level of ninth thoracic vertebra, below this point there is only a thin aponeurosis.
Rhomboidei, minor et major.
Levator scapulae.
Serratus anterior.
Latissimus dorsi—with an accessory head from the lower angle of the scapula.
The two pectoral muscles exhibit some variations from the normal.

Pectoralis major (figs. 7 and 8, *P.Ma*)

Origin. Normal.

Insertion. Into the outer lip of the bicipital sulcus by a heavy sheet of tendon. From the deep surface of this tendon two ab-

normal accessory heads of origin of the biceps brachii are given off.

From the lower free edge of the muscle and from the main tendon there arises an aponeurotic strip which gradually narrows as it passes down the arm and forms a band arching over the biceps muscle and inserting into the medial epicondyle and the medial epicondylar ridge of the humerus. This band is the chondroepitrochlearis muscle, and is not an uncommon structure, being frequently found in the adult (8 times in 64 subjects, Le Double). It is much more frequent in females than in males. It is a normal part of the musculature of many of the lower animals, being known under various other names in cheiroptera, bears, foxes, Dasypus, Echidna, Batrachia and Cetacea, and is believed to be homologous with the tensor plicae alaris of birds (Le Double).

Pectoralis minor (fig. 8, *P.Mi*)

Origin. Statements differ in various textbooks as to the extent of origin of this muscle, some (e.g., Piersol) say the third to fifth ribs, others (e.g., Morris) include the second rib also. In this instance the more extensive origin occurs.

Insertion. The insertion is into the upper surface of the coracoid process and the outer part of the costocoracoid membrane is so intimately blended with this part of the muscle that I have debated whether or not to call it a second insertion into the middle third of the clavicle, an attachment which is occasionally exhibited. The lowest fibers are attached to the medial surface of the coracobrachialis muscle, an insertion which has been noted in other cases by Winslow (vide Le Double).

SHOULDER MUSCLES

The deltoid, supraspinatus, infraspinatus, teres minor, teres major, and subscapularis are all present, and normal in extent.

BRACHIAL MUSCLES

Coracobrachialis (fig. 8, *C*)

Origin. From the coracoid process, and capsule of the shoulder joint, by a common tendon with the short head of the biceps. The capsular origin is uncommon. The muscle in its upper part receives fibers from the pectoralis minor as mentioned above.

Insertion. Into the medial side of the humerus from the level of the lesser tuberosity almost down to the medial epicondyle. What are here present are thus all three divisions of the muscle, namely, superior, middle and inferior portions.

The superior portion here exhibited is rarely found in man though normal to some of the lower animals. The coracobrachialis superior, when present, inserts into the lesser tuberosity, surgical neck, and medial bicipital ridge of the humerus, also frequently into the capsule of the shoulder joint. It occurs only very rarely in the Anthropoidea but as a normal structure in the Quadrumana. It is also present in the elephant, giraffe, bear, cat, hyena, opossum, Echidna and several other animals.

The coracobrachialis medius is inserted into the middle portion of the humerus and forms the main mass of the normal human muscle, the remainder being constituted of the upper part of the coracobrachialis inferior. The medius is the only portion of the coracobrachialis present in the aye-aye, the bat, and the sloth, while it is absent in the kangaroo, otter, and seal.

The coracobrachialis inferior has an extremely variable insertion, extending in different cases from an attachment a couple of centimeters long on the shaft of the humerus below the medius, to an insertion on the inner edge of the whole lower half of the shaft of the bone and the inner epicondyle. In the latter case it bridges the supracondylar foramen in animals where this is present and so is perforated by the median nerve and brachial artery. This muscle is found in the cetacea, the hedgehog, the bear, great anteater and others. The inferior portion is much more developed here than is normal in man, but similar development has been frequently found before.

Between the upper and middle portions runs the musculocutaneous nerve, but there is no perforation of the lower part of the muscle by the brachial artery and median nerve, as occurs when the muscle extends as far as the medial epicondyle of the humerus. The medial edge of the upper third of the muscle is connected with the deep surface of the pectoralis major by a muscular band.

MUSCLES OF THE UPPER ARM

Biceps brachii (figs. 7 and 8, *Bi*)

Origin. The long head arises normally from the supraglenoid tubercle of the scapula. Its tendon is very thin and narrow.

The short head is fleshy and heavy, arising by a broad tendon from the coracoid process and the capsule of the shoulder joint, the muscle formed by this head overlapping that of the long head.

In addition to these two heads two accessory heads are present on the lateral side, arising from the deep surface of the tendon of the pectoralis major and joining the long head at the level of the bicipital groove. On the lateral surface of this united bundle comes in a tough short tendon from the deltoid tubercle and under the long head there is also a distinct bundle arising from the shaft of the humerus to join the long head. There are thus seven distinct origins for this muscle. All these abnormalities have been noted by Le Double though some of them are extremely rare.

Insertion. The greater part of the muscle passes into a tough cylindrical tendon passing to the bicipital tubercle on the radius.

This is a second tendon, however, passing from the superficial and medial aspect of the muscle, as a broad flat band with diverging crescentic edges. It is attached to the anterior surface of the medial epicondyle of the humerus, and to the shaft of the radius in front of and beyond the bicipital tubercle. Between these two points the inferior border of this aponeurosis

presents a free crescentic border under which are visible the other tendon of the biceps and the tendon of the brachialis muscle. There is some fusion of the deep fascia of the arm to the muscle at the beginning of this superficial tendon, which might be interpreted as a rudimentary semilunar fascia.

The attachment to the humerus must be extremely rare as it has not been noted by such an authority as Le Double and no explanation of such an attachment can be drawn from comparative anatomy. The only plausible theory to be entertained is that this is possibly an extremely well developed semilunar fascia which has obtained a bony attachment by following the intermuscular septa to the bones.

The median nerve passes on the superficial surface of this broad tendon while the brachial artery and vein pass deep to it, and also behind the round tendon.

The biceps muscle is responsible for the position of partial supination of the radius, though the hand is pronated. It is to be remembered that one action of the biceps normally is rotation of the radius to produce supination, accomplishing this by a forward pull on the bicipital tubercle which lies posterior to the long axis of the bone in pronation. In this case the radius has been rotated until the bicipital tubercle lies facing the anterior surface of the humerus. There are no muscles attached to the radius capable of opposing the biceps in this action and so the position of supination will be permanently retained.

THE BRACHIALIS MUSCLE

This muscle is divided longitudinally into two portions.

Medial portion (fig. 8, *Br.*)

Origin. Normal in extent from the lower half of the front of the shaft of the humerus.

Insertion. The muscle passes down on the humerus almost to the articulation with the radius. It is inserted along a continuous line on the back of the neck and head of the radius, the joint capsule and the medial epicondyle of the humerus dis-

tally and deep to that part of the biceps tendon inserted here, and deep to the origin of the muscles of the forearm.

This portion of the muscle is supplied by the musculocutaneous nerve, which is normal, as this portion of the muscle develops from the ventral musculature of the arm.

The insertion of the brachialis on the radius is to be expected here, as the ulna is absent, and because it is a frequent abnormality to have accessory insertion on the radius in addition to its ulnar insertion. Indeed, in addition to the ulnar insertion in some of the lower animals, such as the horse, the ruminants and the rodents, a radial attachment is normal and in a few species, such as the platypus the radial insertion is the only one found.

Lateral portion (figs. 7, 9 and 10, *Br.*)

This portion is so distinct from the medial portion as to be practically a separate muscle. It is also divided longitudinally into two completely separate bundles.

Origin. The two bundles of this muscle arises alongside of each other, following the lower half of the circumference of the deltoid tubercle.

Insertion. They pass down the arm as parallel fasciculi and are inserted on the lateral border of the radius in line with each other, the most lateral fasciculus being at least a third the distance down the shaft of the radius. This portion of the muscle is supplied by the radial nerve and represents the portion of the muscle developed from the dorsal musculature of the arm and has, in this instance, separated from the rest of the muscle formed from the ventral elements. The radial nerve normally supplies a small portion of the human brachialis muscle on the lateral side, thus indicating the normal composition of the muscle, which always has a small portion of the dorsal musculature included in it. Le Double cites cases where the brachialis muscle has been found divided into two distinct heads, as found in this case, either one of which may be subdivided again. He does not state the nerve supply, but it is probable the primary separation is between the dorsal and ventral elements of the muscle.

This lateral portion forms a sharp fold projecting between the humerus and radius and occupies the deeper portion of the skin web previously described as binding the arm in flexion at the elbow. This muscle is very tight and prevents all extension of the radius on the humerus. It is the muscle so placed as to most thoroughly prevent this movement, and the part responsible for this is the lateral portion, due to its insertions down the shaft of the radius. There is no opposition to this force as the triceps is not attached to the radius.

Although this muscle occupies only about half the projecting extent of the skin web here, it is probably the cause of the web, forcing the skin out in a sharp fold ahead of it. The fold has developed beyond the extent of the muscle later on.

The lateral portion of the brachialis is responsible for another displacement of the radius. As its insertion is far down on the shaft of the radius, and its pull is all to the one side, it has swung the radius around laterally until the long axis of this bone lies in a plane parallel instead of perpendicular to the line joining the two epicondyles of the humerus. This latter relation is not at first sight apparent, for the forearm appears to be ventral, not lateral to the upper arm. The reason for this is that the scapula, carrying the humerus with it is rotated through a right angle forward and inward on the flattened chest wall. The scapula has medial and lateral surfaces respectively, instead of ventral and dorsal. The humerus similarly has medial and lateral surfaces instead of ventral and dorsal, and the axis at the lower extremity passing through the epicondyles is not mediolateral in direction, but dorsoventral. The forearm thus lies in a dorsoventral plane although actually rotated laterally through a right angle.

Triceps brachii (figs. 9 and 10, T_1, T_2, T_3)

Origin. The long head is very large and arises from part of the axillary border of the scapula as well as the infraglenoid tubercle.

The lateral head arises from the upper third of the posterior surface of the shaft if the humerus above the groove for the

radial nerve, and is quite large. Its border blends with that of the long head throughout its extent.

The medial head lies on the back of the middle third of the humerus, below the groove for the radial nerve. It is overlapped largely by the long head and blends with the deep surface and medial border of the latter.

The lower two-thirds of the muscle exhibit a tendon running lengthwise, at the line of junction of the long and lateral heads. Towards this tendon fibers converge in the upper part muscle, and in the lower part they diverge again to their insertion on the bone.

Insertion. Owing to the absence of the ulna no normal insertion is possible, and the whole lower attachment of this muscle is transferred to the humerus. The insertion is into the whole of the lower third of the posterior surface of the shaft of the humerus and to the back of both epicondyles. The radius receives no attachment whatever from this muscle, so extension of the forearm is an impossibility. This explains the early fixation of the forearm in extreme flexion, allowing thus of the development of the skin web and shortening of the brachialis muscle to make this deformity a fixed one. Migration of the attachment of the brachialis down the shaft of the radius is thus permitted by the permanent flexion of the forearm. In this position the further the muscle passes down the radius the shorter it becomes, as its insertion approaches the level of its origin.

It might be asked why, in absence of the ulna the brachialis muscle becomes attached extensively to the radius but the triceps all ends on the humerus. Why does not the triceps also reach the radius? The difference seems reasonable in view of the following circumstances, comparative anatomy furnishing the answer to the problem. The brachialis is attached to the radius occasionally in man, and as before mentioned, normally in certain lower animals in addition to its ulnar insertion, while in a few species the radial insertion is the only one. In the case of the triceps, insertion on the radius is not normal in the

lower animals even where the ulna is of small importance in the forearm.

It is to be noted that although the two humeral heads of the triceps can produce no movement, as they both arise and insert on the humerus, yet they are both well developed muscle masses.

MUSCLES OF THE FOREARM

There has been great disturbance of the muscles in the forearm, due to the absence of the ulna and reduction of the hand, but it is still possible to homologise some of them with those of the normal type. The others however are difficult to define and the homologies given for them are more in the nature of probabilities than of definite facts. The extensors seem to be more reduced and more atypical than the flexors.

EXTENSORS

Mostly members of the superficial group are here present as all of the deep group with one exception are absent. There are four muscles to consider on this surface.

1. Brachioradialis muscle (figs. 9 and 10, *B.*)

Origin. High on the lateral epicondylar ridge of the humerus.

Insertion. A very short cylindrical muscle running across the bend of elbow to insert on the shaft of the radius at about its middle point, and just to the side of the insertion of the lateral portion of the brachialis muscle.

This muscle is probably the brachioradialis and its shortening is not extreme, having been noted in other cases, while in one of the anthropoids, the gibbon, its insertion is normally high up on the shaft of the radius.

2. Common superficial extensor mass (figs. 9 and 10, *C.E.M.*)

Origin. Lower part of lateral epicondylar ridge and outer surface of lateral epicondyle of the humerus.

Insertion. Runs directly parallel to radius and inserts at the middle of the shaft of that bone, just medial (owing to pronation apparently lateral) to the brachioradialis.

This muscle probably represents the undifferentiated remainder of the superficial extensor mass, except the extensor carpi ulnaris which is separate. It will thus include the extensors carpi radialis longus and brevis, digitorum communis and digiti quinti proprius. In some reptilia and amphibia these muscles are in a common supinato-extensor mass.

Why none of this mass reaches the carpus or digit cannot be explained, but the fact that none of it does so explains why the hand is carried in a position of permanent flexion, because there is a flexor muscle attached to the digit and it is thus without an opponent to its pull.

3. *Supinator* (figs. 8 and 10, *A.*)

Origin. Covered by the common extensor mass it comes from the anterior surface of the lateral condyle of the humerus. This represents the superficial or humeral portion only of the normal human muscle.

Insertion. It courses parallel and deep to the common extensor mass and is inserted into the capsule of the radio-humeral joint, head, neck and upper third of the shaft of the radius, right down to the insertion of the common extensor mass.

This muscle, it seems to me, is quite evidently the supinator, and so is the single representative here of the deep muscles of the extensor series in the forearm.

Extensor carpi ulnaris (figs. 7, 8, 9 and 10, *E.C.U.*)

Origin. Below the preceding muscle from the lowest part of the lateral epicondyle of the humerus. This is the last of the extensor group and lies in contact with the flexors. It is the longest of the extensors, being over double the length of any of the others.

Insertion. By a long slender tendon which is one-third the length of the muscle, into the middle of the dorsal surface at the

lower extremity of the radius and into the carpus. At the origin of the long tendon from the belly of the muscle there comes off also a very short tendon which courses obliquely toward the flexor surface of the radius and is inserted right alongside of and practically blended with a part of the flexor digitorum profundus, about three-quarters of the distance down the bone.

This muscle is named the extensor carpi ulnaris because of its superficial origin from the humerus and its insertion into the carpus, and because it is the most medial of the extensor muscles here found, and is in contact with the flexors. All the muscles inserting into the carpus also show attachment to the lower end of the radius, this attachment seeming to be due to a spreading out of the tendon at its insertion, and so I do not think the radial attachment here offers a serious obstacle to calling the muscle the extensor carpi ulnaris.

FLEXORS

This group of muscles exhibits members of both the superficial and deep layers and although badly disorganized it still retains a somewhat closer homology to the normal divisions of this group than is to be found in the extensors.

SUPERFICIAL GROUP

First layer

1. Flexor carpi radialis (figs. 7 and 8, *F.C.R.*)

Origin. By a broad fleshy head from the upper part of the medial epicondyle of the humerus.

Insertion. This muscle is fleshy in the upper half of the forearm and has a long thin tendon coursing through the lower half to be inserted into the lower end of the radius and into the carpus.

The position of this muscle is along the lateral border of the radius on its volar surface, although it appears to be dorsal due to the rotation of the bone.

From its attachments and position it can be quite safely identified as the flexor carpi radialis muscle.

2. Flexor carpi ulnaris (figs. 7 and 8, *F.C.U.*)

Origin. A broad, flat, fleshy origin from the front of the medial epicondyle of the humerus and from the surface of the bone in front of and below this.

Insertion. This muscle is by far the largest of all those yet described in the forearm. It is fleshy to about two-thirds the distance down the radius where it narrows into a heavy tendon which inserts at the lower end of the radius and into the carpus.

Second layer

3. Flexor digitorum sublimis (superficial portion) (fig. 8, *F.D.S.*)

Origin. Under the origin of the flexor carpi radialis as a thin flat fleshy muscle which courses obliquely to join one of the deep muscles arising on the radius, which will be described later.

This I would homologise with the flexor digitorum sublimis due to its position as the second layer of muscles from the medial humeral epicondyle. There is a possibility of this muscle being the humeral portion of the pronator radii teres. Against this latter view, are the facts that the muscle is entirely covered by the two carpal flexors, and that it is not inserted into the shaft of the radius but joins a muscle arising here to be inserted into the carpus.

DEEP MUSCLES

Third layer

4. Flexor digitorum profundus (figs. 7 and 8, *F.D.P.*)

Origin. A thick fleshy muscle arising from the lower two-thirds of the volar aspect of the radius on its lateral (apparently dorsal) portion.

Insertion. This muscle passes as a compact fleshy bundle as far as the metacarpal region where it condenses into its tendon which is single and runs on the volar aspect of the single digit

to be inserted into the terminal phalanx. In its course it passes under the digital portion of the median nerve which divides on the digit, allowing the tendon to pass out under it in a manner similar to that usually shown by the tendons of the flexor digitorum sublimis muscle.

The flexor pollicis longus muscle is apparently entirely absent or much more probably its muscle mass is indistinguishably fused with that of the flexor digitorum profundus, since the primitive condition of the deep flexors is a single muscle mass giving tendons to the thumb and other digits. Man is one of the very few mammals possessing a flexor pollicis longus muscle and McMurrich ('03) has shown that in the other mammals its absence is not due to a lack of the muscle but to the fact that it has not differentiated out from the common deep flexor mass to the digits. It is thus present as the most radial portion of the flexor digitorum profundus in these forms.

5. Flexor digitorum sublimis (Deep origin) (fig. 8, *F.D.S.*)

Origin. From middle third of volar aspect of radius just medial (apparently ventral) to flexor digitorum profundus.

Joining the proximal part of this muscle is the superficial origin described above.

Insertion. The common mass so formed passes into a slender tendon inserted at the lower end of the radius and beginning of the carpus.

The reason of the failure of the tendon of this muscle to reach the digit I think must be sought in the failure of the palmar aponeurosis to which it is attached, to differentiate into a tendon. McMurrich ('03) has shown that primitively the sublimis muscle ends at the wrist inserting into the palmar aponeurosis. Muscles developed in this aponeurosis later fuse end to end with the flexor sublimis thus producing its tendons in the mammalia. The palmar structures included in the sublimis have evidently failed to form here, leaving the sublimis to end at the wrist.

6. Flexor Digitorum Profundus (detached portion) (fig. 8, *F. D. P.*)

Origin. From the neck of the radius and the shaft of the bone near this on the medial (apparently ventral) border.

Insertion. This muscle is long and slender. As it is followed distally into its tendons it divides into a superficial and deep layer which insert separately. The superficial tendon passes down to the lower end of the radius and to the carpus. The short deeper tendon ends almost immediately on the shaft of the radius a short distance above the lower extremity, and is fused with the short deeper tendon of the extensor carpi ulnaris already described.

This muscle I interpret as the ulnar part of the flexor digitorum profundus, which has differentiated during the muscle development of the limb and become attached to the nearest part of the radius. The flexor digitorum sublimis by the extension of its deep, radial origin, comes between it and the radial portion of the profundus layer and so may have prevented their fusion. On the contrary if the lack of fusion was primary this would allow of the sublimis layer becoming attached down the radius between the two parts of the profundus. There is no possibility of this being the flexor pollicis longus as it lies medial and not lateral to the rest of the flexor digitorum profundus.

Fourth layer

7. Pronator quadratus

A thin film of transversely disposed muscle fibers lying over the lower end of the radius represents the pronator quadratus muscle. It is very poorly developed and small in extent.

It is to be noted that by means of the muscle in the forearm voluntary flexion of the digit is possible but voluntary and active extension is impossible, as all extensors fail to reach the finger. A singular and interesting parallel to this case is found in a case cited by Schultze ('04). In a training school he observed a nineteen year old lad who had only one digit on each of all four limbs. Voluntary flexion of these digits was easily accomplished but he

had no power of extension. The probable explanation is that there was a condition such as present in the case I have dissected. The fact that in both these cases the flexors are evidently better developed than the extensors is significant and seems to point to certain definite conditions in the muscles being associated with the deformity.

MUSCLES OF THE HAND (figs. 7 and 8, *L.*)

Only one muscle is present here. It is a lumbrical, arising in the metacarpal region from the lateral side of the flexor digitorum profundus as this latter muscle passes into its tendon. The lumbrical passes in a spiral direction distally and laterally on to the dorsal surface of the digit where it inserts into the dense fibrous tissue over the phalanges.

NERVES OF THE LEFT ARM

The whole brachial plexus was dissected out as shown in figure 8 and conformed in all its arrangement and branches to the typical formation. Therefore it is only necessary to describe the course and distribution of its main terminal branches.

From the posterior cord

1: Axillary nerve. Normal course and distribution to skin, deltoid and teres minor muscle, and to shoulder joint (figs. 8 and 10, *A. N*).

2. Radial nerve. Runs ventral to the latissimus dorsi tendon, then winds behind the humerus (figs. 8 and 10, *R. N*) in the musculospiral groove, here giving branches to the three heads of the triceps muscle, and then enters the space between the triceps and postaxial portion of the brachialis muscle, where it supplies this part of the brachialis and gives off the dorsal antibrachial cutaneous nerve.

A short distance further on the nerve divides into

a. The superficial radial (figs. 9 and 10, *S. R. N*) which runs a cutaneous course on the lateral side of the whole length of the forearm and hand.

b. The deep radial nerve, which lies under the three superficial extensor muscles (fig. 10) and on the surface of the supinator which is covered in by the others. The nerve supplies all these muscles.

From the lateral cord

3. Musculocutaneous nerve. Supplies the coracobrachialis muscle and penetrates it (fig. 8, *Mc. N.*) between its upper and middle portions to pass between the biceps and the preaxial portion of the brachialis, supplying both the latter muscles and ending cutaneously in the forearm.

4. Outer head of the median nerve. The median nerve is described under the inner cord.

From the inner cord

5. Inner head of the median nerve. Unites with the lateral head over the axillary artery.

The median nerve (fig. 8, *M. N.*) courses ventral and medial to the axillary and brachial arteries in the groove medial to the biceps muscle. It enters the forearm deep to the flexor carpi radialis and superficial head of the flexor digitorum sublimis, and in front of the biceps tendon and is accompanied by the medial vena comes of the brachial artery, while the artery and the lateral vein lie under the two biceps tendons. As it passes the elbow, it gives branches to the flexor carpi radialis, flexor digitorum sublimis and flexor carpi ulnaris and then divides into a superficial and a deep branch.

The deep branch evidently is the volar interosseous nerve of the normal arm, and it supplies the three deep muscles arising on the shaft of the radius.

The superficial branch of the median nerve (figs. 7 and 8, *M. N.*) comes immediately from under cover of the flexor carpi radialis and courses subcutaneously down the ventral surface of the lower two-thirds of the forearm and over the carpus. In the distal third of the forearm it gives off a large cutaneous branch on the medial side.

At the carpus a strong cutaneous branch is given off on each side and on the lateral side also a muscular twig to the lumbrical muscle. The rest of the nerve runs on the ventral surface of the single digit, finally forking to each side of the digit about the level of the second phalanx to let the underlying flexor digitorum profundus tendon pass through it. This nerve was at first mistaken for the tendon of the flexor digitorum sublimis muscle, so typical in appearance was it to this latter structure, when only its course in the forearm and hand was uncovered.

6. Ulnar nerve. Runs down the arm under the deep fascia (figs. 7 and 8, *U. N.*) in company with the basilic vein, pierces the deep fascia a little above the elbow, and divides into two branches, a volar and a dorsal, both running subcutaneously on the medial border of the forearm.

No muscular branches whatever were found on this nerve, its whole distribution being as a sensory nerve to the forearm.

All other nerves of the brachial plexus which are not specially described here are normal in their extent and distribution.

VESSELS OF THE ARM

The vessels of the arm were not dissected above the axilla as it did not seem that any noteworthy changes from the normal would be likely to occur. No injection was employed as it was feared that if a vessel wall ruptured structures around the break might be so stained as to obscure valuable results. Small vessels were thus hard to follow, and arteries to the hand could not be identified.

ARTERIES (figs. 8 and 10)

The *axillary* artery and all its branches were normal in extent and position.

The *brachial* artery lay in the groove medial to the biceps muscle, with the median nerve on its medial side throughout its course, so that there is no crossing of nerve and artery.

The brachial artery gave origin to numerous muscular branches and also to three larger branches, the profunda brachii, coursing

with the radial nerve through the musculospiral groove, and the superior and the inferior ulnar collaterals, running medially alongside the ulnar nerve.

At the elbow the brachial artery (fig. 8) took the astonishing course of passing behind both the biceps tendons and lying on the surface of the brachialis muscle. Just beyond this point the artery bifurcated into two branches which passed down the arm, one on each side of the flexor digitorum sublimis. The lateral branch, the *radial* artery, lay under the flexor carpi radialis muscle, while the medial, the *ulnar* artery lay under the flexor carpi ulnaris. Both arteries became lost in the dissection before the wrist and hand were reached.

VEINS

Superficial veins (figs. 7 and 9)

The *cephalic* vein (*C. V.*) is present here, starting in the hand and running on the lateral (apparently dorsal) border of the dorsal surface of the forearm, across the skin web at the elbow, up the lateral side of the arm, dividing into two channels. These turn ventrally below the insertion of the deltoid, reuniting here, then pass between the deltoid and pectoralis major muscles to terminate deeply in the thoracoacromial vein.

The *basilic* vein (*B. V.*) starts also at the wrist, and runs up on the medial border of the dorsal surface, turning medially to the ventral surface just above the medial epicondyle of the humerus. Here it passes under the deep fascia of the arm, running in the groove medial to the biceps as far up as the axilla where it unites with the common trunk formed by the union of the brachial venae comites to form the axillary vein.

Across the back of the elbow a large vein connects the basilic and cephalic veins transversely.

The *median* vein (*M. V.*) courses up the middle of the ventral surface of the forearm as far as the bend of the elbow where it divides into two large branches, the median basilic and median cephalic.

The *median cephalic* (*M. C. V.*) runs vertically upward on the ventral surface of the postaxial part of the brachialis, receiving as it goes the deep cubital vein from the cubital fossa. The median cephalic joins the lower half of the cephalic and the common trunk joins the upper half of the cephalic.

The *median basilic* runs (*M. B. V.*) back over the medial epicondyle of the humerus then turns up to join the basilic. It is double in most of its course.

Deep veins (*fig. 8*)

The *radia* and *ulnar* veins coursing alongside the corresponding arteries unite to form the vena comes lying medial to the brachial artery, and passing behind the biceps tendons.

Another vein runs back alongside the median nerve in front of the biceps tendons and half way from the elbow to the axilla the brachial vein leaves the side of the artery, crosses in front of the median nerve, and unites with the vein accompanying the nerve. This common trunk ascends to the axilla and unites with the basilic to form the axillary.

The *axillary* vein lies medial and deep to the ulnar nerve and medial cord of the brachial plexus and receives the usual normal tributaries.

EMBRYOLOGICAL AND GENERAL CONSIDERATIONS

The first questions that naturally arise in connection with this case are as to the causative agent and time of production of the monstrous condition here exhibited. There are several different possibilities to be considered and as the time and the cause are closely related they will be taken up together.

This deformity may be hereditary and so transmitted in the germ cells. In the case referred to previously, which was described by Schultze ('04), there was only one digit on each hand and foot and this same identical condition was found in the mother and the mother's father, while a brother had monodactylous hands, and other deformities of the feet. It is a well known fact that monstrosities affecting the limbs show more

tendency to be hereditary than many other kinds. Adami ('08) gives certain good examples of hereditary transmission of such deformities. There is, however, in the case studied here no evidence that heredity plays any part in the production of the abnormality and the cause must be sought for elsewhere.

Again it is possible for a monstrosity to be produced by deficiency in either germ cell, which will produce a deficient fertilized ovum. A normal fertilized ovum may also be injured and Conklin ('05) has shown that even in the ovum there is a differentiation and specific localization of organ forming substances, one of which could be damaged thus leading to the production of abnormal embryos and monstrosities. This has been done by many workers, only one or two of whom, such as Werber ('15) and Stockard ('09–10) need be mentioned. In this case, however, damage to either of the germ cells and also to the fertilized ovum is improbable as there is no history of either of the parents suffering from venereal disease, alcoholism or drug habits and neither of them work in noxious surroundings where poisoning would be possible with lead, arsenic, phosphorus or other agents.

The period of the production of this deformity is thus excluded from the germinal stage and must be either in the embryonic or foetal stages. The foetal stage also can be excluded, for as pointed out by Ballantyne ('04) in his excellent book on antenatal pathology, foetal physiology is, if not identical, at least similar and parallel to that of the individual after birth, and thus, foetal pathology is mainly concerned with disease and disordered metabolism. On the other hand the embryonic period is a period whose physiology is not that of functional activity of organs, but of organ formation and differentiation. Pathological conditions in the embryonic period, therefore, lead to malformations and so if severe to the production of monsters. The deformity in this case is thus limited in its production to a period between the first and seventh weeks of intra uterine life. During this period the limb buds appear and bones and muscles differentiate in them.

Schwalbe ('06) has pointed out that there is a definite termination period for the production of any deformity. Before the end of this period practically all deformities of that particular type must appear, and any produced later than this are to be regarded in the light of accidental occurrences injuring originally perfect parts and so simulating abnormalities produced as errors of development before this termination period. The termination period in each case marks that special time in which organogenesis ceases and functional activity begins in any particular organ or part and marks the limit in time beyond which a given deformity rarely if ever has its origin. This reckoning also places the latest period for the production of the limb deformity in this case at the seventh or eighth week, when the limb is fully differentiated and ossification in the limb skeleton begins.

Mall ('08) after a critical study of one hundred and sixty-three pathological embryos, has concluded that most monsters are produced by the faulty development of normal ova due to external influences, usually a vice of nutrition due to faulty implantation which in turn is generally due to an abnormal condition of the uterine mucosa. Such a condition for instance would be a mild, chronic endometritis which would not prevent the occurrence of a pregnancy but would be enough to cause faulty development. This might well be the cause here, as there is in this case a history of two miscarriages previous to the birth of this monster, without any apparent toxic agent or disease leading to their production, thus giving presumptive evidence of an abnormal condition of the uterus, which would cause faulty implantation and eventual death and expulsion of the products of conception.

Mall has estimated from statistics from various sources that in 100,000 pregnancies there are 80,572 normal births, 11,765 abortions of normal embryos, 7048 abortions of abnormal embryos and early monsters, and 615 monsters born at term. In view of the great prevalence of uterine disorders, superadded to the unsuitable conditions in which many pregnancies occur, the pathological development of approximately 7.5 per cent does not appear unduly high. It will be noted that one monster is

born at term in approximately every one hundred and thirty births.

For a full discussion of the many teratological theories the reader is referred to Ballantyne's text book on antenatal pathology. It is sufficient to mention briefly any other likely causes of the present deformity. Maternal impressions still possess many firm believers, but I think as a cause their utter powerlessness in this case is clearly demonstrated. The impressions were received later in pregnancy, the deformity, as shown above, must have been established very early, so the relation of the two as cause and effect was absolutely impossible. (See page 387).

Foetal diseases do not appear as a rational cause of this deformed condition and neither do amniotic diseases. Amniotic bands and adhesions have been ascribed almost universal teratological influences by devotees of this theory, and when they could not be demonstrated, their previous existence and later disappearance has been postulated. There is no cicatrix or other evidence of any band connected to the extremities here, and the symmetry of the deformity argues against its production thus. The accompanying defects in the vertebral column are evidently not due to such bands.

There is one cause in the production of monstrosities and of pathological embryos that it seems to me is perhaps a fruitful one and which I have not found mentioned by other authors. I refer to attempts in the production of criminal abortion, which as every physician knows, are so prevalent amongst the women of this age. These attempts are not always immediately successful but sometimes the pregnancy is terminated by the death of the injured child at some later date and in some cases pregnancy goes on to full term in spite of the injury. Is it not extremely possible that in these instances where the child continues to live for some time after the attempt to destroy it, that it should exhibit some monstrous condition, especially when the attempt is made in the first two months? Both the use of mechanical means and of drugs would result in these pathological conditions, the instrument by direct injury to the child or to the amnion, the drugs by affecting the implantation in the

uterus, and so being one cause of the condition to which Mall ascribes most pathological embryos. To show that attempts at abortion form a cause not to be neglected in this regard I quote from the Secretary of the Indiana State Board of Health, Dr. J. N. Hurty ('17) who says "It has been estimated that about one-third of pregnancies end in induced abortions, that at least 200,000 volitional abortions occur every year in the United States and that not less than 12,000 women die annually from the direct effects thereof." (This is quoted from another article as I regret I have been unable to obtain the journal with Dr. Hurty's original article in it.) Surely the arguments I have used above are sound in view of such conditions as Hurty states to exist and attempted abortions which are not immediately successful ought to be ranked amongst the causes of pathological embryos and monstrosities.

Some of the abnormal conditions found in this foetus can be correlated with interesting embryological stages of growth which it seems to me throw considerable light on what are otherwise obscure isolated facts. Statements as to normal skeletal and muscular development are taken from the accounts by Bardeen and Lewis in Keibel and Mall's Human Embryology ('10).

In the early development of the vertebra, as the scleroblastema becomes chondrified, this process in the bodies of the vertebrae is brought about by two centers, one on each side of the notochord. At first there is no fusion of these two centers of chondrification dorsally or ventrally around the notochord, as there is present in the mid line a membranous perichordal septum (Keibel and Mall). Normally this septum is soon broken through both dorsally and ventrally and the notochord is completely surrounded by cartilage by about the fifth or sixth week.

Ossification then occurs from a center which is usually single, but may divide or even arise paired.

The early presence of the perichordal septum appears significant in view of the fact that in this foetus are found two vertebrae with divided bodies, each half growing independently, and one-half growing less rapidly than normal. This septum was present at the period of embryonic life when that vice of develop-

ment occurred which produced the monstrosity of the limbs. Is it not very probable that the chondrification process in these two abnormal vertebrae was hindered so that the perichordal septum was not broken down, but remained intact, thus producing a vertebra with a divided body?

Ossification as mentioned above tends to occur in the body from one center, which may be divided. Under such conditions, with the perichordal septum intact it is possible that more of the ossifying center should be in one half than the other, thus accounting for the unequal rate of growth in the two separated halves.

There are some other points of interest in the vertebral column. The lateral masses of the sacral vertebrae ossify as follows: the first at the fifth month of intrauterine life, the second at the sixth month, the third at the seventh month, the fourth and fifth after birth about three months. In this foetus, the age was given as seven months and the third lateral mass center is just appearing, thus showing a normal rate of growth.

The first coccygeal vertebra in this foetus has a center of ossification in its body, while normally it appears in the first year after birth, so in this region there is an actual acceleration of ossification, in direct opposition to the retardation or suppression shown in the abnormal portions of the skeleton.

The core of the limbs at the third week is filled with vascular mesenchyme which at the fourth week becomes a scleroblastemal condensation which then becomes successively chondrified and ossified. The primary failure of the digits and ulna of this foetus can thus be placed as far back at least as the fourth or fifth week of development, at the time when the differentiation of the skeletal parts should have occurred. This would correspond with the time of production of the defect in the abnormal vertebrae. These facts would seem to indicate that at this particular period was exerted the strongest and most active influence of the agent producing the deformities.

Absence of the ulna is a much rarer condition in the forearm than absence of the radius. Kümmel ('95) has collected a series of cases of defect in the bones of the forearm. Unfortunately

I could not secure the journal containing his original article but Ballantyne ('04) in his text book and Schenk ('07) in an article on a case of defect of the ulna agree in their accounts of Kümmel's cases which can be taken as correct. He found 80 instances of defect in the bones of the forearm of which 67 were of the radius, 13 of the ulna. In the case of the ulna it was defective in 5, totally absent in 8 instances. In some of these cases there was associated absence of the ulnar side of the carpus and one or more fingers on the ulnar side of the hand.

The muscles of the limb definitely appear first proximally and differentiation proceeds distally. It might be expected that the muscles of the shoulder girdle and upper arm, being the first to appear after the skeletal deformities were produced, might show some anomalies. They do exhibit anomalies, but peculiarly not anomalies of defect, but of excess, such as supernumary heads and increased insertions. Of course, in the forearm and hand grave defects are associated with the loss of the skeletal structures.

The question naturally arises as to whether the muscle anomalies are a consequence of the skeletal defects or were independently produced by the same vice of development or nutrition to which the absence of the bones is due. In this connection it is to be noted that the suppression of muscles in the forearm is not confined to the ulnar border of the arm but affects also the radial side, so that more than mere absence of the skeleton underlies the anomalies. This can be proved by the fact that muscle is independent and self-differentiating. Muscles develop independently of functional activity as shown here by the two humeral heads of the triceps, inserted also on the humerus, incapable of movement, yet well developed. Harrison ('04) also proved that muscles develop independently of the nervous system, for he removed the spinal cord in early frog embryos, before the muscles had differentiated or received any nervous connection and yet the normal process of muscle development and grouping occurred. This power of self-differentiation goes right back to the ovum where Conklin ('05) has

demonstrated the presence of a myoplasm or muscle forming substance.

In the forearm the extensor and supinator group differentiate before the flexor and pronator set. As the muscle formation follows closely upon the definition of the skeleton, if the growth suppressing influence which acted on the skeleton lasted long enough to influence the muscles it is to be expected that the extensor group would exhibit the greatest amount of damage. Such is actually the case. Only four extensor muscles are present as against seven flexors and pronators plus one palmar muscle. Only one extensor muscle reaches as far as the lower end of the radius, nearly all the flexors reach that level. No extensor tendon reaches the digit, a flexor tendon passes right out to the terminal phalanx, in addition to bearing a lumbrical muscle to the digit. It is to be noted that in the members of the extensor group here present the muscle masses are of about normal proportion, covering half of the length of the radius but in only one case is a long tendon developed, the other muscles inserting at once on the middle of the shaft of the radius. This failure of the long tendons to differentiate out after the appearance of these muscles is a further example of the greater suppression of growth in this region. Gräfenberg ('11) describes the musculature in a case of absence of the radius and the thumb. Here the radial musculature is present as a common mass high up in the forearm, possessing no tendons, and so appearing very much like the extensor muscles I have described. The other muscles both flexors and extensors, in Gräfenberg's case are present and normal in extent.

Regarding the muscle that I have called the common superficial extensor mass, as separation into separate portions begins at the carpus after the appearance of the tendons, it is not possible here to have such a division into its component muscles, because its tendon is entirely absent.

Absence of the thumb is not enough to cause disappearance of the abductor pollicis longus and extensor pollicis brevis, the radial members of the deep extensors, for there is still opportunity for the muscles to develop over the radius. The triceps

did not fail when the ulna disappeared. The same is true of the ulnar members of this group, the extensor pollicis longus, and extensor indicis proprius. All this group have been obliterated by a specific suppressing agent during myogenesis.

In the flexor muscles it seems strange that the pronator teres is not present when so many of the other muscles are. Its complete absence has never been noted as an anomaly although its coronoid head has often been lacking. In lower vertebrates this muscle is a part of a common muscular layer known as the pronatoflexor mass. In this foetus it may be present in the superficial layer, included with the mass of the flexor carpi radialis, having failed to obtain an insertion at the usual level on the radius.

It is interesting to note that in this foetus a definite tendency in one direction is shown by all muscles, which are properly developed and which show anomalies. This tendency, for instance is shown by all the muscles on the front of the upper arm and is a regression or atavistic change, the anomalies resembling normal muscles of the lower animals. Changes due wholly to loss of normal skeletal parts lead to anomalous attachments which of course cannot be properly included in this class as they are in the nature of monstrosities.

The question naturally arises as to what single digit it is that has persisted in this hand, and also what carpal bones are present.

It may be taken as a plausible working hypothesis that with loss of the ulna would be associated loss of the ulnar side of the carpus, with the fourth and fifth digits.

This hypothesis is supported by the fact that the main cutaneous digital nerves ventrally are two strong branches from the median while dorsally the radial reaches the base of the digit. The ulnar nerve has no digital distribution, and as it normally goes to the fourth and fifth digits while the median and radial supply the other three, the digit here present certainly ought to be one of the three on the radial side of the hand.

This would leave three digits still to decide between. This number can be further reduced to two as the thumb is certainly absent, for the persistent digit has a metacarpal and three pha-

langes, and a lumbrical muscle is also found attached to it. The median nerve normally supplies the lumbrical muscle to the second and third digits, the ulnar those to the fourth and fifth. The single lumbrical here present is supplied by the median, a further proof that the digit is the second or third.

The digit is thus either the index or middle finger, but to decide upon which of these two it is, is much more difficult as there is nothing in the disposition of the muscles to help solve the problem. The distribution of the cutaneous branches of the median nerve seem to offer the only key to the solution. In text figures C and D is given side by side the cutaneous distribution of the median nerve in this foetus and in the normal hand. As the cutaneous distribution of the median is wholly digital it is assumed that branches found from the trunk of the median running into the hand were intended for those digits which did not appear. By checking these off against the branches in the normal hand it is found that the digit here present ought to be the index finger.

There is a palmar cutaneous branch from the median arising in the lower half of the forearm and ending in the palm. It is not to be mistaken here for one of the digital nerves, these latter arising in the palm. There are three such nerves, only the middle one passing out on the digit, where it forks to supply each border, while the flexor profundus tendon passes on under it. The other two nerves end at the base of the digit on its medial and lateral borders. To save a long description the reader is referred to the figure explaining the distribution of these nerves. Here at a glance it can be seen that the part of the nerve found on the digit in this foetus, is the portion to the index finger from the first and second common volar digital branches. From this distribution it seems fairly definite that the sole remaining digit on this hand is the index finger.

On the arm which was not dissected it will be remembered that in addition to the single finger carried at the end of the limb there was a well developed digit found on the medial side of the elbow. Radiographs showed this to contain a metacarpal and three phalanges. Of course, this digit can be logically as-

sumed to be one of the ulnar members which has differentiated in spite of the total suppression of the ulna and part of the carpus. Its appearance at the elbow and not the carpal region lends color to the view that the ulnar anlage of the limb skeleton never appeared at all even in the early mesenchyme, so that

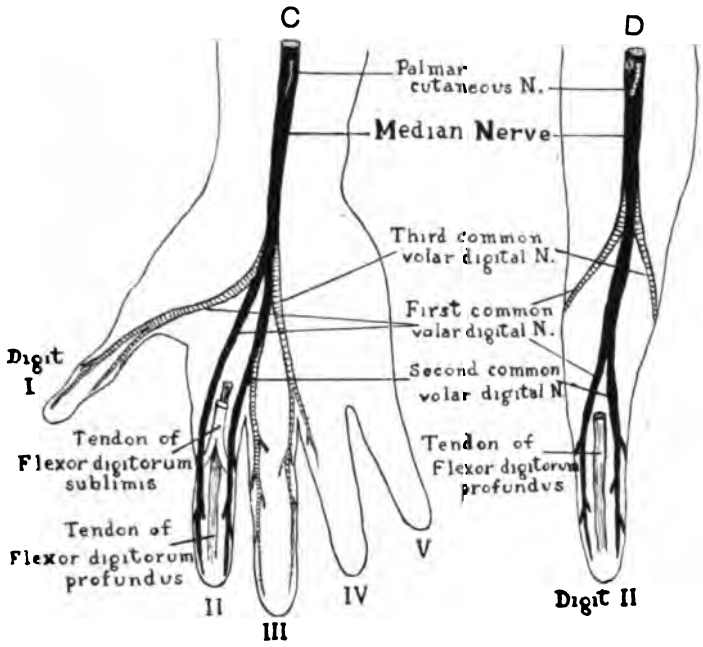

Text fig. C Outline of the cutaneous distribution of the median nerve in the normal human hand.

Text fig. D Outline of the cutaneous distribution of the median nerve in the left hand of this monodactylous foetus.

The part of the nerve shown in solid black in the two figures, is reckoned as identical in the two hands, and is used to determine what single digit is present in the foetus.

the primary reason for nonappearance of the ulna was not a lack of chondrification and ossification.

There is another view in regard to this digit, and that is that the digit is really the representative of all five normal ones, being the result of development of the original undivided digital

anlage in the earliest stage of the limb skeleton as the distal end of the condensed scleroblastemal core.

In view of the facts already expounded it seems to me that this latter view is not likely to be correct. The ulnar nerve ought to have a digital cutaneous distribution if the ulnar fingers of the hand are represented in this common finger, but the ulnar does not pass out on the digit, thus supplying one argument against this hypothesis.

The presence of one digit at the elbow joint on the right arm postulates the separation of one digital rudiment from the common mass. If it separated then clearly the tendency to division of the skeleton of the hand into rays was present and it is just as tenable to suppose that the five-rayed condition of the hand was provided for, but growth suppressed in four, as it is to suppose all five rays of one hand and four in the other to be included in a common mass.

The fingers here present, both in the hand and at the elbow, as will be seen from the table of measurements, are normal in size for a single digit. The development of an undivided common digital mass might be expected to produce a condition of macrodactyly, which is not found here. Considering all the facts, the view that the digit as found on the hand here represents only one of the five of the normal hand seems to be the correct view in this case.

What carpals are present is not capable of definite answer. There are only two present, a proximal one articulating with the radius and bearing beyond it a distal one which carries the digit. These two in their shape as previously described resemble the navicular and lesser multangular more than any of the other carpals. Their absolute identification, however, as these two, is hardly to be warranted from these facts alone. If it be true that these are the two carpals present it adds another proof for the digit being the index finger as these two particular carpals are in the direct line of the radius and the second digit.

In the mechanism of the production of the deformity in the limb several different conditions have to be considered. First, in the early limb bud the ulnar segments may not have been

carried out in the distal part of the evagination from the trunk of the body, being drawn out later only in the proximal part of the limb, so that a complete upper arm is formed but only the radial half of the rest of the limb. Secondly, these segments may have been drawn out, the limb bud being normal, but further differentiation not occurring, so that what is seen in the limb represents a fused radius and ulna in the forearm, fused carpals and digits in the hand. The arguments against the digit really representing all five have already been reviewed, and against the view of the ulna being included in the forearm is the absolutely typical shape and size of the radius, the distribution of nerves and muscles, and the appearance on the right arm of a digit at the elbow, as if this point represented the distal end of the ulnar portion of the arm. Thirdly, the limb bud again may have been normal, without fusion of the radial and ulnar anlagen in the skeleton, only the radial half going on with its development, the ulnar half failing entirely, except for the digit at the right elbow. The presence of this digit lends color to this third view.

DIAPHRAGMATIC HERNIA

After the rest of this paper was written, out of curiosity aroused by the flatness of the abdomen, I opened the body cavity to examine the viscera, and was surprised to discover a diaphragmatic hernia with a large proportion of the abdominal viscera situated in the left pleural cavity. The right half of the diaphragm was intact and perfect, but the left half was almost entirely absent. The sternal and vertebral regions were present and joined in the central tendon, forming a free edge to the diaphragm in the midsagittal plane. The left costal origin was indicated in front by a muscular ridge 2 to 3 mm. high following the costal margin as far back as the axillary line and the whole of the left half of the diaphragm except this narrow peripheral band was absent, leaving a wide open communication between the pleural and peritoneal cavities. The left mediastinal pleura passed over the medial free edge of the opening to become diaphragmatic peritoneum under the right half of the diaphragm,

the costal pleura passed on down as parietal peritoneum on the abdominal wall.

The hernia is thus of the variety known as hernia diaphragmatica spuria. Cases of hernia diaphragmatica vera have a hernial sac formed of diaphragmatic peritoneum and pleura invaginated into the pleural sac, so that the abdominal viscera are not in reality in the pleural sac. In this case however, there is no hernial sac, but a complete hole through the diaphragm and its coverings. The genesis of this condition I would interpret as a persistence of the embryonic pleuroperitoneal passage, the original communication between the pleural and peritoneal cavities, which has not been shut off, due to the failure of the septum transversum to grow back on this side. The left side normally closes a little later than the right (Keibel and Mall, '10) and this may be one factor in the greater prevalence of hernias on the left side.

This defect in the diaphragm must have had its origin during the development of the structure, and so occurred between the fourth and eighth weeks of intrauterine life, probably, on account of its size, in the first half of this period, say the fifth week, which synchronises exactly with the production of the defects in the limbs and vertebral column.

The heart has been pushed over entirely to the right side by the other viscera, but apart from its position is quite normal. The left lung shows two lobes, but is extremely small and flattened against the mediastinal wall just above the heart. The abdominal viscera are all fairly normal in relation to each other and seem to have been rotated en masse up and over toward the right. The left lobe of the liver is thus vertical, and against the mediastinal wall. The oesophagus comes from behind the upper end of the heart into the stomach and the latter is vertical, the pylorus being in the abdomen. The duodenum lies over the vertebral column and the small intestine runs from it into the pleural cavity, successive coils being piled continuously above the previous loops up to the apex of the cavity, where the gut is reflected down medially. Opposite the lung occurs the junction with the caecum and appendix. The colon descends

as far as the duodenum, then turns suddenly back on itself and ascends in the great omentum against the stomach to its upper end, then turns sharply down on the body wall, loses its mesentery and runs on the wall to the brim of the pelvis, where it turns suddenly into a large loop extending up again as high as the liver before turning to come down into the rectum.

Diaphragmatic hernia seems to be a fairly common condition as Ballantyne ('04) collected one hundred cases in the literature from 1888 to 1900. It is a peculiar coincidence, that in one of those cases, just as in this present one, there was also absence of the ulna. This is all the more interesting because Ballantyne states that associated malformations occur less frequently in conjunction with ulnar defects than with defects of other bones in the limbs.

In bringing this study to a close I wish to very cordially thank Prof. J. Playfair McMurrich for providing the material for the work and also for his valuable, kindly criticism of this paper during its preparation.

May 1st, 1917.

BIBLIOGRAPHY

ADAMI, J. G. 1908 The Principles of Pathology, vol. 1. Lea and Febiger, Philadelphia and New York, 1908.

BALLANTYNE, J. W. 1904 Manual of Antenatal Pathology and Hygiene, vol. 1. The Foetus; vol. 2. The Embryo. Green, Edinburgh, 1904.

BARABO 1900 Eine Missbildung. Offic. Protok. der Nürnberger Med. Ges. und Polikl. Munch. Med. Wochensch, 1900, S. 713.

CONKLIN, E. G. 1905 Organ-forming substances in the eggs of Ascidians. Biological Bulletin, vol. 8, p. 205.

GRÄFENBERG, E. 1911 Die Muskulatur in Extremitätenmissbildungen Anat. Hefte, Bd. 42, S. 195–250.

HARRISON, R. G. 1904 An experimental study of the relation of the nervous system to the developing musculature in the embryo of the pig. Am. Jour. Anat., vol. 3.

HURTY, J. N. 1917 Indianapolis Medical Journal, January.

KEIBEL, F., AND MALL, F. P. 1910 Manual of Human Embryology, vols. I and II. Lippincott, Philadelphia and London, 1910.

KÜMMEL, E. 1895 Die Missbildungen der Extremitäten durch Defect, Verwachsung und Uberzahl. Biblioth. Med., Abt. E., Heft 3.

LE DOUBLE, A. F. 1897 Traité des Variations du Système Musculaire de l'Homme. Schleicher, Paris 1897.

MALL, F. S. 1908 A study of the causes underlying the origin of human monsters. Jour. Morph., vol. 19.

MCMURRICH, J. P. 1903 The phylogeny of the forearm flexors. Am. Jour. Anat., vol. 2.

1915 The development of the Human Body, Fifth Edition. Blakiston, Philadelphia.

SCHENK, E. 1907 Ueber zwei Fälle typischer Extremitäten Missbildungen (Ulnadefekt, Fibuladefekt). Frankfurter Zeitsch. fur Pathol., Bd. 1, H. 3 und 4, S. 544–62.

SCHULTZE, E. 1904 Familiäre Symmetrische Monodactylie. Neurol. Centralblatt, S. 704.

SCHWALBE, E. 1906 Ueber Extremitätenmissbildungen (Spalthand, Spaltfuss, Syndaktylie, Adactylie, Polydactylie.) Munch. Med. Wochensch., S. 493.

1906 Die Morphology der Missbildungen des Menschen und der Tiere, T. 1 und 2. Fischer, Jena, 1906–7.

STOCKARD, C. R. 1909 The development of artificially produced Cyclopean fish—"The Magnesium Embryo." Jour. Exp. Zoöl., vol. 6.

1910 The influence of alcohol and other anaesthetics on embryonic development. Am. Jour. Anat., vol. 10.

WERBER, E. I. 1915 Is defective and monstrous development due to parental metabolic toxaemia. Abstract in Anat. Rec., vol. 9, p. 133.

1915 Experimental studies aiming at the control of defective and monstrous development. A survey of recorded monstrosities with special attention to the ophthalmic defects. Anat. Rec., vol. 9, p. 529.

Standard recent textbooks of Human Anatomy.

ABBREVIATIONS

A, supinator muscle
A.A., axillary artery
Ac, acromion process
A.N., axillary nerve
A.T.N., lateral and medial anterior thoracic nerves
A.V., axillary vein
B, brachioradialis muscle
B.A., brachial artery
Bi, biceps muscle
Br, brachialis muscle
B.V., basilic vein
C, coracobrachialis muscle
C.E.M., common superficial extensor muscle mass
Ch, chondroepitrochlearis muscle
Cl, clavicle
Cu.V., cubital vein
C.V., cephalic vein
D, deltoid muscle
Dx, cut edge of deltoid muscle
E, lateral epicondyle of humerus
E.C.U., extensor carpi ulnaris muscle
F.C.R., flexor carpi radialis muscle
F.C.U., flexor carpi ulnaris muscle
F.D.P., flexor digitorum profundus muscle
F.D.S., flexor digitorum sublimis muscle
H, head of humerus
H.R., head of radius
I., medial epicondyle of humerus
I.B.N., intercostobrachial nerve
Inf., infraspinatus muscle
L., lumbrical muscle
L.C., lateral cord of brachial plexus
L.D., latissimus dorsi muscle
L.S., levator scapulae muscle
L.T.N., lateral thoracic nerve
M.A.C.N., medial antibrachial cutaneous nerve
M.B.C.N., medial brachial cutaneous nerve
M.B.V., median basilic vein
M.C., medial cord of brachial plexus
Mc.N., musculocutaneous nerve
M.C.V., median cephalic vein
M.N., median nerve
M.V., median vein
P.A., profunda brachii artery
P.C., posterior cord of brachial plexus
P.C.A., posterior humeral circumflex artery
P.Ma., pectoralis major muscle
P.Mi., pectoralis minor muscle
R., rib
Rh, rhomboid muscles
R.N., radial nerve
S.A., serratus anterior muscle
S.C.M., sternocleidomastoid muscle
S.N., suprascapular nerve
Sp., spine of scapula
S.P.I., serratus posterior inferior muscle
Spl, splenius cervicis et capitis muscle
S.R.N., superficial radial nerve
Sup, supraspinatus muscle
T_1, long head of triceps muscle
T_2, lateral head of triceps muscle
T_3, medial head of triceps muscle
T.Ma, teres major muscle
T.Mi, teres minor muscle
Tr, trapezius muscle
Trx, cut edge of trapezius muscle
U.N., ulnar nerve
X, depression in back over defective vertebrae

PLATE 1

EXPLANATION OF FIGURES

1 Deformed foetus seen from in front.
2 Deformed foetus seen from left side.
3 Left arm, viewed laterally, showing monodactyly and webbed elbow.
4 Right arm, viewed ventromedially, showing monodactylous hand and extra digit located at elbow.

1

2

3

4

PLATE 2

EXPLANATION OF FIGURES

5 Radiograph of foetus from right side. Thirteen thoracic vertebrae and ribs are shown.

Cervical Vertebra I.
Cervical Vertebra VII
Thoracic Vertebra I.
Scapula.
Thoracic Vertebra XIII.
Lumbar Vertebra I
Clavicle
Radius
Lumbar Vertebra V
Sacral Vertebra I.
13 Ribs
Humerus
Ilium
Sacral Vertebra V.
Femur
Coccygeal Vertebra I.
Ischium
Pubis
Tibia
Fibula
Talus
Calcaneus
Proximal Phalanges
Distal Phalanges
Metacarpals

5

PLATE 3

EXPLANATION OF FIGURES

6 Radiograph of foetus from ventral surface to show thirteen thoracic vertebrae and ribs. Two defective vertebrae are seen in the thoracic region.

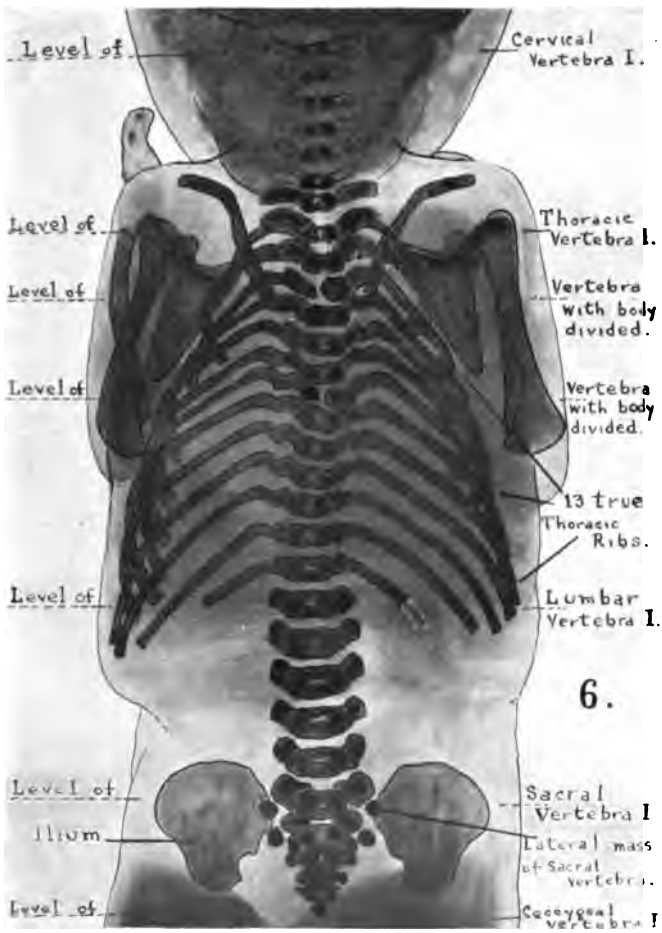
Level of
Cervical Vertebra I.
Level of
Thoracic Vertebra I.
Level of
Vertebra with body divided.
Level of
Vertebra with body divided.
13 true Thoracic Ribs.
Level of
Lumbar Vertebra I.
6.
Level of
Ilium
Sacral Vertebra I
Lateral mass of Sacral vertebra.
Level of
Coccygeal vertebra I

PLATE 4

EXPLANATION OF FIGURES

7 Superficial dissection of the ventral surface of the left arm.
8 Deep dissection of the ventral surface of the left arm.
9 Superficial dissection of the dorsal surface of the left arm.
10 Deep dissection of the dorsal surface of the left arm.

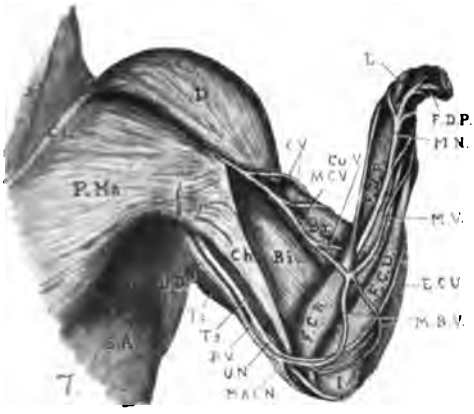

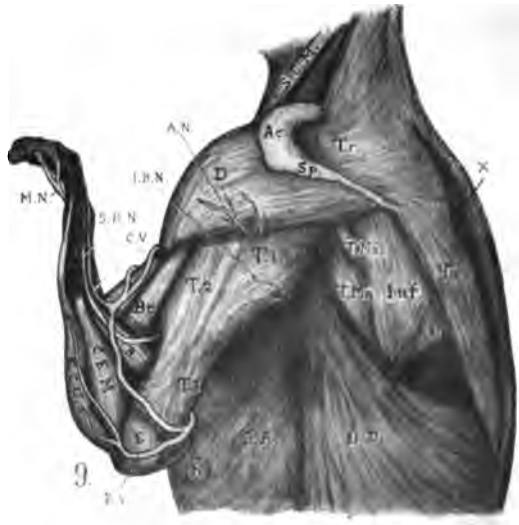

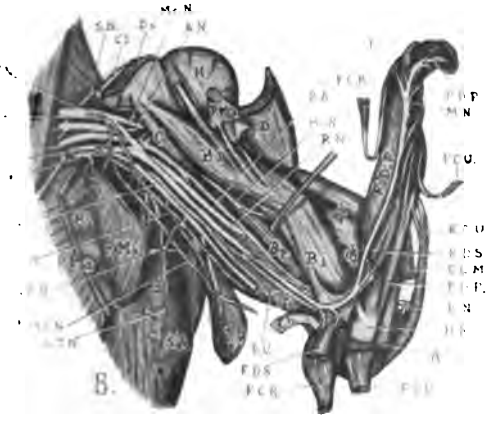

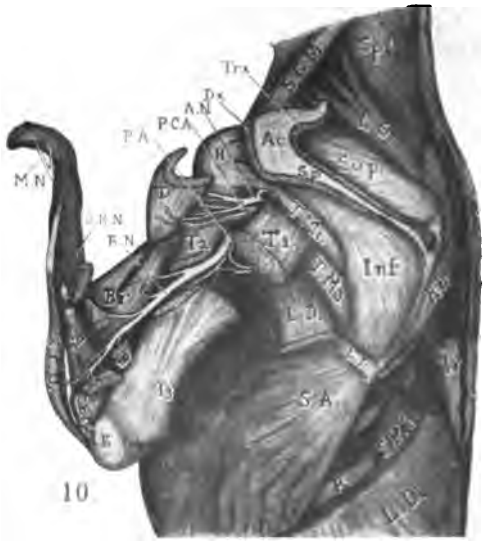

UNIV. OF
CALIFORNI

UNIVERSITY OF TORONTO STUDIES

ANATOMICAL SERIES

No. 1: The anatomy of the orang-outang, by Professor A. PRIMROSE ..... o.p.

No. 2: The skull of a human foetus of 40 mm., by CHARLES CLIFFORD MACKLIN 0.50

No. 3: Anatomy of a seven months' foetus exhibiting bilateral absence of the ulna accompanied by monodactyly, by J. C. WATT 0.50

EXCHANGE
DEC 7 1921

UNIVERSITY OF TORONTO STUDIES

ANATOMICAL SERIES

LIBRARY OF THE UNIVERSITY OF CALIFORNIA

No. 4: SYMMETRICAL BILATERAL DYSTOPIA OF THE KIDNEYS IN A HUMAN SUBJECT, WITH OUTWARD ROTATION OF THE HILUS, MULTIPLE ARTERIES AND VEINS, AND A PERSISTENT POSTERIOR CARDINAL VEIN, BY J. C. WATT

(REPRINTED FROM THE ANATOMICAL RECORD, VOL. 19)

THE UNIVERSITY LIBRARY: PUBLISHED BY
THE LIBRARIAN, 1920

University of Toronto Studies

COMMITTEE OF MANAGEMENT

Chairman: SIR ROBERT ALEXANDER FALCONER, LL.D., K.C.M.G.
President of the University

PROFESSOR W. J. ALEXANDER, PH.D.

PROFESSOR J. J. MACKENZIE, B.A., M.B.

PROFESSOR J. P. MCMURRICH, PH.D.

BRIG.-GEN. C. H. MITCHELL, B.A.SC., C.B., C.M.G., D.S.O.

PROFESSOR G. H. NEEDLER, PH.D.

PROFESSOR GEORGE M. WRONG, M.A.

General Editor: H. H. LANGTON, M.A.
Librarian of the University

AUTHOR'S ABSTRACT OF THIS PAPER ISSUED BY THE BIBLIOGRAPHIC SERVICE, JUNE 21

Reprinted from THE ANATOMICAL RECORD, Vol. 19, No. 3, August, 1920

SYMMETRICAL BILATERAL DYSTOPIA OF THE KIDNEYS, IN A HUMAN SUBJECT, WITH OUTWARD ROTATION OF THE HILUS, MULTIPLE ARTERIES AND VEINS, AND A PERSISTENT POSTERIOR CARDINAL VEIN

JAMES CRAWFORD WATT

Department of Anatomy, University of Toronto

TWO FIGURES

In the laboratory of the Department of Anatomy of the University of Toronto a very interesting series of associated anomalies relating to the kidneys and their vessels was discovered during the regular course of dissection. The specimen was at once put aside for investigation, and on further study has been considered worthy of a detailed description.

The body was that of a well-proportioned but somewhat emaciated male, aged twenty-seven, who died of pulmonary tuberculosis. Apart from the abnormalities associated with the kidneys, no other gross anomalies were noticed in this subject.

THE KIDNEYS

Shape and size (fig. 2)

The outline of the kidneys is that of a long, narrow oval. The ventral surface is quite convex, the dorsal surface flattened. Of the two poles, the lower is much thicker than the upper. A shallow groove winding spirally from the ventral surface laterally and caudally on to the dorsal surface forms the hilus, and notches the outer border where it crosses it. Except for the presence of the hilus, the surface is smooth, and shows no special lobulation.

was in contact with the vertebrae medially for two-thirds of its length. The lower pole, however, had the upper pole of the kidney inserted between it and the vertebral column.

On the right side the kidney and suprarenal gland lay entirely below the level of the liver, which was thus allowed to come into contact with the diaphragm on its posterior surface.

The upper pole of each kidney and the common renal vein from each side were under cover of the duodenum at the flexure of the latter at the lower end of the descending limb.

The hilus (fig. 2)

The position of the hilus is most interesting, and is quite similar on both sides. Starting above, about three centimeters below the upper pole, on the anterior surface, it runs obliquely caudad to cut the lateral border of the kidney, forming a notch on it about two thirds of the way down. It then curves from here on to the posterior surface, ending about two or three centimeters from the lower end of the kidney.

The hilus is thus placed on the opposite border to the normal and forms a spiral with gradually increasing rotation about the polar axis as it proceeds caudad.

VESSELS

Arteries (figs. 1 and 2)

The renal arteries and also the spermatic arteries of both right left sides are multiple.

Right side. The right renal arteries are five in number. The first comes off the abdominal aorta at the level of the second lumbar vertebra and goes behind the inferior vena cava to the upper end of the hilus on the anterior surface of the kidney. The second renal artery also goes to this surface, coming from the aorta at the level of the third lumbar vertebra and running in front of the vena cava.

Off the right common iliac artery come the third renal artery, a very small one, the fourth, quite large and dividing early into

two, and the fifth, a small artery again. These three arteries running in close company pass behind the lower pole of the kidney and enter the lowermost part of the hilus on the posterior surface.

The right spermatic arteries are two in number. The higher one arises from the aorta between the first and second renals, and runs posterior to the inferior vena cava and both renal veins, but anterior to the upper pole of the kidney. The lower artery arises from the second renal, goes posterior to the inner renal vein, anterior to the outer vein, and anterior to the kidney. At the lateral border of the kidney the two spermatic arteries and the vein form a common bundle running in contact with this border and the ureter in the iliac fossa, and then turning over the psoas muscle to the internal abdominal ring.

Left side. There are four left renal arteries. The first is off the aorta at the upper limit of the second lumbar vertebra and runs down anterior to the upper pole of the kidney. The second artery is from the aorta, over the second lumbar vertebra, level with the highest artery on the right. It is also to the hilus on the upper part of the anterior surface of the kidney.

The third left renal artery is off the left common iliac, and is peculiar in that it runs across the upper part of the iliac fossa behind the kidney, to pass into the hilus just where it cuts across the lateral border.

The fourth artery is off the internal iliac, or hypogastric artery, just at its commencement, and runs anterior to the external iliac artery and psoas major muscle and penetrates the kidney on its medial border just near the lower pole.

On this side there are three spermatic arteries, the highest coming off a suprarenal branch of the first renal, the other two directly off the first renal. All three arteries and the spermatic vein form a common bundle coursing anteriorly along the lateral border of the kidney, then lateral to the ureter in the iliac fossa and down to the inguinal canal.

Veins (figs. 1 and 2)

Right side. There are two renal veins, both coming from the upper part of the hilus over the anterior surface of the kidney, and uniting at the level of the upper pole of the organ into a common vein which is about three-quarters of an inch in length and empties directly into the inferior vena cava.

The right spermatic vein, a single vessel, opened into the lateral of the two renal veins.

Left side. On this side are three renal veins. Two are quite similar to those on the right, arising from the anterior surface of the kidney on the upper part of the hilus and uniting into a common stem which crosses anterior to the aorta and empties into the inferior vena cava.

Just at the junction of the above two veins, there comes into the medial one, a longitudinal vein which lies over the front edge of the psoas muscle, on the vertebral column, in the interval between the aorta and the left kidney. This stem starts at the level of the fifth lumbar vertebra, and communicates with the left common iliac vein below. As it ascends it receives as tributaries four lumbar veins, one of which is double, and also a renal vein. This renal vein comes from the hilus where the latter cuts the outer border of the kidney, and runs medially posterior to the kidney, alongside of the third renal artery, and ends in this ascending vein. This longitudinal stem is interpreted as a persisting portion of the embryonic posterior cardinal vein of the left side, which lies exactly in the position occupied by this present vein.

The left spermatic vein, single in spite of the presence of three arteries, empties at the junction point of the two large upper renal veins into the common trunk.

Ureter (figs. 1 and 2)

The position and relations of the ureter are remarkably symmetrical on the two sides.

At its pelvis, each ureter is divided into two parts. One is a long, narrow, tubular portion which lies in the upper part of

the hilus, on the anterior surface of the kidney. The other is a broad, short, funnel-shaped portion communicating with the kidney in the hilus just before the latter cuts round the outer border of the organ.

The two parts unite at the lateral border of the kidney, which the ureter now follows to the lower pole, where it then crosses the iliac fossa, turns medially over the psoas muscle and external iliac artery into the pelvis, where its course into the bladder is normal.

The highest artery and the lateral vein accompany the upper branch of the ureter as it enters the kidney, the vessels lying behind. The other vessels enter the kidney mostly behind the lower branch of the ureter.

SIMILAR CASES

Multiple renal arteries and veins in all the locations found in this case have been previously described and discussed by various authors, and so call for no special consideration. Tonkoff ('03), for instance, describes and gives a figure of a right kidney slightly displaced downward and with an arrangment of its four renal arteries almost identical with those of the left kidney in this case.

Macalister ('83) and Morris ('85) both state that abnormal vessels occur in three individuals out of every seven.

The occurrence of a vena cardinalis posterior along with renal anomalies has been noted before. Melissinos ('11) found a case of pelvic kidney with a persistent right cardinal vein, and gives reference to a few other instances.

The presence of the rotation seen in these kidneys, on the contrary, is evidently quite a rare condition. Among the anomalies of position of the hilus, the particular one exhibited here is not even mentioned in the text-books on pathology or surgery. It is self-evident that such a position would be of great interest, especially to the surgeon.

Gerard ('05), in a review of 527 cases, states that the renal hilus, instead of lying medially, may be superior, inferior, ventral, or dorsal, but does not mention any instance of a lateral position.

Müllerheim ('02) describes a case where the left kidney was found in the pelvis, with its hilus not medial, but anterior, and he states that one of the characteristics of dystopia of the kidney is that the hilus is usually anterior in position.

Morris ('04), in a summary of displacements, states that the kidney may be rotated so that the hilus looks upward, outward, directly forward or backward, and mentions one case of the hilus occurring laterally. This case was described by Farquharson ('94) as a left kidney placed in the pelvis with hilus looking to the left.

Brown ('94) also describes a right pelvic kidney which had rotated till its posterior surface had become anterior and the hilus looked posteriorly to the right. Johnson ('14) described a case in the cat exactly similar to that of Brown's and Anitschkow ('12) describes and gives a figure of a left kidney in man displaced slightly back in the lumbar region and with a hilus which he describes as anterior, but which, in the illustration, appears to course around the lateral border, as there is a marked indentation shown there.

McMurrich ('98), considering a series of crossed dystopia of the kidneys with fusion, pointed out that in nearly all cases the position of the hilus was anterior.

This retention of an anterior position of the hilus in displacements and in fusions of the kidneys is the retention of the normal embryological position. Pohlman ('05) noted that until the kidney had ascended in the embryo to where it was approximately in the adult position, the hilus was ventral, and then a rotation medially of 90° occurred about the polar axis. Felix ('12) also states that this rotation occurs, but that a reverse rotation toward the ventral surface also occurs later, so that the hilus is finally ventromedial.

The kidneys in the present case have not reached the usual final level and so might be expected to have retained the hilus anteriorly. This is true of the upper part, but the lower portion exhibits the rare outward rotation through 90° to bring it laterally, and the lowest part goes even further than this to lie posteriorly. There is thus considerable torsion in the kidney, the hilus forming quite a spiral in its course.

The fact that the ureter lies ventral to the main renal vessels at the hilus at first sight appears as an anomaly. It will be seen, however, that if the hilus were to be rotated into its usual position the ureter would then lie posterior to the vessels. Thus at their entrance into the kidney these structures stand in their normal relations to each other, but the rotation makes them appear reversed.

The position of the suprarenal glands is interesting. McMurrich, Morris, Müllerheim, and others have all stated that the relation of these glands to the kidneys is merely topographical and that they are found in their usual places in cases where the kidneys are displaced. In this instance, however, they lie closely capping the upper pole of each kidney, and so are displaced somewhat caudally from their normal location.

What was the actual cause of all the anomalies shown above is open to conjecture. It must have been a force acting in early embryonic life. The displacement into the iliac fossa was probably due to lack of growth in the ureter and the torsion due to a twisting of the pelvis of the ureter. It is of interest to note that Felix ('12) states that in the lumbar region the ureter shows a dilatation accompanied by a spiral twisting. An exaggeration of this process might possibly account for the result shown here. Whatever the cause may have been, the result is most remarkable for instead of a symmetrical displacement of the whole organ, we have here the upper pole with the upper end of the hilus facing still in the old embryological position, while proceeding caudad there is an ever-increasing torsion evident, until finally at the lower end the hilus shows a displacement of 180° brought about by lateral rotation.

The position of the kidneys in the lower lumbar region and iliac fossa seems to be a much rarer condition than the position within the pelvis, as by far the greatest majority of cases of dystopia without fusion are reported as being in the pelvis.

The symmetrical degree of dystopia shown by these two kidneys seems to be almost as rare a condition as the lateral hilus. In all the cases quoted above and in many others not mentioned here, if the two kidneys are not fused to form the discoidal or the

horseshoe kidney, either there is a much greater degree of dystopia on one side than on the other or else only one kidney shows displacement, the other being in its normal position. Thus the kidneys in this instance are unique in several respects and have therefore seemed well worthy of description.

BIBLIOGRAPHY

ANITSCHKOW, N. N. 1912 Studien über Nierengefässe bei Angeborener Nierendystopie. Virch. Arch. für. path. Anat., Bd. 207, S, 213.

BROWN, M. 1894 Variations in the position and development of the kidneys. Journ. of Anat. and Physiol., vol. 28.

FARQUHARSON, W. F. 1894 Case of left kidney, displaced and immovable. Journ. of Anat. and Physiol., vol. 28.

FELIX, W. 1912 The development of the urinogenital system. Keibel and Mall's Human Embryology, vol. 2, J. B. Lippincott Co., Philadelphia and London.

GÉRARD, G. 1905 Les anomalies congénitales du rein chez l'homme. Journ. de l'Anat. et de la Physiol., T. 16, p. 241 et 411.

JOHNSON, C. E. 1914 Pelvic and horseshoe kidneys in the domestic cat. Anat. Anzeiger, Bd. 46, S. 69.

MACALISTER, A. 1883 Multiple renal arteries. Journ. of Anat. and Physiol., vol. 17, p. 250.

McMURRICH, J. P. A case of crossed dystopia of the kidneys with fusion. Journ. of Anat. and Physiol., vol. 32.

MELISSINOS, VON K. 1911 Beckenniere mit persistierender Vena cardinalis dextra. Anat. Anzeiger, Bd. 39, S. 149.

MORRIS, HENRY 1885 Surgical diseases of the kidney. Cassell & Co., London. 1904 Surgical diseases of the kidney and ureter, including injuries, malformations and misplacements. Vols. 1 and 2. Keener & Co., Chicago, U. S. A.

MÜLLERHEIM, R. Ueber dei diagnostische und klinische Bedeutung der congenitalen Nierendystopie, speciell der Beckenniere. Berlin. klin. Wochschr., 1902, S. 1130.

POHLMAN, A. G. 1905 A note on the developmental relations of the kidney and ureter in human embryos. Johns Hopkins Hosp. Bull., vol. 16, no. 167, February, 1905.

TONKOFF, W. 1903 Beitrag zu den Nierenanomalien. Intern. Monatschr. für Anat. und Physiol., Bd. 20, S. 449.

UNIVERSITY OF TORONTO STUDIES

ANATOMICAL SERIES

No. 1: The anatomy of the orang-outang, by Professor A. PRIMROSE ..... o.p.

No. 2: The skull of a human foetus of 40 mm., by CHARLES CLIFFORD MACKLIN 0.50

No. 3: Anatomy of a seven months' foetus exhibiting bilateral absence of the ulna accompanied by monodactyly, by J. C. WATT 0.50

No. 4: Symmetrical bilateral dystopia of the kidneys in a human subject, by J. C. WATT 0.25

UNIVERSITY OF TORONTO STUDIES

ANATOMICAL SERIES

EXCHANGE
OCT 18 1922

No. 5: THE TERMINALS OF THE HUMAN BRONCHIOLE,

BY HERBERT G. WILLSON

(REPRINTED FROM THE AMERICAN JOURNAL OF ANATOMY, VOL. 30)

THE UNIVERSITY LIBRARY: PUBLISHED BY
THE LIBRARIAN, 1922

University of Toronto Studies

COMMITTEE OF MANAGEMENT

Chairman: SIR ROBERT ALEXANDER FALCONER, LL.D., K.C.M.G.
President of the University

PROFESSOR W. J. ALEXANDER, PH.D.

PROFESSOR J. J. MACKENZIE, B.A., M.B.

PROFESSOR J. P. MCMURRICH, PH.D.

BRIG.-GEN. C. H. MITCHELL, B.A.SC., C.B., C.M.G., D.S.O

PROFESSOR G. H. NEEDLER, PH.D.

PROFESSOR GEORGE M. WRONG, M.A.

General Editor: H. H. LANGTON, M.A.
Librarian of the University

AUTHOR'S ABSTRACT OF THIS PAPER ISSUED BY THE BIBLIOGRAPHIC SERVICE, MARCH 27

Reprinted from THE AMERICAN JOURNAL OF ANATOMY
Vol. 30, No. 3, May, 1922

THE TERMINALS OF THE HUMAN BRONCHIOLE

HERBERT G. WILLSON

University of Toronto

NINE FIGURES

In the hope of throwing some light on certain questions about which there has been controversy, the construction of a wax model of a respiratory bronchiole was begun at the University of Toronto in October, 1919. The work was carried out in collaboration with Prof. J. Playfair McMurrich, by whom the problem had been suggested and to whom the writer is very greatly indebted for advice and assistance.

The extreme complexity of the terminal branches of the bronchial tree is not generally appreciated. The maze of channels which occur even in a minute piece of lung tissue cannot be visualized accurately from a mere comparison of serial sections. The larger passages of the lung may be injected with wax or metal and a cast obtained by corroding away the lung tissue, but one cannot be certain of obtaining in this way a complete cast of the smaller tubes. The method of wax reconstruction of serial sections is the only plan by which one may hope to get clear ideas regarding the finer tubes, and even this method is especially difficult to apply to the bronchioles. So complicated are the branchings and so carefully has nature economized space in the lung, that if all the air passages in a piece of lung tissue are reconstructed in wax on a magnified scale, the result is practically a solid, and the model has to be dissected in order to show the relationships of tubes and air-cells.

Malpighi in 1661 demonstrated the vesicular nature of lung tissue and showed how the trachea terminates in bronchial filaments, but after his time there was no important contribution to the knowledge of the histology of the lung until the early part

of the nineteenth century, when Soemmering, Rossignol, Reisseisen, and others published the results of their researches, and Henle, by his discoveries in general histology, laid the foundation for many special investigations. Controversy now arose in regard to such questions as the exact shape of the terminal bronchioles, their method of branching, and as to whether or not there were direct communications between alveoli.

Rossignol, writing in 1847, refers to the most distal divisions of the bronchial tree as 'infundibula,' and these he describes as being thickly beset with alveoli. He notes that the alveoli of the infundibulum are of an unusually great depth, and that while the alveoli are scattered and few in the proximal part of the respiratory bronchiole, they are soon arranged close together, covering the whole surface of the last bronchial divisions. As to the method of branching, he concludes that there are both dichotomous and trichotomous divisions. In his investigations Rossignol inflated and dried the lung, after having injected the blood vessels.

In 1860 Waters described monopodial, dichotomous and trichotomous branching. His conclusions were based on the study of single sections. In man he found no alveoli in the terminal bronchiole, but only in the infundibulum. He states that at a certain place the terminal bronchiole widens into a cavity into which open six, eight, or ten canals, beset with alveoli. These canals he terms air-sacs, these being again identical with Rossignol's infundibula.

F. E. Schulze in 1871 used the term 'Alveolengang' to denote all the parts of the tubular system on which there are alveoli, excepting, however, the terminal sacs, for which he employed the term infundibula.

In 1892 W. S. Miller announced the discovery of a new element in the series of pulmonary air-spaces, terming it the 'atrium' and locating it between the air-sacs (infundibula) and the terminal bronchiole (alveolengang). This space seems to be identical with the enlargement of the terminal bronchiole described by Waters as giving origin to the air-sacs, but Miller describes it as something more than a mere enlargement, having a more

or less spherical form with numerous alveoli on its walls and giving origin to from two to five air-sacs. The lung of the dog was used in Miller's first investigation; but in 1900 and again in 1913 he published accounts of further researches, and maintained that his description held good for lung of cat, ox, child, and adult man.

In his article of 1900 he gives the following table of nomenclature for the air-spaces of the lung:

W. S. MILLER	B. N. A.	SCHÄFER	SCHULZE	KÖLLIKER
Bronchus	Bronchiolus respiratorius	Bronchial tube	Alveolengang	Alveolengang
Terminal bronchiole	Ductuli alveolares	Lobular bronchus		
Atrium				
Air-sac		Air-sac	Infundibulum	Infundibulum
Air-cell	Alveolus pulmonis	Air-cell	Alveolus	Alveolus

But at the same time he revised his own earlier terminology, substituting the B. N. A. terms for 'Bronchus' and 'Terminal bronchiole.' In his investigations Miller used the method of wax reconstruction. His results have found wide acceptance by the authors of text-books, in spite of several dissenting voices.

In 1900 Justesen gave an account of his investigations of the structure of the lung in oxen. He used corrosion preparations and also serial sections, drawings of which were made on transparent paper, so that by superposing the drawings, successive sections might be compared. He finds that each 'bronchiolus simplex' forms dichotomously two respiratory bronchioles, each of which again divides dichotomously, each of the branches so formed ending in a large cavity which he identifies with the atrium of Miller. His atria are variable in size, sometimes quite distinct, and sometimes only slight enlargements of the bronchioles, and while Miller finds two to five air-sacs on each atrium, and Waters six to ten, Justesen believes that there are normally four. Two first bud out and these then divide, so that each of the four occupies a position corresponding to one of the angles

at the base of a four-sided pyramid, the apical angle of which is occupied by the atrium. In other words, the air-sacs do not arise as accidental growths from the atria, but are formed by two successive dichotomies in planes at right angles. In the adult ox he found occasionally but three air-sacs on an atrium—a condition which he explains by supposing that in the case of the primary air-sacs the secondary dichotomy had failed owing to space exigency.

Justesen holds that the bronchial branchings occur in a definite mathematical plan and are fundamentally dichotomies, but that in the majority of the branches the dichotomy becomes modified into a sympodial arrangement, the terminal branches still retaining the dichotomous plan. If this be so, and the mathematical regularity of the dichotomies persist, the lateral branches of each sympodial stem might be expected to show a decreasing number of air-sacs as they were traced peripherally, one arising from an earlier dichotomy having twice as many air-sacs as that which arose from the succeeding dichotomy. Justesen believed that he obtained evidence in favor of this arrangement in his observation on the pig where the eparterial bronchus gave rise to as many lateral branches as did the stem branches for the rest of the lung.

F. E. Schulze, writing in 1906, takes the view that Miller's atria are not new spaces, but only those parts of the ductuli alveolares into which the sacculi open. He states:

> So wenig, wie man an einem sich unregelmässig verzweigenden Baumast diejenigen Stellen, wo sich ein Ast in zwei oder auch mehrere Endäste teilt, als besondere typische Stellen charakterisieren und mit einem eigenen Namen, sondern einfach als Teilungsstellen zu bezeichnen pflegt, so wenig scheint mir in dem respiratorischen Gangsystem der Lunge die Auszeichnung dieser Stellen durch eine besondere Benennung ('Atrium') erforderlich oder auch nur zweckmässig zu sein.

Schulze claims that normally in man and in many mammals there are direct communications between alveoli—'alveolar pores'—and in this view he is supported by Hansemann, Hassall, Zimmerman, Nicolas, and Merkel, but is opposed by Piersol, W. S. Miller, Laguesse, and Oppel.

In 1907 J. Müller investigated the lungs of most of the domestic animals, using metal corrosions as well as sections. His conclusions regarding the occurrence of atria he states as follows:

Hinsichtlich des neuen Luftraumes, des Atriums, war es mir nun weder an den Korrosionspräparaten noch an den Schnitten bei irgend einem unserer Haussäugetiere möglich, ihn als einen Luftraum sui generis bestätigen. Wenn auch da und dort einmal ein Alveolengang vor seiner Auflösung in die Infundibula eine buchtige Erweiterung zeigte, welche etwa dem 'Atrium' Justesens entsprechen könnte, so habe ich doch niemals zwischen jedem Infundibulum und dem Alveolargang, noch auch zwischen mehreren Infundibeln und einem solchen einen oder mehrere kugelige Hohlräume eingeschaltet gesehen, welche für das konstante Vorkommen der Millerschen Atrien sprechen könnten.

Müller found alveolar pores in various animals, but not in young animals. He thinks these are pathological.

Just as my first model was completed, I received the number of The American Journal of Anatomy that contained two articles by the Japanese investigator Ogawa, who by an interesting coincidence had been working in the University of Kyoto at exactly the same problem as myself and by similar methods, but had evidently begun the construction of his model some months before I started with mine. Ogawa worked with human material, and constructed both a negative and a positive model of the terminal branchings of the lung, the former being at a magnification of 100 diameters and measuring 8 x 12 x 8 cm., while the latter was enlarged 80 diameters and measured 11.3 x 24 x 20 cm. Like Schulze and Müller, he reaches the conclusion that "Miller's atrium is an unnecessary term, at least for the human lung." In his second paper he states that "alveolar pores are normally found in many mammals, and only seldom cannot be seen." Further reference to Ogawa's work will be made when his results are compared with my own.

MATERIAL

The material used was exclusively human and consisted of portions of the lungs of two individuals obtained at autopsies performed soon after death. One of the individuals was a woman of thirty years who had died of heart disease (mitral stenosis),

while the other was a child whose age could not be definitely ascertained, but was certainly less than thirteen years. In the case of the adult, portions of suitable size were taken from the lungs and immersed in Bouin's fluid, but in the case of the child's lung the entire organ was first injected through the bronchus under gentle pressure with Bouin's fluid, and then immersed in the same fluid, portions suitable for sectioning being taken only after the tissue had been fixed in this manner. The portions selected were carried through the various grades of alcohol and imbedded in paraffin, and to secure satisfactory penetration of the paraffin they were, while in 70 per cent alcohol, placed under the bell-jar of an air-pump and the air exhausted till bubbles ceased to rise from the cut surface of the tissue.

By this method a perfect infiltration of the paraffin was obtained, and the tissue was cut into serial sections, 20 μ thick in the case of the adult lung and 30 μ in that of the child. Both series were stained with Weigert's elastic tissue stain, this being chosen with the intention of studying later the distribution of the elastic fibers in the human lung. Wax reconstructions of the air spaces, i.e., negative reconstructions of portions of each lung were made at a magnification of 100. To ensure accuracy in the superposition of the wax plates in the model of the adult, numerous bridges were left in cutting out the air-spaces, but in the second model the necessary accuracy was obtained by the use of a duplicate series of drawings of the sections made upon transparent paper. A duplicate drawing of a section about the middle of the series was covered by a sheet of glass, and on this the pieces of wax representing the corresponding air-spaces were placed one after the other, as they were cut from the wax plate. The next succeeding drawing was then carefully oriented upon that first chosen, so that the position of the air-spaces shown in the one could be accurately determined with reference to those of the other, and from the information thus obtained the pieces of wax representing the air-spaces of the second section could be accurately adjusted on those cut from the first plate. Dealing in this way with successive drawings and wax plates, half the model was built up. This completed portion was then detached

from the sheet of glass, turned upside down, and the other portion of the model was then built up in the same way. This method of orientation was found to be much more economical of time than was the use of bridges and entailed no sacrifice of accuracy.

To follow a respiratory bronchiole from its beginning to its terminals, it was necessary to make drawings from 128 sections of the adult lung. As each section was 20 μ thick, it is evident that the piece of lung containing all these branches had a thickness of 2560 μ, i.e., 2.56 mm. or a little over 1/10 of an inch. It will be evident also that the height of the completed model would be 256 mm., or a little over 10 inches. In the case of the child's lung, drawings of sixty-three sections were required, and as each section was 30 μ thick, the thickness of the piece of lung reconstructed was 1890 μ, or 1.89 mm., and the height of the completed model approximately 7.5 inches.

RESULTS

The first impression received from inspection of the completed models is that the branchings of a respiratory bronchiole are far more complicated than is revealed in the text-books, and one feels also that there is difficulty in 'labeling' the various parts according to the terms commonly used. In some places a number of alveoli are represented in the reconstruction as opening into a cavity which seems too small to deserve the name of an air-sac, while in another place one finds an alveolus which is several times as large as the ordinary alveolus. The models indicate that the minute passages in the lung are not formed in strict accordance with the usual descriptions. The two models when placed side by side suggest at once that the child's lung is a miniature of the adult lung, just as the child's hand is a miniature of the adult hand, there being no apparent difference in complexity of structure. More air-sacs occur in the volume of child's lung represented than in the greater volume of adult lung represented in the first model.

A photograph of the model from the adult lung is shown in figure 1. It starts with a non-respiratory bronchiole which is

marked *3a*, and is so designated because in tracing it back through the serial sections it was found to represent the third dichotomy from a bronchus which contained cartilage in its wall. The *3a* dichotomizes into branchings marked *4a* and *4b*, of which *4b* has not been followed any further, but *4a* again divides dichotomously into *5a* and *5b*, whose walls show alveolar outbranchings, so that they are to be regarded as respiratory bronchioles. The *5b* is followed only a short distance, but *5a* again divides into two stems, one of which was followed for some distance, but its reconstruction is omitted in the photograph for the sake of simplicity. The other stem, which may be designated *6a*, is completely reconstructed, and gives rise to all that portion of the model which is colored. It can be followed into a further dichotomy, one branch of which gives rise to the portions colored orange and green, while from the other all the remaining portions originate. The orange and green portions have been separated from the rest of the model in order that its parts might be more completely shown.

A photograph of the model on this scale, though useful for a general orientation of its parts, does not sufficiently reveal the details. These are more clearly shown in figure 2, which represents a part of the portion colored orange in figure 1 at a greater magnification. It shows a number of infundibula or air-sacs with their alveolar outbranchings, and it shows also how difficult it is to determine exactly what shall be termed an air-sac and what an air-cell. Thus the lower of the two portions colored yellow might equally well be regarded as a single air-sac with a number of complicated air-cells, or as at least two air-sacs with a common basal portion. Similarly, the upper yellow portion might be regarded as a single large air-sac or as three, according to the point of view of the observer. The terms infundibulum or air-sac (ductulus alveolaris B. N. A.) and alveolus or air-cell are all useful in conveying an idea as to the arrangement of the terminal air-spaces of the lung, but it must be remembered that in the human lung, at least, transitions exist between them; particular cases may be found where it is difficult to say whether one is dealing with an air-sac or an air-cell.

To obtain a clearer picture of the terminal branchings, those represented in both models were projected upon a single plane, the projections being based partly on tracings of various sections used in the construction of the models, and partly on sketches of the smaller parts. The result obtained in the case of the model of the child's lung is shown in figure 3. The stem marked *1* is a non-respiratory bronchiole which was traced through seventy-four sections (2.22 mm.) to reach its origin from a bronchiole with cartilage in its wall. Four dichotomies occurred in this distance. In the model of the adult lung three dichotomies occurred between the first respiratory bronchioles and the bronchiole with cartilage in its wall. The stem (*1*) divides into two branches, only one of which (*2*) was followed; this was a respiratory bronchiole, alveoli occurring on its wall. It in turn undergoes a dichotomy, only one limb of which (*3*) was followed, and then two additional dichotomies succeed in rapid succession, only one branch of each being followed. That followed from the last of these dichotomies (*6*) again divides into *7* and *8*, these again into *9* and *10* and *11* and *12*, respectively, but beyond this the branchings become irregular, and while it would be possible to interpret some of these divisions as dichotomies, there are others where the branching could be more accurately termed a trichotomy. In fact, the branching in some parts is so irregular that almost any 'method' might be read into it. The truth seems to be that, as the terminals are approached, no one system of branching is followed, but one edict is obeyed, i.e., that there must be no waste of space.

Embryological investigation has shown that in the early development the branching is dichotomous, and apparently this is continued, with some modification in certain of the branches, until there comes a time when the small bronchioles are competing with one another for space, and then they branch or send out processes in any possible direction. This competition for space of the infundibula and alveoli, seen in the complicated interdigitation of these elements from different respiratory bronchioles and in their varying form and size, is the most striking impression that one receives from a study of the models. An idea of the

manner in which the infundibula fit in with one another may be obtained from figure 4, which is a photograph of the pleural surface of the model of child's lung. The numbers on the infundibula correspond with those on the branchings shown in figure 3.

From the diagram and the accompanying photographs it will be evident that the models reveal no definite space which corresponds to Miller's atrium. Careful study of the models shows, it is true, enlargements of the respiratory bronchioles where several infundibula communicate with them, but these enlargements exhibit no definite delimitation from the remaining portions of the bronchioles, and they never assume a spherical form. Schulze was probably correct in his contention that a special name is not needed for that part of a branch from which a number of subordinate branches arise.

It is interesting to note that Justesen's description of the branchings of a respiratory bronchiole applies very closely to the branchings revealed by the models, except in regard to the atrium. Both Waters and Justesen held very decided views as to the planes in which successive branchings occur. Waters believed the plane of two diverging branches to be always at right angles to the plane of the two branches preceding. Justesen claims that "there is a strong tendency of the dichotomous divisions to lie in alternating planes cutting one another at right angles," but this was not universal. Examination of the models indicates that Waters' rule is by no means constantly true. Four angles which, according to Waters' rule, would be 90°, were found to be approximately 85°, 90°, 10°, and 45°.

The number of branchings that intervene between a non-respiratory bronchiole and an air-sac was determined in seven cases, and in three the air-sacs were reached at the fifth division, in three at the sixth, and in one case at the seventh. Ogawa found from two to nine ramifications, with an average from fourteen cases of 5.57. Laguesse found six or seven branchings.

The alveoli or air-cells on seven different air-sacs were counted, the numbers being as follows: 22, 14, 16, 18, 12, 16, and 20, giving an average of 16.8. Ogawa's average is 11. However, many of the air-sacs, as Justesen says, are bifurcated or deeply

indented, and a good deal depends on whether the subdivisions are considered as separate air-sacs or not.

Calculating from the lengths of the tubes in the model the following are the actual lengths of these tubes in the adult lung.

	mm.
No. 1	1.6
No. 2a	0.8
No. 3a	0.5
No. 4a	0.5
No. 5a	0.5
No. 6a	0.4
No. 6b	0.2

The greatest and least diameters of the non-respiratory bronchioles represented in the same model were estimated as follows:

	mm.
No. 3a	0.3 x 0.40
No. 4a	0.3 x 0.25
No. 4b	0.4 x 0.22

Similar estimates in the case of the respiratory bronchioles were:

	mm.
No. 5a	0.4 x 0.30
No. 5b	0.3 x 0.35
No. 6a	0.3 x 0.30
No. 6b	0.4 x 0.30

Measurements of the greatest and least diameters of those tubes into which the air-sacs open gave the following results in three cases,—the figures indicating the actual dimensions in the lung:

0.3 mm. x 0.2 mm.
0.5 mm. x 0.3 mm.
0.4 mm. x 0.3 mm.

This gives an average of 0.4 mm. × 0.27 mm.

Ogawa found the average diameter of an alveolar duct to be 0.24 mm., and he quotes Kölliker's estimate as 0.27 mm. and that of Schulze as from 0.4 to 0.2 mm.

It will be seen from these measurements and from the illustrations that the bronchial tree in its finer ramifications by no means shows a decrease in the diameter of successive branches

towards the periphery. There is, indeed, sometimes an increase even before the air-sacs are reached.

The air-sacs themselves show a great diversity of shape and size and frequently they are recurrent. Figure 2 shows plainly the tendency of the air-sacs to widen out to a greater diameter than the bronchiole from which they arise. It was, no doubt, this widening-out tendency which caused the early investigators to use the term 'infundibulum,' though the air-sacs are not funnel-shaped. Calculations of the actual size of eight air-sacs gave the following results, the measurements being taken in three dimensions:

0.4 x 0.8 x 0.4 mm.
0.3 x 0.6 x 0.3 mm.
0.7 x 0.4 x 0.3 mm.
0.6 x 0.3 x 0.4 mm.
1.0 x 0.4 x 0.5 mm.
0.3 x 0.4 x 0.3 mm.
0.5 x 0.3 x 0.2 mm.
0.4 x 0.6 x 0.2 mm.

The air-sacs or alveoli, as shown in the model, vary greatly in size and shape. The following estimates were made of the actual diameters in three directions of the alveoli of the lung: (All the measurements given above have reference to the adult lung.)

0.05 x 0.06 x 0.07 mm.
0.08 x 0.08 x 0.12 mm.
0.08 x 0.10 x 0.13 mm.
0.06 x 0.08 x 0.10 mm.
0.12 x 0.15 x 0.20 mm.
0.08 x 0.10 x 0.13 mm.
0.08 x 0.05 x 0.15 mm.
0.08 x 0.10 x 0.10 mm.
Average: 0.075 x 0.09 x 0.125 mm.
Extremes: 0.05 and 0.20 mm.

Ogawa in the case of a man of thirty-one years found an average of 0.1 mm. for depth and breadth of an alveolus, and in the case of a man of fifty-six years, his estimates are 0.15 mm. depth and 0.19 mm. breadth. Ogawa's extreme estimates, counting both his cases, are 0.04 and 0.21. It will be seen that many of the

alveoli represented in the model are elongated to a greater extent than is usually described, though, as has been mentioned, Rossignol noted that certain alveoli had unusual depth. The models confirm the observations of Rossignol regarding alveoli.

In the construction of the models and in the examination of the sections, careful search was made for evidence of interalveolar communications, but no evidence of their existence was found. The air-sacs interlock with wonderful closeness, so that there is absolutely no waste of space, and because of this close interlocking it sometimes requires great care to satisfy oneself of the absence of interalveolar communications, but in no case could such communications be demonstrated.

THE AREA OF PULMONARY AIR-SPACES

During the course of this work the interesting question of the total area of the respiratory air-spaces naturally suggested itself, and an attempt was made to answer it by estimating the total area of the respiratory epithelium in a cubic millimeter of lung tissue and then multiplying this by the total volume of the lung, expressed in cubic millimeters. It is evident that such a method can give only approximately the actual respiratory surface in the lung, since it takes no account of the variations that may occur in the size and number of the air-spaces in various cubic millimeters of the lung, and it fails to make allowance for the larger non-respiratory bronchioles and bronchi. Yet the calculation seemed worth carrying out, as it promised, at least, a maximum figure beyond which the total respiratory surface could not possibly extend.

In order to estimate the area represented in one cubic millimeter of lung tissue, a square of 100 mm. side was marked out on each of fifty successive drawings in the series of adult lung, the squares being oriented so that the series of squares represented successive sections of tissue. Since the sections were 20 μ thick, the fifty squares together represented sections totaling 1 cu. mm. in volume. The total perimeter of the various air-passages in each of these squares was measured. This was done by transferring the drawings within each square to millimeter paper, and

counting the number of millimeters in the perimeter of each air-space in that square, and totalling the amount. The grand total for the fifty squares amounted to 69346 mm. Since the magnification was 100 diameters, the corresponding perimeter in the actual lung would be $\frac{69346}{100}$ mm. and if this be multiplied by the thickness of the sections $\frac{20}{(1000)}$ the result will be nearly 14 sq. mm. of respiratory surface in 1 cu. mm. of lung tissue.

The lung tissue used in this estimation was obtained after the lungs had collapsed—the pleura having been opened. Vierordt estimates the volume of the lungs in this condition to be from 3005 to 3975 ccm. Taking the volume as the average of these, 3400 ccm. or 3400000 cmm., the area of the walls of the air-passages (respiratory and non-respiratory) is approximately $\frac{69346}{100} \times \frac{20}{1000} \times 3400000$ sq. mm., or about 47 square meters.

Now, the volume varies as the cube of like dimensions, while the area varies as the square of like dimensions, so that the area would not be doubled if the volume of the lung were doubled by expansion of air-passages. According to Arnold, the volume of the lung when fully inflated is 6805 ccm., and Vierordt states that the volume is 9521 ccm. 'bei stärkster Füllung.' For the areas corresponding to these estimates the extreme limits might fairly be placed at 70 and 90 square meters, respectively. Vierordt's estimate possibly refers to artificial inflation of the lungs after death. For the volume of the lungs on deep inspiration, Arnold's estimate seems a reasonable one, since 5500 ccm., in the case of the adult lung, is the approximate total volume of complemental, tidal, supplemental, and residual air. We are thus led to the conclusion that on ordinary deep inspiration the total area of the respiratory and non-respiratory epithelium is approximately 70 square meters, and the respiratory area alone must be considerably less than this. In order to estimate how much less, one would have to know the proportionate amount of respiratory to non-respiratory epithelium in the air-passages, and this is not known.

It might be pointed out that the method of multiplying the perimeter by the thickness of the section is exact only in the case of a tube of uniform diameter. To illustrate, it is plain that the cylinder formed by a pile of coppers has an area on its curved surface equal to the sum of the areas of the edges of the coppers, while the area of the curved surface of a cone is really greater than the total area of the edges of a number of discs of gradually diminishing diameter piled up to represent a cone. Here, then, is a source of error which tends towards making the result too low, while errors of omission in the counting or tracing would tend in the same direction. On the other hand, the cubic millimeter of lung tissue on which our calculation is based contained only the finer branchings of air-passages, so that the result would be accurate only if the whole lung were made up of such fine branchings. This source of error, tending to make a too high result, can hardly be canceled by the factors referred to above. The figures given probably represent the extreme upper limits of area corresponding to the respective degrees of expansion.

In Hermann's Handbuch der Physiologie there is given a calculation by Zuntz of the area of the respiratory surface. Zuntz assumes the average diameter of an alveolus to be 0.2 mm. when the lung is moderately inflated, and the total air-space of the lung to be 3400 to 3700 ccm. He considers that at least 3000 ccm. of this space is occupied by alveoli and infundibula. He calculates the volume of an alveolus as though it were a sphere, and arrives at the following result for volume and area of a single alveolus:

Volume, 0.00414 ccm.
Area, 0.125+ sq.mm.

Reducing the 3000 ccm. to cubic millimeters, he divides this volume by the volume of a single alveolus, and reaches the conclusion that the number of alveoli in the lung is 725 million. On the basis of this result and the estimated area of a single alveolus, he concludes that the area of the respiratory surface is 90 square meters, when the lung is inflated to a moderate extent.

Aeby used the same figures as Zuntz for volume and area of a single alveolus, assuming the average alveolus to be of spherical

form and to have a diameter of 0.2 mm. Since the volume of such a sphere is 0.004+ cmm., Aeby concludes that in a cubic millimeter of lung tissue there would be 250 such alveoli, each with an area of 0.125+ sq. mm., so that in a cubic millimeter of lung tissue the total area would be 250 × .125 or 31.25 sq. mm.

Nicolas gives estimates of the different areas of respiratory epithelium corresponding to the various degrees of expansion. He considers the maximum volume of air which the lungs will hold to be 4970 ccm. in the average man. His statements are based on calculations by Aeby:

> Le nombre total des alvéoles est immense. Huschke l'avait évalué à 1700 ou 1800 millions. Selon Aeby ce chiffre est beaucoup trop élevé. D'aprés ses calculs chaque millimétre cube de poumon comprendrait 250 alvéoles représentant une surface de 31.2 millimétres carrés. En estimant le volume du poumon à 1617 centimétres cubes chez l'homme et à 1290 chez la femme, on obtiendrait chez le premier une somme totale de 404 millions d'alvéoles et chez la seconde de 322 millions, (en chiffres ronds). Cette quantité correspondrait à une surface de 50 à 40 métres carrés pendant l'expiration forcèe, de 79 (homme) à 63 métres carrés (femme) pendant l'état moyen de repos, et enfin de 129 (homme) à 103 métres carrès (femme) lors d'une dilation compléte.

The result here given of 129 square meters is greatly in excess of my maximum result, in spite of the fact that in the calculations of Aeby and Nicolas the figure representing the volume of the lungs is smaller. The difference arises from the difference in the estimate of the number of square millimeters of area per cubic millimeter of lung tissue. Nicolas uses Aeby's estimate of 31.2 sq. mm., while my estimate is 14 sq. mm. To obtain a result of 31.2 sq. mm., according to my method of calculation, the air-spaces cut in an area of 1 sq.mm. would have to be much more numerous than those of any of my sections of adult lung.

F. E. Schulze also refers to Aeby's calculations. After explaining that Aeby assumes the average diameter of an alveolus to be 200 μ, he states that he cannot agree with Aeby's estimate of the number of alveoli and corresponding total respiratory surface. Schulze used his own estimate of the volume, 1500 ccm., for the lungs of the average man. To get the volume of the respiratory parenchyma he deducts 20 per cent, leaving 1200

ccm. He takes the volume of an alveolus to be 200^3 cubic microns. Reducing the 1200 ccm. to cubic microns, he divides the volume of a single alveolus into this total volume and arrives at the conclusion that there are 150 million alveoli in the lung, thus:

$$\frac{12 \times 10^{14}}{2^3 \times 10^6} = 150{,}000{,}000$$

He then calculates the area of an alveolus as 5×200^2 square microns, and estimates the total respiratory surface as $5 \times 200^2 \times 150{,}000{,}000$ square microns, or 30 square meters.

The estimates of Schulze and Zuntz are much higher than mine in proportion to the figures which they use for the volume of the lung.

In our calculation it was found that in the adult, a cubic millimeter of lung tissue represented the following area of lining of air passages:

$$\frac{69346}{100} \times \frac{20}{1000} = 13.869 \text{ sq. mm., or nearly 14 sq.mm.}$$

Similar calculations were made of the corresponding area in the child's lung, and estimates were made also from sections of emphysematous human lung and from the lung of an opossum. The results are given below.

ADULT NORMAL	CHILD	MAN OF 61, EMPHYSEMATOUS	OPOSSUM
14 sq.mm. (nearly)	19 sq.mm.	6 sq.mm. to 8.713 sq.mm.	27 sq.mm.

Some of the tracings on which these calculations are based are reproduced in figures 5 to 9.

In the child's lung only a few typical sections were counted, and only one reading was taken of the opossum lung.

In the emphysematous lung, the total perimeters of twenty-five consecutive sections were counted, the sections being of tissue near the pleura, though there were other parts, also near the pleura, where the emphysema was much more marked. The readings of the twenty-five squares gave a total of 21784 mm., an average of 871.3 mm., which corresponds in the actual

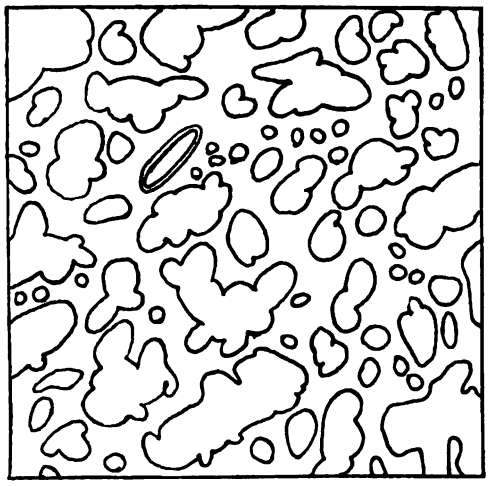

5



6



7

Figs. 5 to 7 Each figure represents a square millimeter of a section of lung tissue, traced with a projection apparatus. The figures were traced at the same magnification (× 100) and reduced in reproduction to × 60. The double lines represent blood vessels. Fig. 5, section of a child's lung. Fig. 6, section of an opossum lung. Fig. 7, section of an adult human lung.

8

9

Figs. 8 and 9 Each figure represents a square millimeter of a section of emphysematous (human) lung tissue, traced with projection apparatus. Both figures were traced at a magnification of 100 and reduced in reproduction to × 60.

lung tissue to an average perimeter of 8.713 mm. Using a more direct method of calculation than previously, this average perimeter of 8.713 mm. multiplied by 1 (millimeter) gives 8.713 sq. mm., the approximate area of lining epithelium in each cubic millimeter of emphysematous lung. The readings of eight other sections of emphysematous lung, taken from near the pleura, gave a total of 4728 mm., or an average of 591 mm., corresponding in the actual lung to 5.91 mm., or nearly 6 mm. This average perimeter in 1 sq.mm. corresponds to an area of 6 sq.mm. per cubic millimeter of lung tissue.

It will be seen that the average for all the readings of the emphysematous lung indicates that a man with emphysema might possibly have only half the normal amount of respiratory epithelium per unit of lung volume.

CONCLUSIONS REGARDING THE HUMAN LUNG

1. In the branching of the respiratory bronchioles there is far greater complexity, irregularity, and a greater degree of interlocking than is usually described.

2. There is no spherical space, or 'atrium,' such as has been described by Miller.

3. The method of branching of the bronchioles is dichotomous until the terminals are approached, and then the branching becomes irregular.

4. Counting as the first branch, a respiratory bronchiole arising from a non-respiratory one, the air-sac is usually reached at the fifth to seventh branch.

5. There are normally no direct communications between adjacent alveoli.

6. The bronchioles do not decrease in diameter as the periphery is approached, but remain of fairly uniform size until the air-sacs are reached, and the air-sacs are, as a rule, of greater diameter than the tubes from which they arise.

7. Waters' rule, that the planes of successive dichotomies cut one another at right angles, is only exceptionally confirmed.

8. The lung of the child is just as complex in structure as that of the adult.

9. It is calculated that during ordinary deep inspiration the total area of respiratory and non-respiratory epithelium in the adult lung is not greater than 70 square meters.

BIBLIOGRAPHY

AEBY, CHR. 1880 Der Bronchialbaum der Säugetiere und des Menschen.

HENLE 1873 Handbuch der Anatomie des Menschen, Bd. 2.

JUSTESEN, P. TH. 1900 Zur Entwickelung und Verzweigung des Bronchialbaumes der Säugethierlunge. Arch. f. mikr. Anatomie, Bd. 56.

MILLER, W. S. 1892 The lobule of the lung and its blood vessels. Anat. Anz., Bd. 7.

1893 The structure of the lung. Jour. Morph., vol. 8.

1900 Das Lungenläppchen, seine Blut und Lymphgefässe. Archiv. f. Anat. u. Physiol., Anat. Abt.

1902 Article 'Anatomy of the lungs.' Reference Handbook of the Medical Sciences, New York.

1907 A criticism of some of the recent literature on the structure of the lung. Anat. Rec.

1913 The air spaces in the lung of the cat. Jour. Morph., vol. 24.

MÜLLER, J. 1907 Zur vergleichenden Histologie der Lungen unserer Haussäugetiere. Archiv. f. mikr. Anatomie u. Entw., Bd. 69.

NICOLAS, A. 1903 Appareil respiratoire in Poirier's 'Traité d'Anatomie humaine.' Paris, T. 4, Fasc. 2.

McLEOD, J. J. R. 1920 Physiology and biochemistry in modern medicine, 3rd edition.

OGAWA, C. 1920 The finer ramifications of the human lung. Am. Jour. Anat., vol. 27, no. 3.

1920 Contributions to the histology of the respiratory spaces of the vertebrate lungs. Am. Jour. Anat., vol. 27, no. 3.

SCHULZE, F. E. 1906. Beiträge zur Anatomie der Säugethierlungen. Sitzungsbericht kgl. preuss. Akademie d. Wiss.

VIERORDT, H. 1906 Daten und Tabellen für Mediziner. Jena.

ZUNTZ, N. 1882 Hermann's Handbuch der Physiologie, IV Band Theil. S. 90.

PLATE 1

EXPLANATION OF FIGURE

1 Reconstruction from an adult lung. This model was made at a magnification of 100 diameters. The distance in the model from the top of the part colored orange to the bottom of the part colored green is 7 inches.



PLATE 2

EXPLANATION OF FIGURE

2 Part of a reconstruction of an adult lung, more highly magnified. This part is the right half of the portion colored orange in plate 1, seen from above. The illustration shows the part at its actual size in the model, which was constructed at magnification of 100 diameters.

2

PLATE 3

EXPLANATION OF FIGURE

3 Diagram of a reconstruction from a child's lung, showing the terminal branchings of a respiratory bronchiole, as projected upon a single plane. The numbers on the diagram correspond to those shown in plate 4.



3

PLATE 4

EXPLANATION OF FIGURE

4 Reconstruction from a child's lung, showing the air-sacs as they abut against the pleura. The model was made at magnification of 100 diameters. The part of the model shown in the illustration has a vertical height of 6½ inches. The numbers correspond to those in the diagram, plate 3.

CHICAGO PUBLIC LIBRARY

UNIVERSITY OF TORONTO STUDIES

ANATOMICAL SERIES

No. 1: The anatomy of the orang-outang, by Professor A. PRIMROSE ..... o.p.

No. 2: The skull of a human foetus of 40 mm., by CHARLES CLIFFORD MACKLIN 0.50

No. 3: Anatomy of a seven months' foetus exhibiting bilateral absence of the ulna accompanied by monodactyly, by J. C. WATT 0.50

No. 4: Symmetrical bilateral dystopia of the kidneys in a human subject, by J. C. WATT 0.25

No. 5: The terminals of the human bronchiole, by HERBERT G. WILLSON 0.50

UNIVERSITY OF TORONTO
STUDIES

ANATOMICAL SERIES

EXCHANGE
MAY 15 1924

No. 6: THE BEHAVIOUR OF CALCIUM PHOSPHATE AND CALCIUM CARBONATE (BONE SALTS) PRECIPITATED IN VARIOUS MEDIA, WITH APPLICATIONS TO BONE FORMATION, BY JAMES CRAWFORD WATT

THE UNIVERSITY LIBRARY: PUBLISHED BY
THE LIBRARIAN, 1923

University of Toronto Studies

COMMITTEE OF MANAGEMENT

Chairman: SIR ROBERT ALEXANDER FALCONER, LL.D., K.C.M.G., President of the University

PROFESSOR W. J. ALEXANDER, PH.D.

PROFESSOR J. P. MCMURRICH, PH.D.

BRIG.-GEN. C. H. MITCHELL, B.A.Sc., C.B., C.M.G., D.S.O.

PROFESSOR G. H. NEEDLER, PH.D.

PROFESSOR GEORGE M. WRONG, LL.D.

General Editor: W. S. WALLACE, M.A., Librarian of the University

THE BEHAVIOR OF CALCIUM PHOSPHATE AND CALCIUM CARBONATE (BONE SALTS) PRECIPITATED IN VARIOUS MEDIA, WITH APPLICATIONS TO BONE FORMATION.

[Reprinted from BIOLOGICAL BULLETIN, Vol. XLIV., No. 6, June, 1923.]

THE BEHAVIOR OF CALCIUM PHOSPHATE AND CALCIUM CARBONATE (BONE SALTS) PRECIPITATED IN VARIOUS MEDIA, WITH APPLICATIONS TO BONE FORMATION.

JAMES CRAWFORD WATT,

ANATOMICAL LABORATORY, UNIVERSITY OF TORONTO.

WITH THIRTY-EIGHT FIGURES IN THREE PLATES.

CONTENTS.

PAGE

Introduction 280
Part 1. Microscopic Study of Precipitation:
Technique 282
Reaction in aqueous solutions 283
Precipitation of calcium phosphate 283
Precipitation of calcium carbonate 284
Precipitation in colloidal solutions 284
Precipitation of calcium phosphate 285
Precipitation of calcium carbonate 285
Influence of other agents on the precipitate 288
Influence of different ions 290
Precipitation in blood serum 291
Precipitation in hyaline cartilage extract 291
Influence of hydrogen ion concentration 292
Disintegration of spherules 295
Number of forms assumed by precipitate 297
Part 2. Examination of Bone:
Technique and material 298
Results of examination of bone 300
Part 3. Discussion:
Theories regarding deposit of calcium salts 301
Reversibility of calcium reaction 305
Summary 307

INTRODUCTION.

There are at present three main theories presented in explanation of the manner in which the matrix of bone becomes impregnated with the two inorganic salts, calcium phosphate and calcium carbonate. These views may be briefly summarized as follows:

1. That the salts are deposited in the matrix by a precipitation *in situ* from the interaction of soluble salts in the blood and the tissue.

2. That the salts are excreted, or secreted, either with the matrix, or into the matrix, by the bone cells.

3. That a complex combination salt known as calcium carbonophosphate, carried in solution in the blood, is thrown out of solution in the bony matrix by a change in the carbon dioxide content of the tissue, and after precipitation is finally converted into the two components, calcium carbonate and neutral calcium phosphate, in the exact proportions found in bone.

The weight of evidence is at present in favor of the third view, especially supported by the work of Barillé and of Wells, but it seems to me that fully conclusive proof that this is the process has not yet been brought forward.

The precipitation theory, however, offers a very simple and plausible explanation, and so it was determined to investigate the behavior of bone salts on precipitation and see if any light could be shed on the actual manner of impregnation of the bony matrix.

An exact knowledge of the way in which the bone salts are added would be a great aid, indeed, to our understanding of the growth of bone, repair of fractures, changes in rickets and osteomalacia, and other kindred conditions. It would also throw light on the formation of calcareous patches in scar tissue and in arteriosclerosis, for Wells has shown that calcification and ossification are quite similar processes, and the same two calcium salts are present in both cases in exactly the same proportions.

This research work, as finally carried out, involved the microscopic study of the reactions whereby calcium carbonate and calcium phosphate were precipitated, both in separate solutions and also in the same solution, first in various aqueous media and then in certain colloidal ones. This was followed by a thorough examination of the unchanged matrix of many different bones in the mouse, the frog, the guinea pig, the dog, and human fœtuses of various ages.

"For experimental investigation of the artificial process will

furnish the best clue to a precise and certain knowledge of the natural one, by showing more clearly how much is due to physical agency"—Rainey.

PART I. MICROSCOPIC STUDY OF PRECIPITATION.

TECHNIQUE.

For simple examination of a reaction, a glass slide measuring 38 x 75 mm. was taken and on it were outlined two squares with sides of 20 mm. painted in melted paraffin, so that the wax formed the sides of a shallow cell. Into a cell were placed a small amount of the two reacting solutions to give the desired precipitate, and then a cover glass 22 mm. square was dropped on, supported by the wax cell wall. If it was desired to keep the specimen, melted wax was then painted all around the edges, and overlapping on to the cover glass. The wax was then coated with thick shellac, which in its turn overlapped slightly on to the glass. The cell was thus permanently sealed. Two cells could be made on one slide and the same reaction could be compared in distilled water and in a colloidal solution side by side.

It was found desirable to examine not only the precipitate formed immediately at the line of contact of the two reacting solutions, but also what was formed later, in more remote parts of the solution, during diffusion, and as the concentration of the dissolved salts became less and less with increasing precipitation. To do this required larger cells, and it was desirable to have a fairly uniform thickness of cell, which was accomplished as follows:

On a glass slide 38 x 75 mm. in size two thin parallel strips of mica dipped in melted paraffin were so placed as to support the long edges of a glass cover slip measuring 24 x 50 mm., which was placed upon them. These long edges were now thoroughly painted over with melted paraffin, which on hardening cemented the cover slip to the slide. A cell measuring from 0.1 mm. to 0.2 mm. deep was thus made, still open at both ends. By means of a fine glass pipette one of the reacting solutions, $M/10$ calcium chloride, was now introduced at one end until the cell was nearly two thirds filled. This end was then carefully dried and sealed with paraffin.

At the still open end was now introduced the other solution—for instance, $M/4$ sodium carbonate, or $M/4$ triple sodium phosphate—and the last border of the cell was then sealed and the slide labeled. All borders were then painted with thick shellac, which was allowed to slightly overlap the wax on to the glass.

To obtain a series of cells of uniform depth, a sheet of mica four inches by two inches in size was split until the required thickness was obtained, equal to that of a number two cover glass. It was cut across with scissors into two-inch strips about two millimeters wide. One sheet thus prepared will cut into approximately forty or fifty strips.

Cells filled with warm solutions sometimes showed broken cover glasses on cooling. Also in cells completely filled with solutions a slight amount of expansion due to change of temperature was sufficient to cause leakage by loosening the wax from the slide. And so to provide for permanency of the specimens all cells were so filled as to leave an air space to provide for contraction or expansion without undue strain, and were filled with solutions at room temperature, 20°–21° C.

Pure distilled water was used in all experiments, all solutions were filtered to make them perfectly clear, and chemically pure reagents were employed in every case.

Reaction in Aqueous Solution.

Precipitation of Calcium Phosphate.

Calcium phosphate was obtained by the interaction of $M/10$ solution of calcium chloride and $M/4$ solution of triple sodium phosphate in water. This strength of reagent gave plenty of precipitate, without it being so dense as to interfere with proper microscopic examination. As the two solutions were of different concentration, there was a different rate of diffusion on the two sides of the line of contact, with corresponding differences in rate and amount of precipitation.

Immediately that contact occurs between the two solutions a milky cloud appears, which grows rapidly in size. For a moment, although the cloud is visible to the naked eye, the solution seen microscopically is still clear, but an instant later it becomes vio-

lently agitated, and the agitation becomes quickly defined as being caused by very minute particles, which are in very rapid motion, both oscillatory and translatory. These particles, appearing only as small dots even under the highest magnification, grow in size, losing their motion as they increase in bulk, until finally they form the fine amorphous granules which gather in clumps, and masses, and fine films, to form the precipitate.

Precipitation of Calcium Carbonate.

Calcium carbonate was precipitated by the interaction of a $M/10$ solution of calcium chloride with a $M/4$ solution of sodium carbonate. The process here resembles that described above for calcium phosphate in the form of myriads of fine particles in rapid Brownian movement. All movement finally ceases as these particles agglutinate into large clumps, and then a remarkable change occurs, for the granular masses just formed fade from the sight, dissolving again into the solution, while scattered here and there larger, rapidly growing particles occur, which become defined as crystals, angular in outline, or as small spherical bodies, known as spherules, which are later converted into crystals as they increase in size (Figs. 1, 2, 3, and 25).

Two or three hours after the formation the precipitate is all crystalline. It is very rare to see a spherule persisting in pure aqueous solutions.

The appearance of precipitates of calcium carbonate in the form of spherules has been frequently noted before. As long ago as 1839 it was described by Link, who, in accordance with this phenomenon, thought that crystals at their first origin were fluid and only later became hard and angular, as solidification occurred.

Precipitation in Colloidal Solutions.

The colloids employed were gelatin and egg albumen.

Various concentrations of gelatin were experimented with, ranging from an 8 per cent. solution, which solidified quickly, to a 1 per cent. solution, which remained fluid for some time and then formed a soft jelly. As the various concentrations gave similar results the weaker ones were used as a matter of routine, being easier to handle.

For albuminous solutions Merck's powdered soluble egg albumen was employed, water being added to make the approximate normal proportions given by Lillie for fresh albumen in the hen's egg, namely, albumen 12 per cent., water 88 per cent. by weight.

In 1857 Rainey published the first of a series of papers on the precipitation of carbonate and phosphate of calcium in colloids, using gelatin, albumen, and gum arabic. His best results were obtained with gum arabic, and he pointed out that the solutions of the gum holding the two salts reacting to give the precipitate should be of very different densities, so that diffusion and the consequent reaction would occur slowly and gradually. I have found, however, with albumen and gelatin, that if the reacting salts differ sufficiently in concentration, the concentration of the colloidal solution need not differ in order to secure good reactions. And so in many series of experiments 1 per cent. gelatin was used throughout, although in others this concentration was used only with calcium chloride, and a 4 per cent. solution with sodium carbonate or phosphate. Egg albumen was used always in the same concentration.

Precipitation of Calcium Phosphate in Colloids.

The employment of a colloidal solution seems to have little or no influence on the precipitation of calcium phosphate. The deposit is quite similar to that in aqueous solutions, being fine, granular, and amorphous (Fig. 36), and aggregating to form thin gelatinous veils and clouds. Results in egg albumen were similar to those in gelatin. These findings are in agreement with the work of Rainey, Harting, Biedermann, and others.

Precipitation of Calcium Carbonate in Colloids.

The reaction here is very characteristic. Calcium carbonate formed in the presence of colloids has a tendency to separate out and persist in the form of the spherules mentioned previously, which have been named calcospherites.

The first effect of the colloid is to very much emphasize and prolong the stage in which the particles are small and show active Brownian movement, apparently by preventing their early fusion into larger masses. In a short time, however, larger particles are

seen which grow partly at the expense of the smaller ones, which redissolve as described for aqueous solutions. But there are many small particles which apparently do not dissolve, but pass on directly over to the larger form of deposit, by forming a nucleus for the laying down of additional material from the clear solution.

The precipitate exhibits two separate forms. One of these is distinctly crystalline (Figs. 8, 10, 12, 13) and is found most densely at the primary line of contact of the reacting solutions where deposit was very rapid. Even here the colloid shows its influence, for the crystals are not perfect, but are deformed in various ways, and exhibit rounded angles and suppression of their typical shape.

The second form of deposit is in the shape of very perfect small spheres (Figs. 7–12, 29, 30, 31), which vary greatly in their transparency, markings, and size according to the solution in which they are formed.

Rainey obtained spherules in gum arabic only after the lapse of an hour or more. At first a faint nebulosity was seen, lasting in thin solutions of gum for one hour, in thick solutions for over a week, after which spherules occurred. In my work I have been able to identify these bodies in less than ten minutes, and in some solutions to see them attain a size of 30 μ in one hour. They grow rapidly and attain practically their full size in forty-eight hours, ranging then according to the solution in which they lie, from a size of 1 μ up to 120 μ. In Rainey's case they grew gradually for several months and ranged in size from 2 μ to 200 μ. I had one single example of a pear-shaped body which measured 120 μ x 300 μ.

Evidently gum arabic exhibits a more powerful colloidal influence on the precipitate, but gelatin or albumen will give excellent results in a very much shorter time, which is a valuable consideration.

Brownian movement in parts of some slides is still active after the lapse of a year, due to the colloid retaining some of the precipitate in its original, extremely small, granular form, preventing coalescence to form the larger particles seen in other areas where precipitation was denser and more rapid.

The process of coalescence of the small particles can be observed in favorable cases. Very small spherules showing active move-

ment travel about in the solution, colliding with and working past others. Suddenly two of these, instead of passing, will be drawn together, as though pulled by a strong attractive force, and will merge completely in one large spherule, which in its turn may absorb small ones. At these moments of coalescence the spherules give the observer the impression of being fluid, flowing together like two drops of water, and lead one to believe that Link was correct in interpreting these small spherules as liquid crystals. As these bodies become larger they lose their movement, settle down, and become of glassy hardness. There is also a later growth by addition of material from the surrounding clear solution.

Richards and Archibald have shown that the particles of precipitates at their first appearance seem to have a rounded outline to the eye even under high magnification, but by photographs, however, they have demonstrated that these particles are real crystals of typical shape. This condition is true for some particles of calcium carbonate formed in aqueous solutions, but in colloids a great deal of the deposit is in the form of particles which are round, and persist in this shape as they grow. There are other particles also, which clearly are not round, and give the crystalline form of deposit which occurs simultaneously with the spherules.

The spherules formed in gelatin (Figs. 13 and 31) are very perfect, with a smooth surface, and clear, transparent, glassy appearance. Those formed in albumen (Figs. 26 and 29) often show a slightly irregular periphery and give indications of their internal structure. They appear to be built up of concentric layers, and often exhibit an amorphous center. Extending from this center to the periphery is also a faint, but quite distinct, radial striation in certain cases. These appearances have already been well described and illustrated by Rainey, Harting, and Biedermann.

It ought to be noted here that Harting has been erroneously credited by many writers with the discovery, in 1872, of the calcospherites formed in colloidal solutions. Rainey described and gave accurate illustrations of these bodies in 1857, and had observed them as early as 1849, and so deserves the credit of this discovery.

Combined precipitates of calcium carbonate and phosphate (Fig. 36) show each salt acting quite independently, the phosphate occur-

ring in its usual amorphous form, the carbonate in typical crystals and spherules. Similar conditions were found by Rainey in gum arabic.

The colloids gelatin and albumen were chosen as being artificial media easily prepared which might be looked on as approximately comparable respectively to the bony matrix and to the blood serum or to cellular tissues. Reactions in gelatin might give a clue to those in bone, and similarly reactions in albumen might indicate processes of calcification in other tissues. After studying the reactions in these simple media, they were further modified by the addition of various substances which are either normally or pathologically found in the blood or tissues, to see what effect these special substances would exert.

Further experiments were also carried out to study the effect of the hydrogen-ion concentration of the colloid. To complete this stage of the work reactions were followed in cartilage extract and in blood serum. Then specimens of bone from various animals were examined to see if there was any correlation between the structure of their matrix and the results obtained experimentally in the various media.

The Influence of Other Agents on the Precipitate.

The substance whose influence was to be investigated was added in equal concentration both to the sodium carbonate or phosphate, and to the calcium chloride solutions which were to react to form the precipitate. The new agent was thus balanced so that its action could not be one sided.

The agents used and their concentration in solution were:

$M/10$ sodium chloride, same proportion as in human blood serum.
0.1 per cent. dextrose, same proportion as in human blood serum (Gradwohl).
0.05 per cent. urea, same proportion as in human blood serum.
0.1 per cent. lecithin. Blood serum contains 0.7 per cent. (Wells).
1.0 per cent. acetone. Simulating conditions in acidosis.
0.5 per cent. ethyl alcohol.

The effects produced on the precipitation of calcium carbonate were quite definite for some of these substances, and in some in-

stances very remarkable changes of form resulted. The influence on calcium phosphate was much less striking, as this deposit remained in the same granular, amorphous form in all cases, and the results were mainly a slight difference in the average size of granules, and also differences in the speed and completeness of precipitation similar to those which will be noted in detail below for calcium carbonate, to which latter deposit alone the succeeding paragraphs relate.

Addition of Sodium Chloride.

The main effect noted on adding sodium chloride was the speeding up of the reaction. Brownian movement ceased sooner, crystallization was more rapid, and in most cases the main portion of the precipitate consisted of smaller crystals and spherules, and in the colloids the crystals were of very poor shape.

Addition of Dextrose.

The influence of this compound was slight and seemed to consist mostly in added transparency of the crystals and spherules. There was also slight modification in shape.

Addition of Urea.

Even in aqueous solutions some spherules were formed when urea was present. The effect in colloidal solution (Figs. 30 and 35) was to favor increase in size of the spherules, with a marked tendency toward fusion, so that many double forms and dumbbell-shaped bodies were seen. Urea thus shows an influence quite the opposite of sodium chloride upon the precipitate. It evidently favors growth of this deposit and suggests the idea that the presence of urea in blood and in urine may aid in the deposit of calcium salts in the calcareous incrustation of sclerotic arteries and the growth of renal and vesical calculi.

Addition of Lecithin.

Lecithin, even in small amounts, 0.1 gm. in 100 c.c. water gives a turbid solution even after filtering, but microscopically the solution appears clear, so that it is evidently a colloidal one.

The lecithin has a remarkable influence on the precipitation of

calcium carbonate. Even in aqueous solution (Figs. 4, 5, 6) spherules occur in great numbers, and many of these are of a large size not obtainable in other solutions. There is also a distinct tendency toward fusion of spherules in contact with each other, so that double and multiple forms are numerous. Beautiful rosettes (Fig. 5) were present, due to the adhesion of many oval-shaped bodies.

In gelatin and albumen (Figs. 10 and 11) the same phenomena occurred, producing magnificent rosettes and very large spherules measuring 120 μ in diameter.

Lecithin thus has a very typical colloidal action on the precipitate, favoring the spherical forms of deposit. This compound is found in blood in seven times the strength it was employed here, and is also found in bone and other tissues, so that its action on a precipitation of bone salts, if such occurs, ought to be appreciable. This point will be discussed later.

Addition of Acetone.

The presence of acetone (Fig. 12) hastens the process of precipitation, making it occur very rapidly, and also makes the initial deposit at the moment of contact much denser and more complete. This point is rather suggestive. It leads to the question as to whether or not conditions of acidosis such as accompany serious cases of nephritis and diabetes have an influence favoring the progress of calcification in the arteriosclerosis so often found in these cases.

Addition of Ethyl Alcohol.

The alcohol had no appreciable effect upon precipitation except to add to the optical clearness of some preparations.

The Influence of Different Ions.

The calcium carbonate was precipitated in separate cells by the carbonates of sodium (Figs. 1 and 4), potassium (Figs. 2 and 5), and ammonium (Figs. 3 and 6), so that the solutions contained the three last-named ions as the only variable, all other factors being equal. In aqueous solution the crystal form of the calcium carbonate in the three cases was noticeably different. In colloidal

solutions the spherules seen were very different in their appearances in each set of slides.

The most noteworthy change was seen where the ammonium salt was used, the deposit being much coarser, with rougher, more irregular surfaces, and as a rule much greater in size and with more tendency toward fusion and toward clumping into masses.

The whole series for each ion, including those slides with the six accessory agents described above, showed similar tendencies to the plain, unmodified reaction. Each series consisted of 21 slides, consisting of 7 in water, 7 in gelatin, and 7 in albumen.

Precipitation in Blood Serum.

Clear serum was pipetted off from test tubes of dog's blood allowed to stand for some hours in a refrigerator. The precipitation of calcium phosphate in this serum showed the usual granular amorphous character. Calcium carbonate separated out almost entirely in the form of spherules, many of which were quite large. The process of precipitation in blood serum was very complete, covered practically the whole area of the slide, and seemed to be greater than usual in amount. This appearance suggested the thought that the sodium carbonate and phosphate of the blood aided the reaction, making precipitation greater in amount, but further consideration made this seem unlikely, as the usual amount of carbonate or phosphate was added to the blood, and this alone was sufficient to precipitate more than the total amount of calcium, without the aid of the salts naturally in the blood.

Mixtures of carbonate and phosphate present the usual character, each salt being precipitated in its own peculiar form and being thus easily identified (Fig. 36).

Precipitation in Hyaline Cartilage Extract.

An extract of fresh hyaline articular cartilage was prepared by mashing it up in distilled water, allowing the mixture to stand a short time, and then filtering it and using the clear solution. The same concentrations of salts were used here as in other cases, but the resulting precipitate was very much less in amount. Precipitation occurred only in the area of contact of the solutions, was in

a finely divided state, showed some tendency to form crystals, but mostly was in form of granules and very small spherules. There were no large spherules whatever. The total amount of deposit would lead one to think that very weak solutions had been employed instead of the usual ones.

Hyaline cartilage extract thus seems to decrease the amount of precipitation and to retain what deposit is formed in a very finely divided state. Addition of the various accessory substances used in previous cases had no effect, even lecithin apparently being powerless to produce the large spherules.

These facts may have some significance, for here we have an extract of a tissue which although apparently similar to other cartilage which does ossify, and although situated in continuity with ossified tissue, yet retains a matrix free from a deposit of calcium salts. Its extract forms the most unfavorable medium yet found in which to produce precipitation of calcium salts. Solutions of equal concentration in other media give three to four times the amount of precipitate found here. The experimental facts, it seems, are in complete accord with the nature of the tissue, which is unfavorable to the deposition of calcium salts in it.

Influence of Hydrogen-Ion Concentration.

Loeb's method was employed of treating gelatin to obtain it with a definite hydrogen-ion concentration. To 0.25 gm. gelatin in a test tube were added 20 c.c. of cold acid solution of a definite strength, and this was allowed to stand for 30 minutes, during which time the gelatin swelled remarkably, but did not dissolve. It was then filtered and washed on the filter paper four times with 25 c.c. of cold distilled water at 5° C. to remove all free acid.

The gelatin was then transferred to a test tube standing in hot water, where it melted, and the volume was made up to 25 c.c. with hot distilled water, thus giving a one per cent. gelatin solution. Two tubes for each strength of acid were prepared. On cooling the pH of each pair was determined approximately by Clark's colorimetric method, and then one tube of the pair was rendered a $M/10$ calcium chloride solution, and the other one a $M/4$ sodium carbonate solution, and these two solutions were placed as usual in a cell to react.

There was also an alkaline series made similarly to the above. In each series there were ten grades as follows:

Acid series treated with $\frac{1}{16}, \frac{1}{32}, \frac{1}{64} \cdots \frac{1}{8192}$ HCl.

Alkaline series treated with $\frac{M}{16}, \frac{M}{32}, \frac{M}{64} \cdots \frac{M}{8192}$ NaOH.

The pH of the acid series of washed gelatins in one per cent. solution ranged from 3.2 to 6.0. Untreated gelatin, both in sheets and in powder, which had been used for all the previous experiments was found to possess a pH of 6.0.

The weakest alkaline member of the series registered 6.2 and the fifth member of the series a pH of 9.0, above which no record was kept.

The amount of precipitate visible to the naked eye was less in the acid series than the alkaline one. It was least of all in those specimens where the pH was in the neighborhood of the isoelectric point of gelatin, which occurs in the acid series at 4.7, and which marks the point where the gelatin is most insoluble and most inert. In these slides there was practically no diffusion and spreading of the precipitate, only a narrow band of deposit occurring along the line of contact of the reacting solutions. Such a condition would lead one to infer that the salts in solution are intimately bound to the gelatin.

It was also noted that crystals (Figs. 17, 18, 19) were abundant, and very often large, in the various acid gelatins. Crystals were also present in the weaker alkaline specimens, but in gelatin treated with $M/2048$ NaOH or stronger alkaline solutions (Fig. 23) not a single crystal has yet appeared in a period of six months since the preparation of these slides. Here the precipitate is still in the form of very small spherules, often so densely packed as to prevent Brownian movement, but elsewhere still actively in motion, which has gone on continuously for six months without a change, and gives every indication of continuing indefinitely. The larger of these spherules, approaching one micron in diameter, have a slow movement and so can be well observed, and have given definite proof of what was already suspected from a study of other slides,

namely, that the so-called spherules are in reality flattened discs. During their vibratory movement many of them have been observed to slowly roll over and a narrow, thin edge is presented to the view instead of the circular outline. The appearance reminds one very strongly of a red blood corpuscle.

The largest and clearest spherules (Figs. 19–22) were formed in gelatin whose pH was between 4.7 and 7.5—that is, all in gelatin on the alkaline side of the isoelectric point—but in specimens whose reaction was either weakly acid or weakly alkaline, the neutral point being 7.0. This is the zone in which is obtained the formation of the largest spherules. Untreated gelatin, used for all the previous series of reactions without regard to hydrogen-ion concentration, has a pH 6.0 and so is within this zone. The pH of human blood and many tissues also lies in the alkaline part of this zone.

It is interesting to note that in strong acid members of the series precipitation is rapid, and while spherules may early be present, the deposit in the course of a short time becomes entirely crystalline in structure. In strongly alkaline members precipitation is very complete, but the deposit remains for an indefinitely long time in the form of small, discrete spherules, which do not grow or fuse, and which continue to exhibit Brownian movement. No crystals appear in these latter cases, even after the lapse of many months.

In the intermediate zone of weak acid, neutral, or weak alkaline gelatin both spherules and crystals appear in quantity, and the spherules are very large. In the part of this zone in which the hydrogen-ion concentration of blood and many tissues lies the deposit is mostly in the form of small spherules and the tendency to crystallization is very poor. This is essentially a colloidal phenomenon and seems significant in view of the fact that it has frequently been found that certain drugs in colloidal form have a much better therapeutic effect, have a much less damaging effect on healthy tissues, and are much more pleasant in their administration to the patient. As an example of this, compare the actions of silver nitrate and of argyrol, a colloidal silver vitellin. The colloidal preparation much more nearly approaches the condition of the tissues themselves and the reactions ought to be of a more col-

loidal character, which I have shown is the natural condition with the hydrogen-ion concentration on the basic side of the neutral point. To the acid side of this point reactions tend to the ordinary chemical crystalline variety.

Disintegration of Spherules.

A most remarkable phenomenon was observed during the last two months in some of the slides, where spherules have been observed in process of disintegration and transformation into crystals. This was first noticed in the acid gelatin series in a slide where the gelatin had a pH of 4.9 and where for the whole of six months appearance had been constant.

This case (Fig. 31) had offered one of the most perfect examples of large spherules, which were of perfect outline, glassy transparency, absolutely clear, and showing no indication at all of their internal structure. These spherules were formed in half an hour and had attained their full growth in less than two days, and for six months presented the same appearance, with no indications of a change. It happened at the end of this period that they were not examined for about one month, when it was discovered that some of them (Figs. 19 and 33) had disappeared, others were disintegrating, and all still present were opaque, while in this area which had not previously shown a single crystal there was now a number of large crystals.

Other slides were examined for similar conditions without avail, but a month later several of them showed signs of a change, and by examination of these at intervals a complete series of stages in the transformation has been obtained and a complete description of it can now be given.

The first sign of a change is in the occurrence of a very fine opaque central spot of a bluish tint (Figs. 20, 21, 24*a*, and 32) in the otherwise clear spherule. This area increases a little in extent, and the next stage then is ushered in by the appearance around this center (Fig. 24*b*) of a faint nebulous haze, which becomes more opaque and finally seems to consist of a fine radial striation (Fig. 24*c*) which extends farther and farther, until it reaches the periphery of the spherule, which is now an entirely opaque white

body. At this stage some spherules are uniformly opaque (Fig. 24*d*), others show a marked radial striation (Fig. 24*e*).

The final step in the change now occurs with a very gradual disappearance of the spherule, apparently by dissolving into the surrounding solution. It decreases in diameter and also in thickness until the remnant, diminished very much in size, appears like a nebulous ghost of the former spherule and eventually fades completely from view. During the solution the opaque center of many spherules seems to dissolve early (Figs. 24*f* and 32), converting the body into a ring.

In those cases where the spherule is uniformly opaque (Figs. 24*d* and *f*) solution is very uniform at the surface, the contour of the spherule remaining perfect while the size contracts. Where there is radial striation, however (Fig. 24*e* and *g*), the periphery dissolves unevenly, giving the spherule a rough, rather ragged surface.

Coincident with the beginning of the process of dissolving of the spherules, crystals occur in these areas which formerly were entirely composed of spherules, and which for several months' duration had not shown a single crystal. These crystals grow steadily both in size and in number (Figs. 19, 20, 21), while the spherules disappear. The passage of the material from the spherule into solution is evidently very transitory, it coming out again immediately to be deposited in the crystal.

What is the interpretation of this phenomenon? It seems to me that there is a very evident one, and that this is the same process very much delayed in starting, and very much protracted in its action, which occurs rapidly in ordinary aqueous solutions. It will be remembered that in precipitating calcium carbonate in pure water it is at first in a granular, amorphous form, which later redissolves and comes out of solution a second time as spherules and crystals, which grow rapidly, the spherules all being converted into crystals during growth.

Again in colloidal solutions the same process happens, but is delayed somewhat, taking hours or days instead of minutes. In such cases an area of spherules seen one evening after a precipitation, when examined next morning is found to consist of crystals.

Apparently in some of these cases at least, as Brownian movement ceases and the particles grow in size, the spherule is transformed directly into the crystal.

In the degeneration of the large spherule it seems to me we have a similar phenomenon to that of the other cases. The large spherules could correspond to the amorphous particles of the aqueous solution, fused into a large mass, the redissolving occurring very late to form the final crystal. There is evidently a very strong directive force toward the formation of crystals even in the colloids, and though interfered with and hindered by them for a long period, it nevertheless conquers. What it is that initiates the change after the deposit has remained stationary for many months is problematical. There was no infection in the gelatin, no change in its appearance, or any other fact to give a clue.

Some slides in other series in both gelatin and albumen also show evidence of some change in the spherules, which in view of the above facts may be expected to progress farther.

As far as I know this remarkable transformation of the precipitate has never been described before. The further investigation of this phenomenon is outside of my province and belongs to the field of physics and chemistry, where it will provide some very interesting problems which I hope some competent investigator will undertake to solve.

A second method of disintegration (Fig. 6) has also been observed in a lecithin solution, where some large spherules with very marked striation lost this striation after the lapse of several months and became dully opaque. Certain clear radii then appeared along which cleavage occurred, splitting the spherule into sectors which finally separated, giving triangular crystals.

Number of Forms Assumed by Precipitate.

It is to be remarked that in no slide was it possible, after Brownian movement ceased, to obtain only a single form of deposit. There were always two, and in many cases several forms occurring, and this applies equally to pure aqueous and to colloidal solutions. This multiplicity of form in the precipitate has also been noted by Biedermann and is due doubtless to differences in the relative con-

centration of the reacting salts and in the diffusion currents in different parts of the solution. Side by side may be found an area of crystals and of perfect spherules, or both forms may be seen mixed in one area.

In passing from the sodium carbonate end of a cell across the precipitate to the calcium chloride end there is often seen a marked change in shape of the deposit, forms present to one side of the line of contact of the two solutions not being present on the other. Spherules may occur all to the one side, but follow no rule as to which they select. Transition forms occur from one area to another. Orde found similar conditions on sectioning plugs of coagulated albumen with which he had sealed the ends of capillary tubes containing solutions which gave precipitates in the plugs when the sealed ends of the tubes were immersed in certain other solutions.

The multitude of forms exhibited in the precipitate of calcium carbonate in the slides seemed remarkable, but on referring to Goldschmidt's "Atlas der Krystallformen," I found illustrations for 2,544 modifications of the crystal form of calcite which have already been observed. Many of the changes are slight, but all are quite evidently different, and among them may be recognized all the types of crystal form I have obtained. Spherules and their variations were not shown.

PART 2. EXAMINATION OF BONE.

Technique and Material.

The ordinary method of examining bone by means of very thin ground sections, or by sections cut from decalcified bone, are useless to give the structure of the matrix. A method just published by Bast, however, for the study of bone cells *in situ*, without cutting sections, is equally applicable for the examination of the matrix and was here employed.

Bast worked with the parietal and ethmoid bones of mice and young rats, rabbits, cats and dogs, the nasal conchæ of these animals, pieces of the ethmoid in man, and other bones thin enough to be transparent. These were mounted whole. The specimens were fixed in 95 per cent. alcohol, washed in water, stained for

8 hours or more in diluted aqueous solution of Gentian violet, dehydrated in alcohol, cleared in benzol, and mounted in balsam.

To stain the bone cells only, the periosteum was left on the specimens, and this was later removed by dissection under a binocular microscope while the bones were in benzol. In this way the matrix remained clear, while if the periosteum was removed previous to staining, the matrix stained also.

This method was used by me, but as the matrix was the main object of study, most of my preparations were not stained, but were mounted for observation clear, in three different ways: first, without fixation, in a shallow cell filled with normal saline; second, in a shallow cell of glycerin; and third, fixed in 95 per cent. alcohol, then absolute alcohol, cleared in benzol, and mounted in balsam.

A cover glass to which some of the precipitate of calcium carbonate was adherent in the form of both spherules and crystals was passed through all the processes necessary to staining above and mounted in balsam. There was no change to be seen in the precipitate, so it can be inferred that calcium salts in the bony matrix, if in this form, would not be altered by any of the processes.

The specimens of bone used were parietal and ethmoidal bones and nasal conchæ of the mouse, frontoparietal bones of the frog, and splinters and thin sections in various planes from the femur, tibia, humerus, radius, ulna and scapula, of frog, mouse, guinea pig, dog, and human fœtus. The frog and mouse were young, so that their bones were in process of growth, and if there is any visible difference between new formed and old matrix it should be evident here. Thin pieces of the long bones cut with a sharp knife to take in areas of the total thickness of the shaft, or to show transition from the bony shaft to the cartilaginous epiphysis, were taken, splinters were clipped off long bones, small pieces were crushed, and all these were mounted as described above. The whole of a concha, scapula or parietal, if small, was mounted as one specimen.

In all cases the periosteum was carefully peeled off and was mounted alongside of the bone so that examination of it for newly formed matrix could also be made.

Results of Examination of Bone.

Both bright and dark field illumination were employed and specimens of bone, when thin, were quite transparent and easily examined. In bone that is well formed, whether from adult, or young individual, or fœtus, the appearances are similar. The bone cells and all their processes in the canaliculi are easily followed and appear as Bast has described them. The matrix round about them is homogeneous, transparent, and almost glassy in appearance, and gives no indication (Fig. 37) of being formed of separate particles. If it was originally formed in such a manner, there has been complete fusion, so that there is no evidence of a precipitation. In fact, the whole appearance bears out the statements of text-books of histology that, although two thirds of the bony matrix is composed of inorganic salts, they are so intimately blended with the organic material that there is no visible evidence of their presence.

In the case of growing long bones, such as those of the limbs, sections were taken across the shaft to include the newly formed growing periphery just under the periosteum, and also sections in the length of the bone to include the end of the diaphysis, the epiphyseal plate of cartilage, and the bony epiphysis. These sections, however, were disappointing, as even at the transitional areas any tissue that could be identified as bony matrix appeared homogeneous, so that no evidence of precipitation could be obtained here.

In the case of the developing diaphysis of the long bones of the limbs in human fœtuses, however, there were definite, discrete particles to be seen. In Quain's Anatomy there is a fine description by Schäfer of the appearances of developing bone with which my findings entirely agree. Just ahead of the advancing bone of the diaphysis is an area of change, where the tissue is no longer cartilage, but is not yet true bone. Here we find definite fibres (Fig. 38) like those of white fibrous tissue, and known as Sharpey's fibres, extending from the bony material forward into the cartilage, and in these fibres in the narrow area immediately in advance of the true bone are numerous very fine granules which appear similar to the material of the matrix in well-formed bone and so are evidently the bone salts. They are crowded in the fibres just ahead of the actual bone, and in the bone itself we find

the homogeneous appearance due to the fusion of these discrete particles into one mass. Pacchioni has also described the first appearance of lime salts in bone in the form of fine granules which later form a homogeneous mass.

The possible origin of these particles either by precipitation or secretion will be discussed later.

PART 3. DISCUSSION OF RESULTS.

Concerning some of the physical phenomena of the precipitation reactions studied, remarks have been made at appropriate places in the previous pages describing the work and need not be repeated here.

There are a few points to be constantly borne in mind in considering the question of ossification, which have been very clearly demonstrated by Wells. The most important is the fact that there is a very definite and fixed ratio between the amount of calcium carbonate and calcium phosphate deposited in bone. The second point is that this same ratio is equally true in areas of calcification in tissues other than bone. The third fact is that the processes of ossification and of calcification are essentially the same, the kind of matrix or tissue in which the deposit occurs differentiating the two processes.

Theories Regarding Deposition of Calcium Salts.

The reactions with calcium phosphate show it to be invariably precipitated in a granular form so that if it were visible in bone it should be evident in a finely divided amorphous form. As this salt forms over eighty per cent. of the inorganic material, it ought to be readily demonstrated, but this is not the case, because the matrix is clear and homogeneous, not granular, except at the advancing edge of ossification in developing fœtal bones.

It has been shown that in mixed solutions calcium carbonate is not prevented, by the presence of the phosphate, from coming out in typical spherules or crystals, so that it might be expected that the carbonate would show in one of these forms in bone, in which it forms fifteen per cent. of the salts. This expectation is further strengthened by the fact that typical spherules have been found in the shells of invertebrates, which are mostly calcium carbonate, by

Rainey and by Biedermann. The dentine and enamel of the teeth, Rainey believed he had demonstrated to be composed of spherules, forming in rows and coalescing. Neither in old bone nor in new, nor in a transitional area transforming from cartilage to bone, have I seen either a single crystal or a single spherule.

Previous work has demonstrated that spherules can always be found in calcium carbonate precipitated in colloids. This formation is favored by the occurrence of the reaction gradually and slowly, and also by the presence of lecithin, which is found in both blood and bone, so that all the conditions in the matrix of the bone are favorable to the formation of spherules if precipitation occurs. The hydrogen-ion concentration is also favorable to formation of large spherules. With optimum conditions for their occurrence, and with a complete absence of these bodies, the interpretation is that the salts found in the bony matrix are not deposited in it by simple precipitation from a double decomposition of salts in the blood or the tissue. This is purely negative evidence, which, of course, is not of the same value as positive evidence, but it seems to me forms a very strong point against the simple precipitation theory.

It must be noted, however, that if calcium carbonate is very small in amount compared to the amount of phosphate precipitated that spherules may not be in evidence, but the whole precipitate will be granular, with coarser granules, resembling minute spherules and interpreted as carbonate interspersed among the masses of finer granules formed by the phosphate. It must be emphasized that homogeneous masses such as seen in the bony matrix never occurred in any of my experiments, but precipitates, no matter how long they were kept, remained composed of distinct discrete particles.

Another point against this theory is that it supposes that a soluble salt of calcium circulates in the blood to be precipitated as phosphate and carbonate in the bone. With the large amount of sodium carbonate and sodium phosphate in the blood, calcium carbonate and phosphate should be formed at once, here and not in the bone. But calcium is present in the blood in a greater amount than calcium carbonate and calcium phosphate are soluble in water.

And so it might appear that calcium can not be carried in the blood in the form in which it is later deposited in the bone. Pauli and Samec, however, have shown that difficultly soluble salts like calcium carbonate may have the amount of their solubility in water increased to over seven-fold in an albuminous solution, and so it is possible that the bone salts, formed by interaction of the blood salts and calcium absorbed into the blood as calcium chloride, might still be carried in solution in the blood and deposited in the bone.

This is closely related to the views of Barillé, whose theory is a step in advance of this, and is strongly supported by such work as that done by Wells. According to this view the calcium is in the blood in the form of a double salt formed here, tribasic calcium carbonophosphate, $P_2O_8Ca_2H_2 : 2CO_2(CO_3H)_2Ca$. This is soluble in the blood concentration of carbon dioxide. Infiltrating tissues like the bony matrix where the carbon dioxide content is lowered, this is precipitated and immediately breaks up into calcium carbonate and dicalcium phosphate, which latter salt is converted into calcium phosphate, giving the final proportion found in bone of 15 parts calcium carbonate to 85 parts phosphate. Even by this method of precipitation, however, one might expect to be able to see the salts in the matrix, and not being able to do so argues in favor of their being combined with the matrix. The most important point brought out in this theory is a clear consistent explanation supported by experimental evidence, as to the fixed proportion in the amount of the two calcium salts, the carbonate and phosphate, which is always found in their deposition.

It is interesting to note here the following facts regarding cartilage. Wells has shown that there is an almost specific power in cartilage for the absorption of calcium salts. My work is in agreement with this, for in cartilage extracts there was obtained the least amount of precipitation obtained in any of the experiments, thus showing the power of the substances in cartilage to hold on to the calcium. In spite of this affinity for calcium, however, microscopic evidence of developing ossification in bones preformed in cartilage shows us that the deposition of calcium is never directly in a cartilaginous matrix, but that the cartilage preceding the bone is destroyed and replaced by the organic bony matrix which is of

a fibrous character, and this then has the calcium salts deposited in it.

The final possible explanation of the deposit of bone salts in the matrix is the secretory one. Wells and others have been forced to the conclusion that there is a selective or specific action of tissues, such as cartilage or membrane about to ossify, by which calcium salts are absorbed or otherwise taken into them, while apparently entirely similar areas of cartilage and membrane do not ossify at that time or at any later time. From this view of selective action it is not a far step to that of secretory action, explaining the ossifying process as a secretion of the calcium salts by the bone forming cells. It is already generally admitted that the matrix is a product of the bone cells, and if this is true, it is quite logical to assume that the calcium salts are taken by the bone cells from the blood and passed on into the matrix.

The difficulty in this theory has been to account for the amount of phosphate in the tissues. The calcium was looked upon as being derived from that carried in the blood, but the phosphate was explained as being due to cellular activities, derived either from the nucleus or from cellular degeneration. Another difficulty here, again, is to explain the fixed ratio of carbonate and phosphate. This, of course, could be looked upon as due to the carbon dioxide content of the tissue, or as due to the activity of the cell, a definite proportion being found in the secretory products here just as in other organs of the body.

It seems to me, however, that the nearest approach to the truth is to be obtained by combining two views. The bone salts, I believe, reach the tissue as the soluble double salt, tribasic calcium carbonophosphate, which by its constitution provides for the tissue both calcium carbonate and calcium phosphate, each salt in the proper proportion found in bone. I do not believe, however, that deposit here is by precipitation, for in the bone, owing to the colloidal matrix, the hydrogen-ion concentration, and the presence of lecithin, all conditions are most favorable to a visible and characteristic precipitate, showing granules and spherules, but there is no visible evidence whatever of these bodies. The only evidence in favor of precipitation consists of the following two sets of facts:

First, Schäfer and Pacchioni have described the first appearance of bone salts in developing bone in the form of minute granules which quickly coalesce. This I have confirmed. This evidence could also be interpreted as showing the presence of the salts to be due to secretory activity. Secondly, Olivier in a tumor of the breast and Pettit in a tumor of the maxilla and also in a renal cyst saw and made illustrations of calcospherites. These bodies can be explained only as a precipitation phenomena, but they do not afford sufficient evidence to prove that this is the process whereby the bone salts are deposited. And so these salts, after reaching the bone in correct proportions as the double salt above mentioned, must be deposited in the matrix by some more subtle process than ordinary precipitation.

Here we have recourse to the secretion theory. The bone salts in their proper proportions having been brought to the cell by the blood, are taken by the cell and secreted as an integral part of the matrix in combination with the ossein, the organic base, which it is generally admitted already, is a product of the cells. This will produce a matrix uniform in appearance, with salts invisible, and provides the proper proportion of each salt, as the cell is in its turn provided with the two salts in that exact amount. Histological evidence shows that the fibrous matrix appears first in the newly forming bone and impregnation with the bone salts begins immediately, the salts showing as fine granules at first, and coalescing as their quantity increases, to form a homogeneous matrix.

Reversibility of Calcium Reaction.

There seems to be evidence that this process of secretion is reversible, the bone cells being able to take up the calcium salts again. Wells and others have shown that calcium is removed from the bones in cases where there is a great demand for it in the body, as in pregnancy, or where it is being steadily lost by the body, for instance by way of a pancreatic fistula. Also, the osteoclasts responsible for the normal resorption of bone are supposed by some authors to be only osteoblasts which have changed their function. And further, where a graft of either living or dead bone, or a bone plate and bone screws are used to repair an injury, a process known

as creeping replacement occurs whereby this material is gradually absorbed and replaced by new bone. It has been shown by Gallie and Robertson that it is the osteoblasts which invade the graft, gradually absorb the old matrix and bone salts immediately surrounding them, and then replace this by newly formed substance.

If the bone salts were laid down by precipitation of tribasic calcium carbonophosphate due to a change of the carbon dioxide content, it seems to me it would be impossible for this precipitate to be removed again as easily as Wells states it is, in response to the body's need for calcium. Would pregnancy or a pancreatic fistula so change the carbon dioxide content of the bone, as to make possible a reversal of the conditions that brought about the precipitation, and so either provide for increased solubility of the two salts or else make possible the recombination of the carbonate and phosphate of calcium into the double salt, with its consequent solution and carrying off in the blood?

It seems to me that the carbon dioxide content in the bone will not vary enough to permit of such a reversal, as to raise it would indicate a high activity in a tissue whose metabolism is low. This low-grade activity is given as a reason for obtaining the precipitate.

The taking of the calcium salts out of the bone probably depends on some balance that has to be maintained between the blood, the osteoblast, and the bony matrix. If the blood is rich in calcium, the cell can take it and pass it on into the matrix. If the blood is poor in calcium, the cell to maintain its relation in balance to the blood takes from the matrix to add to the blood. This is an instance comparable to the relations between the blood and its dextrose, and the liver cell and its stored glycogen, to maintain a certain carbohydrate balance.

This view also follows logically upon that of Wells, who regards the bony matrix as a great reserve store of alkaline bases for the body, where the calcium salts are in a state of flux, being constantly added to or drawn upon according to the needs of the body. Changes in the bones are much greater in extent and more rapid in their occurrence than is generally believed. It seems to me that this idea of the reversibility of the direction in which calcium salts

pass through the tissues is a most valuable one for the proper comprehension of some of the processes of growth, repair of fractures, and changes going on in rarefaction of bony tissues.

Summary.

1. Calcium phosphate precipitated in water or in colloidal solutions is constantly granular and amorphous in character, and apparently uninfluenced by the nature of the solution.

2. Calcium carbonate precipitated in water shows a great diversity of crystalline form; in colloidal solutions it shows two main forms, an irregular crystalline one and a spherical.

3. Mixtures by simultaneous precipitation of both salts in the same solution show each salt separating out independently and the part of the deposit formed by each can be easily identified.

4. Spherule formation by calcium carbonate is a typical reaction in colloidal solutions.

5. Spherules and crystals are influenced in shape, size, number, and internal structure by a variety of substances found normally or pathologically in the blood, most notably by lecithin which favors the formation of large spherules, and by acetone which increases the rapidity and extent of precipitation.

6. The character of the deposit of calcium carbonate is influenced by the hydrogen-ion concentration of the colloidal solution, being most crystalline in acid media, all in the form of spherules in strongly alkaline media, and mixed in form in solutions neutral or nearly neutral.

7. Large spherules, after persisting for months may undergo a sort of degenerative process, with change of internal structure, after which they dissolve and the material forming them is laid down in a crystalline form. As far as I know this phenomenon has never been previously described.

8. In fresh bone of various animals examined in various ways there is no visible microscopic evidence of the bone salts, although they form two thirds of the mass of the matrix. The inference is that the bone salts are not deposited in the matrix by simple precipitation, for the conditions are such that, if precipitated, granules, spherules, and crystals should be visible.

9. In the rapidly developing fœtal skeleton the first appearance of bone in the matrix is in the form of fine granules or globules which quickly fuse or coalesce to form a homogeneous mass. This might be interpreted according to the bias of the observer as supporting evidence either of precipitation or of secretion of the salts into the matrix.

10. The view advanced by Barillé and supported by Wells's work, that calcium is carried in the blood as tribasic calcium carbonophosphate, is probably correct, as it furnishes the bone salts in the proper proportion, but their view of its deposit in the matrix as a precipitate due to change in concentration of carbon dioxide does not appear correct in view of the fact that no precipitate of the bone salts is visible.

11. The theory that the salts furnished by the blood are taken by the bone cells and secreted by them along with the matrix seems reasonable in view of the condition found in the matrix.

12. The action of the osteoblasts seems to be reversible, they being able to absorb or take up the calcium salts again out of the matrix.

In concluding this paper I wish to acknowledge my indebtedness to others by thanking Professor J. Playfair McMurrich for special apparatus and for valuable references, also the following for providing material for investigation: Professor W. H. Piersol, Dr. R. D. Defries, Dr. Banting, Dr. Simpson, Dr. Dafoe, and Dr. Low.

BIBLIOGRAPHY.

Barillé, A.

'04 De l'action de l'acide carbonique sous pression sur les phosphates métalliques; combinaison (carbonophosphates) ou dissolution, applications diverses. Journ. de Pharm. et de Chimie, Ser. 6, T. 19, p. 14, 71, 196, 245, 295.

'10 Rôle des constituants de la dissociation de la carbonophosphate tricalcique dans la genèse du tissu osseux et des diverses concrétions à base de phosphate et de carbonate de calcium. Journ. de Pharm. et de Chimie, Ser. 7, T. 1, p. 342.

Bast, T. H.

'21 Studies on the Structure and Multiplication of Bone Cells facilitated by a new Technique. Amer. Jour. of Anat., Vol. 29, pp. 139–157.

Biedermann, W.

'02 Ueber die Bedeutung von Krystallization prozessen bei Bildung der Skelette wirbelosser Tiere, namentlisch der Molluskenschalen. Zeitschr. für allgemeine Physiol., Bd. I., S. 154–208.

'02 Untersuchungen über Bau und Entstehung der Molluskenschalen. Jenaische Zeitsch. für Naturwiss., Bd. XXXVI., S. 1–164.

Bowman J. H.

'06 A Study in Crystallization. Journ. of Soc. of Chem. Indust., Vol. 25, p. 143.

Clark, W. M.

'21 The Determination of Hydrogen Ions. Williams and Wilkins Co., Baltimore.

Gallie, W. E., and Robertson, D. E.

'18 The Transplantation of Bone. Journ. of Amer. Med. Ass., Vol. 70, pp. 1134–1140.

'19 The Repair of Bone. Brit. Journ. of Surg., Vol. VII., No. 26, pp. 211–216.

Goldschmidt, V.

'13 Atlas der Krystallformen. Vol. 2 and Atlas Vol. 2. Winters, Heidelberg.

Gradwohl, R. B. H., and Blaivas A. J.

'20 The Newer Methods of Blood and Urine Chemistry. 2d Edition. C. V. Mosby Co., St. Louis, U. S. A.

Harting, —.

'72 On the Artificial Production of some of the Principal Organic Calcareous Formations. Quart. Journ. Micros. Science, New Series, Vol. XII., pp. 118–123.

Holmes, H. N.

'17 The Formation of Crystals in Gels. Journ. of Physical Chem., Vol. XXI., pp. 709–733.

Lillie F. R.

'08 The Development of the Chick. Henry Holt and Co., New York.

Link, H. F.

'39 Ueber die erste Entstehung der Krystalle. Annalen der Physik und Chemie. Poggendorf, Bd. 46, S. 258.

Loeb, Jacques.

'18 Amphoteric Colloids, I.–V. Journ. of Gen. Physiol., Vol. I. I. Chemical Influence of the Hydrogen Ion Concentration, p. 39. II. Volumetric Analysis of Ion Protein Compounds; the Significance of the Isoelectric Point for the Purification of Amphoteric Colloids, p. 237. III. Chemical Basis of Influence of Acid upon the Physical Properties of Gelatin, p. 363. IV. The Influence of the Valency of Cations upon the Physical Properties of Gelatin, p. 483. V. The Influence of the Anions upon the Physical Properties of Gelatin, p. 559.

Loeb, Jacques.

'20 Ion Series and the Physical Properties of Proteins. Journ. of Gen. Physiol., Vol. 3, p. 85.

'20 The Proteins and Colloid Chemistry. Science, New Series, Vol. LII., No. 1350, pp. 449–456.

Olivier, E.

'95 Cancer gelatineux du Sein avec Corps Calcaires. Beitr. zur Path. Anat. und zur Allgem. Pathol., Bd. XVII.

Ord, W. M.

'72 On Molecular Coalescence and on the Influence of Colloids upon the Forms of Inorganic Matter. Quart. Journ. Micros. Science, Vol. XII., pp. 219–239.

Pacchioni D.

'02 Untersuchungen über die normale Ossification des Knorpels. Jahrb. f. Kinderheil. Berl., Bd. LVI., S. 327–340.

Pauli. W., und Samec, M.

'09 Ueber Löslichkeitsbeeinflussung von Electrolyten durch Eweisskörper. Biochem. Zeitschr., Bd. 17, S. 235–256.

Pettit, A.

'97 Sur le Rôle des Calcospherites dans la Calcification a l'Êtat Pathologique. Arch. d'Anat. Micros., T. 1, p. 107.

Rainey, George.

'57 On the Formation of the Skeletons of Animals, and other Hard Structures formed in Connection with Living Tissues. Brit. and Foreign Med. Chir. Review, Vol. XL., p. 343.

'58 Precise Directions for making of Artificial Calculi, with some Observations on Molecular Coalescence. Quart. Journ. Micros. Sci., Vol. VI., pp. 41–50.

'59 On the Structure and Mode of Formation of the Dental Tissues, according to the Principle of Molecular Coalescence. Quart. Journ. Micros. Sci., Vol. VII., pp. 212–225.

'61 Some Further Experiments and Observations on the Mode of Formation and Coalescence of Carbonate of Lime Globules, and the Development of Shell Tissues. Quart. Journ. Micros. Sci., New Series, Vol. 1, pp. 23–32.

Richards T. W., and Archibald, E. H.

'01 A Study of Growing Crystals by Instantaneous Photomicrography. Amer. Chem. Journ., Vol. XXVI.

Schäfer, E. A.

'12 Text-book of Microscopic Anatomy. Quain's Elements of Anatomy, Eleventh Edition, Vol. II., Pt. I. Longmans, Green and Co., London and New York.

Wells, H. G.

'06 Pathological Calcification. Journ. Med. Research, Vol. XIV. (N. S., Vol. 9), p. 491.

'10 Calcification and Ossification. Harvey Lectures, 1910–11.

'11 Calcification and Ossification. Arch. of Int. Med., Vol. VII., p. 721.

'18 Chemical Pathology. Third Edition. W. B. Saunders and Co., Philadelphia and London.

EXPLANATION OF PLATES.

PLATE I.

All figures are from camera lucida tracings and are of equal magnification, × 200, so that the relative size of precipitated particles in each case can be compared. Only forms which were common, and appeared in quantity have been shown.

All illustrations are to show forms assumed by calcium carbonate precipitated from various solutions by the reagents listed below.

FIG. 1. Crystals of calcium carbonate precipitated by sodium carbonate in distilled water.

FIG. 2. Crystals of calcium carbonate precipitated by ammonium carbonate in distilled water.

FIG. 3. Crystals of calcium carbonate precipitated by potassium carbonate in distilled water.

FIG. 4. Deposit of calcium carbonate precipitated by sodium carbonate in distilled water containing 0.1 per cent. lecithin. Note small spherules, and small crystals, a tendency towards clumping, a very large spherule and a large rosette.

FIG. 5. Deposit of calcium carbonate precipitated by ammonium carbonate in distilled water containing 0.1 per cent. lecithin. Spherules of various sizes, a marked tendency to fusion, and formation of large irregular masses are to be noted.

FIG. 6. Deposit of calcium carbonate precipitated by potassium carbonate in distilled water containing 0.1 per cent. lecithin. Note a tendency to clumping, various sizes of spherules with some double forms. The last three forms indicate one process of disintegration of a spherule, by the occurrence of radial lines along which it splits into sectors, which thus become triangular crystals.

FIG. 7. Deposit of calcium carbonate precipitated by sodium carbonate in a solution of egg albumen. Practically the whole precipitate was in form of spherules.

FIG. 8. Deposit of calcium carbonate precipitated by ammonium carbonate in a solution of egg albumen. Spherules of varying size are seen, also some crystals.

FIG. 9. Deposit of calcium carbonate precipitated by potassium carbonate in a solution of egg albumen. Many spherules are seen, and a tendency towards fusion is noted.

FIG. 10. Deposit of calcium carbonate precipitated by sodium carbonate in a solution of egg albumen containing 0.1 per cent. lecithin. Note the markedly increased size of spherules and crystals and the tendency to fusion.

FIG. 11. Deposit of calcium carbonate precipitated by ammonium carbonate in a solution of egg albumen containing 0.1 per cent. lecithin. Note the increased size of particles, and their tendency to fuse.

FIG. 12. Deposit of calcium carbonate precipitated by potassium carbonate in a solution of egg albumen containing 1 per cent. of acetone. Crystals and spherules both occur. One crystal is seen fused with a spherule.

FIG. 13. Deposit of calcium carbonate by interaction of calcium chloride in a 1 per cent. gelatin solution with sodium carbonate in a 4 per cent. gelatin.

Fields are shown by various sized spherules, of crystals, and of spherules and crystals mixed.

FIG. 14. Deposit of calcium carbonate by interaction of calcium chloride in 1 per cent. gelatin solution with ammonium carbonate in 4 per cent. gelatin solution. Spherules of various sizes are seen.

FIG. 15. Deposit of calcium carbonate by interaction of calcium chloride in 1 per cent. gelatin solution containing 0.1 per cent. lecithin, with ammonium carbonate in 4 per cent. gelatin solution containing 0.1 per cent. lecithin. Note the increase in size of the spherules over those shown in Fig. 14. Three different degrees of fusion are illustrated in the double forms.

FIG. 16. Deposit of calcium carbonate precipitated by sodium carbonate in a 1 per cent. solution of untreated gelatin.

FIG. 17. Deposit of calcium carbonate precipitated by sodium carbonate in a 1 per cent. solution of gelatin previously treated with $\frac{1}{16}$ HCl solution. Large crystalline precipitate.

FIG. 18. Deposit of calcium carbonate precipitated by sodium carbonate in a 1 per cent. solution of gelatin previously treated with $\frac{1}{32}$ HCl solution. Large, markedly crystalline deposit.

FIG. 19. Deposit of calcium carbonate precipitated by sodium carbonate in a 1 per cent. solution of gelatin previously treated with $\frac{1}{512}$ HCl solution. The field shown in this figure was composed for some months altogether of clear spherules and a few dumb-bells. The spherules here illustrated are now undergoing disintegration and in their place are appearing large crystals. Some debris is seen in one corner. One spherule is seen partly from the side, showing its true shape to be a disc.

FIG. 20. Deposit of calcium carbonate precipitated by sodium carbonate in a 1 per cent. solution of gelatin previously treated with $\frac{1}{2048}$ HCl solution. Disintegrating spherules and new crystals are seen.

FIG. 21. Deposit of calcium carbonate precipitated by sodium carbonate in a 1 per cent. solution of gelatin previously treated with $M/8192$ NaOH solution. Newly formed crystals and various stages of disintegrating spherules are shown.

FIG. 22. Deposit of calcium carbonate precipitated by sodium carbonate in a 1 per cent. solution of gelatin previously treated with $M/4096$ NaOH solution.

FIG. 23. Deposit of calcium carbonate precipitated by sodium carbonate in a 1 per cent. solution of gelatin previously treated with $M/2048$ NaOH solution. Precipitate is all in the form of small spherules which have been in constant Brownian movement for six months.

FIG. 24. A series of spherules showing various stages in the disintegrative changes which occur before they redissolve. *a*, Spherule with small central opaque area. *b*, Spherule with opaque radial striation extending from central spot. *c*, Spherule with further extension of opaque area. *d*, Spherule almost completely opaque. Narrow, bright, clear periphery. *e*, Spherule striated right out to periphery. *f*, Spherule like that in *d*, dissolving both at periphery and in center in a regular manner. *g*, Spherule like that in *e*, dissolving at an irregular rate at the periphery. *h*, *j*, Remains of dissolving spherules, and debris of some that have fallen apart.



J. C. WATT.

PLATE 2.

Photomicrographs all taken at a standard magnification, × 200, with dark field condenser in use.

FIG. 25. Crystals of calcium carbonate precipitated by ammonium carbonate in water.

FIG. 26. Calcium carbonate precipitated by sodium carbonate in a solution of egg albumen containing $N/10$ sodium chloride.

FIG. 27. Calcium carbonate precipitated by potassium carbonate in water containing 0.1 per cent. lecithin. Note one double spherule and three large single spherules of which the two larger show indications of the radial divisions which will result in splitting the spherule into crystals of triangular outline. Many small crystals and spherules seen.

FIG. 28. Calcium carbonate precipitated by ammonium carbonate in water containing 0.1 per cent. lecithin.

FIG. 29. Calcium carbonate precipitated by potassium carbonate in a solution of egg albumen containing 1 per cent. ethyl alcohol.

FIG. 30. Calcium carbonate precipitated by potassium carbonate in a solution of egg albumen containing 0.05 per cent. urea.

FIG. 31. Calcium carbonate precipitated by sodium carbonate in a 1 per cent. solution of gelatin previously treated with 1/1024 HCl solution. Clear spherules, some seen from side appearing disc-like.

FIG. 32. Calcium carbonate precipitated by sodium carbonate in a 1 per cent. solution of gelatin previously treated with 1/2048 HCl solution. Some crystals are present. Spherules begin to show an opaque central dot, the first indication of a coming disintegration.

FIG. 33. Calcium carbonate precipitated by sodium carbonate in a 1 per cent. solution of gelatin previously treated with 1/512 HCl solution. This field was formerly all spherules, now some crystals are seen. Spherules are far advanced in disintegrative process, are completely opaque, and are dissolving, some appearing only as ghosts of their former selves.

FIG. 34. Calcium carbonate precipitated by ammonium carbonate in 1 per cent. gelatin solution containing 0.05 per cent. urea. Rings and striations seen in spherules.

FIG. 35. Calcium carbonate precipitated by sodium carbonate in a 1 per cent. gelatin solution containing 0.05 per cent. urea. Field of very small mixed crystals and spherules.

FIG. 36. Combined precipitate of calcium phosphate and calcium carbonate by action of sodium phosphate and sodium carbonate in dog's blood serum. The calcium carbonate shows as seven spherules. The calcium phosphate shows as a cloud of very fine amorphous granules, which is the form in which it precipitated in all experiments.

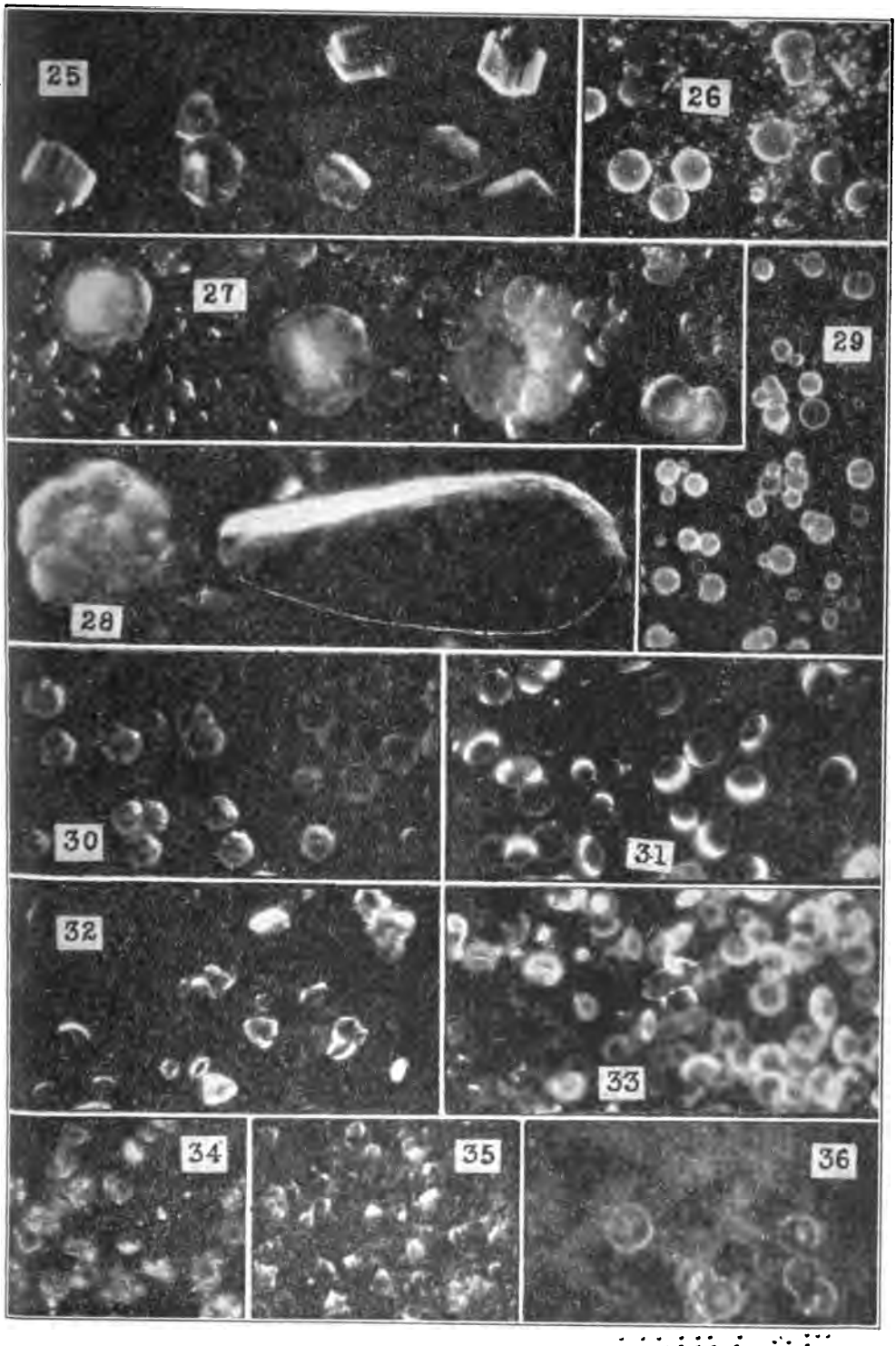

J. C. WATT

UNIV. OF CALIFORNIA

PLATE 3.

FIG. 37. Photomicrograph of a small piece of bone from the growing femur of a mouse. The bone cells show as small, oval, opaque bodies in the specimen. No discrete particles can be seen in the matrix. Magnification, × 200.

FIG. 38. Outline sketch made with camera lucida, of the growing bony end of the diaphysis of the humerus of a six months human foetus. Four zones can be distinguished. *A*, fully formed bone spicules (shown as solid black, marrow spaces white, bone and marrow cells not indicated) with calcium salts fused. *B*, osteogenic fibres, impregnated with calcium salts in form of minute granules. *C*, newly forming osteogenic fibres, not yet impregnated with bone salts, and cartilage showing changes preparatory to bone formation. *D*, unaltered cartilage. Magnification, × 300.



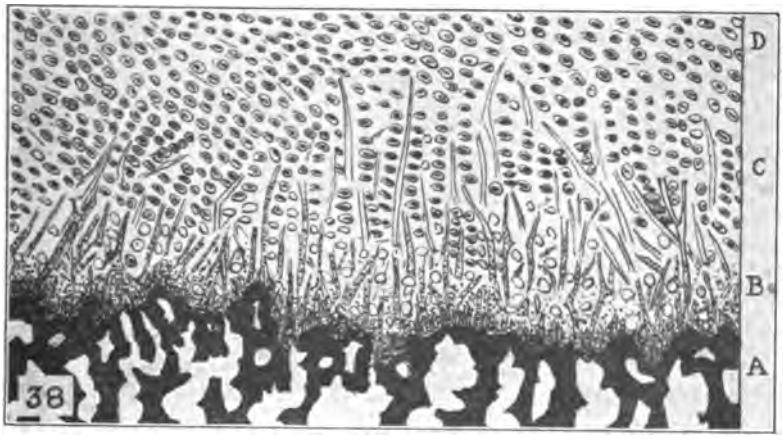

J. C. WATT.

UNIV. OF CALIFORNI

UNIVERSITY OF TORONTO STUDIES

ANATOMICAL SERIES

No. 1: The anatomy of the orang-outang, by Professor A. PRIMROSE ..... o.p.

No. 2: The skull of a human foetus of 40 mm., by CHARLES CLIFFORD MACKLIN 0.50

No. 3: Anatomy of a seven months' foetus exhibiting bilateral absence of the ulna accompanied by monodactyly, by J. C. WATT 0.50

No. 4: Symmetrical bilateral dystopia of the kidneys in a human subject, by J. C. WATT 0.25

No. 5: The terminals of the human bronchiole, by HERBERT G. WILLSON 0.50

No. 6: The behaviour of calcium phosphate and calcium carbonate (bone salts) precipitated in various media, with applications to bone formation, by JAMES CRAWFORD WATT 0.50

UNIVERSITY OF TORONTO STUDIES

ANATOMICAL SERIES

MAR 28 1926

No. 7: THE DEPOSITION OF CALCIUM PHOSPHATE AND CALCIUM CARBONATE IN BONE AND IN AREAS OF CALCIFICATION, BY JAMES CRAWFORD WATT

(Reprinted from Archives of Surgery, May, 1925, Vol. 10)

THE UNIVERSITY LIBRARY; PUBLISHED BY THE LIBRARIAN, 1925

University of Toronto Studies

COMMITTEE OF MANAGEMENT

Chairman: SIR ROBERT ALEXANDER FALCONER, LL.D., K.C.M.G.,
President of the University

PROFESSOR W. J. ALEXANDER, PH.D.

PROFESSOR J. P. MCMURRICH, PH.D.

BRIG.-GEN. C. H. MITCHELL, B.A.SC., C.B., C.M.G., D.S.O.

PROFESSOR G. H. NEEDLER, PH.D.

PROFESSOR GEORGE M. WRONG, LL.D.

General Editor: W. S. WALLACE, M.A.,
Librarian of the University

THE DEPOSITION OF CALCIUM PHOSPHATE AND CALCIUM CARBONATE IN BONE AND IN AREAS OF CALCIFICATION

JAMES CRAWFORD WATT, M.D.
Associate Professor of Anatomy, University of Toronto
TORONTO

In adult bony tissues the matrix in which the bone cells are embedded appears as a clear homogeneous mass, giving no visible indication of the large amounts of calcium carbonate and phosphate which are contained in it, although these salts form two thirds of its mass. The only visible evidence of the presence of these salts is to be found in newly forming, very rapidly growing bone in the fetus, where discrete particles, or separate granules, have been recognized. Adult bony tissues show only homogeneous fused masses.

The organic basis of the matrix consists of fibers formed by the bone cells, similar to those of white fibrous tissue. In bones preformed in cartilage, the cartilage is destroyed at the advancing edge of the bony growth and replaced by these fibers, which, immediately on their formation, begin to show a deposition of calcium salts in the form of very fine, minute granules (Pacchioni,[1] Schäfer,[2] Watt[3]). These granules show only at the extreme advancing edge of the new bone, for, as the deposit increases, the granules fuse to form a solid homogeneous mass without visible structure, right up to the line of formation of the new fibers at the growing periphery.

The fibers forming the organic matrix of the bone are admittedly a product of the bone forming cells. Uniformity of opinion, however, is absent as to the mode of deposition of the calcium salts. The granules might represent either a precipitation product or a secretory one, and three main views are advanced in explanation of the deposition of the salts. These are:

1. The salts are deposited by precipitation in the matrix of a soluble salt of calcium, such as the chlorid, by carbonates and phosphates found in the tissues.

---

1. Pacchioni, D.: Untersuchungen uber die normale Ossification des Knorpels, Jahrb. f. Kinderh. **56**:327-340, 1902.

2. Schäfer, E. A.: Quain's Elements of Anatomy, Ed. 11, London and New York, Longmans, Green & Company, 1912, **2**, pt. 1.

3. Watt, J. C.: The Behaviour of Calcium Phosphate and Calcium Carbonate (Bone Salts) Precipitated in Various Media, with Applications to Bone Formation, Biol. Bull. **44**:280-317 (June) 1923.

2. A modified precipitation theory, in which a soluble double salt, calcium carbonophosphate, is carried in the blood and precipitated in the bone by lowered carbon dioxid content in this tissue. The double salt immediately breaks up into calcium carbonate and dicalcium phosphate, the latter being quickly converted into the tricalcium phosphate.

3. The secretion theory explains the presence of the salts as being due to cellular activities. Calcium is taken from the blood and combined with the carbonate radical in the cell, or with the phosphate radical, the latter being derived from the phosphorus compounds contained in the nucleus, either as a normal cell product or as a product of degeneration.

A thorough study of the precipitation of calcium carbonate and calcium phosphate in colloids was undertaken, and fresh bone from the frog, mouse, guinea-pig, cat, dog, man and human fetus was examined to see if any evidence of precipitation was available. The results of this work have been published in full.[4]

The results of this research, briefly summarized, may be stated as follows. It was found that bone salts precipitated in colloids behave in a very definite manner. Calcium phosphate is always amorphous and granular, just as in aqueous solutions. Calcium carbonate, on the other hand, shows a very characteristic change. It has its typical crystalline shape modified or deformed, and it shows a large proportion of the particles composing the precipitate in the form of spherules, rounded bodies and circular disks (Rainey,[5] Harting,[6] Biedermann,[7] Watt[8]). In mixtures of the two salts, each is easily identified in its typical form. Accessory substances present, such as urea, lecithin, and sodium chlorid, found normally in the blood and the tissues, favor precipitation and spherule formation. The hydrogen-ion concentration

---

4. Biol. Bull., (June) 1923.

5. Rainey, George: On the Formation of the Skeletons of Animals, and Other Hard Structures Formed in Connection with Living Tissues, Brit. and Foreign Med. Chir. Review **40**:343, 1857; Precise Directions for Making of Artificial Calculi, with Some Observations on Molecular Coalescence, Quart. J. Micr. Science **6**:41-50, 1858; On the Structures and Mode of Formation of the Dental Tissues, According to the Principle of Molecular Coalescence, ibid. **7**: 212-225, 1859; Some Further Experiments and Observations on the Mode of Formation and Coalescence of Carbonate of Lime Globules, and the Development of Shell Tissues, ibid., New Series **1**:23-32, 1861.

6. Harting: On the Artificial Production of Some of the Principal Organic Calcareous Formations, Quart. J. Micr. Science, New Series **12**:118-123, 1872.

7. Biedermann, W.: Ueber die Bedeutung von Krystallization prozessen bei Bildung der Skelette wirbelosser Tiere, namentlisch der Molluskenschalen, Ztschr. f. allg. Physiol. **1**:154-208, 1902; Untersuchungen uber Bau und Entstehung der Molluskenschalen, Jenaische Ztschr. f. Naturwiss. **36**:1-164, 1902.

of the blood and the tissues favors formation of large spherules, so that the carbonate especially can be very easily identified if precipitated. Small deposits of calcium carbonate in a large amount of phosphate may fail to show as spherules, but remain in the form of coarse granules somewhat darker and differing in appearance from those of calcium phosphate. The granules always remain discrete, however, and I have never seen an example of fusion into homogeneous plates or masses such as are found in fully formed bone.

Examination of bone failed to disclose either spherules, crystals or any discrete particles of bone salts except in the rapidly growing end of fetal bones, as described above, where small particles, which quickly fused, were seen. The literature records no results of this kind except in two isolated cases of bone tumors (Pettit,[8] Oliver[9]) where some spherules were found. The conclusions to be drawn from these facts are given below.

Considering the various foregoing theories, the arguments in favor of or against them may now be considered.

PRECIPITATION THEORY

In favor of this theory is its plausibility; against it are a great array of facts. Bone salts do not take the form in the colloidal bony matrix in which they invariably appear in colloids, even in one so nearly related to bone as gelatin. There is a fixed proportion of carbonate to phosphate in bone, carbonate 15 parts, by weight, and phosphate 85 parts, as proved by Wells.[10] Precipitation will not explain this fixed proportion.

There is also no reason why the bone salts should not be formed in the blood before ever reaching the bone, from the reaction of the absorbed calcium chlorid with the blood salts sodium carbonate and phosphate. It might be argued that such insoluble salts of calcium could not then reach the bone, but it is a fact proved by Pauli and Samec[11] that the salts calcium carbonate and phosphate are soluble in an albuminous solution in seven times or more the amount of their

---

8. Pettit, A.: Sur le Rôle des Calcospherites dans la Calcification a l'Etat Pathologique, Arch. d'Anat. Micr. **1**:107, 1897.

9. Olivier, E.: Cancer gelatineux du Sein avec Corps Calcaires, Beitr. z. Path. Anat. u. z. allg. Path. **17**:640-647, 1895.

10. Wells, H. G.: Pathological Calcification, J. M. Research **14**:491, 1906; Calcification and Ossification, Harvey Lectures, 1910-1911; Calcification and Ossification, Arch. Int. Med. **7**:721 (June) 1911; Chemical Pathology, Ed. 3, W. B. Saunders and Company, Philadelphia and London, 1918.

11. Pauli, W., and Samec, M.: Ueber Loslichkeitsbeeinflussung von Electrolyten durch Eiweisskorper, Biochem. Ztschr. **17**:235-256, 1909.

solubility in water, so that they could be transported in this form in the blood. This, therefore, leads naturally to the next theory.

THE CARBONOPHOSPHATE THEORY

Barillé [12] has given fairly conclusive evidence that there is formed in the blood a salt known as tribasic calcium carbonophosphate ($P_2O_8Ca_2H_2 : 2CO_2[CO_3H]_2Ca$), which is soluble in the blood concentration of carbon dioxid. Wells believes that on coming to bone where the carbon dioxid content is low, this double salt precipitates, breaks up and finally is converted into 15 parts calcium carbonate and 85 parts calcium phosphate; experimental facts have been adduced in support of this view. The strong point of the theory is that the two salts are brought to and laid down in the bone in exactly the right proportions.

Now Wells has shown that calcium salts in bone are in a state of flux, acting as a great alkali or basic reserve, which can be drawn upon if the body needs increased calcium, as in the case of a pregnancy, or if it is losing calcium steadily, as from a pancreatic fistula. This, of course, demands some change in the condition in the bone which will operate to put the salts into solution. Unless they can dissolve directly, which is very unlikely or they would not remain deposited, then we should expect some sort of reversal of the mechanism of deposition; the carbon dioxid content of the bone would rise and the double salts be reconstituted to pass in solution out of the bone. This is a very unlikely change, as the metabolism of the bone will not change sufficiently to raise the carbon dioxid thus, the naturally low content being given as the reason for precipitation.

A second argument against deposition by this modified precipitation reaction is that crystals and spherules of calcium carbonate, or at least granules, might be expected when the double salt breaks up, but they do not appear, although conditions in the bone are at an optimum for their formation.

SECRETORY THEORY

The fine granules, the form in which the bone salts first appear in the rapidly growing osteogenic fibers, might be interpreted as a secretory phenomenon. The carbonate radical has been explained as being derived from the carbon dioxid in the tissue, the phosphate radical from nuclear activity or from phosphorous compounds freed by cellular

---

12. Barillé, A.: De l'action de l'acide carbonique sous pression sur les phosphates metalliques; combinaison (carbonophosphates) ou dissolution, applications diverses, J. de Pharm. et de Chim. **19**: 14-71, 196, 245, 295, 1904; Rôle des constituants de la dissociation de la carbonophosphate tricalcique dans la genese du tissu osseux et des diverses concretions a base de phosphate et de carbonate de calcium, J. de Pharm. et de Chim. **1**:342, 1910.

degeneration. This explanation does not account for the fixed proportions between the two salts, and it also gives an unsatisfactory origin to the phosphate radical, considering the large amount of the salt present. The secretory view does explain, however, why no precipitation phenomena are to be seen, why the salts appear in fine granules in or on the osteogenic fibers and rapidly fuse into a homogeneous and apparently structureless mass.

It seems to me that the most logical complete explanation of the deposition of the bone salts is therefore to be obtained by combining two of the foregoing views, as follows: Evidence is in favor of the calcium being carried in the blood as the soluble double salt, calcium carbonophosphate. This, I believe, correctly explains the carrying of the salts to the bone, to which it supplies both carbonate and phosphate in exactly the proper proportion. But from this stage onward, evidence is in favor of the view that this salt is taken from the blood and deposited in the bone by the action of the osteoblasts.

This view also provides for a reversibility of the direction of travel of the calcium. The cell may take up the bone salts and pass them back into the blood, a process which is well known and recognized in bone absorption. Grafts of bone, dead or living, used by surgeons in operative repairs of bone (Gallie and Robertson [13]) are invaded by osteoblasts from the healthy surrounding bone, and these cells absorb the graft and replace it by new bony tissue formed by themselves, this process being known as creeping replacement. Moreover, when the body is being robbed of its normal supply of calcium, as it is during pregnancy or in the case of a pancreatic fistula, there is rarefaction of the bones by the taking up of bone salts from them. If osteoblasts are to be given the credit for the removal of bone by "absorption," as most workers in this field have called the process, I see no reason why the reverse process of bone formation by secretion cannot also be credited to them. A further argument in support of this view is that the osteoclasts, the absorbing agents of normal bone, are believed by many to be only modified osteoblasts.

REVERSIBILITY OF THE TRANSPORT OF CALCIUM

These facts also suggest that there is maintained in the body a certain calcium balance similar in its workings to the well known carbohydrate balance. The carbohydrate balance is between the sugar content of the blood, the liver cell, and the liver's reserve store of glycogen. Sugar is removed from the blood by the hepatic cells and deposited as glycogen when the content in the blood is high. The reaction is reversed when

13. Gallie, W. E., and Robertson, D. E.: The Transplantation of Bone, J. A. M. A. **70**:1134-1140 (April 20) 1918; The Repair of Bone, Brit. J. Surg. **7**:211-261, 1919.

the blood is poor in sugar. Similarly, with a normal calcium content in the blood, the osteoblasts can obtain and deposit bone salts, but with blood poor in calcium the reaction will be reversed, salts being removed from the bone to raise the calcium content of the blood toward normal. The calcium in the bones is thus a great alkali reserve in a state of flux, with an interchange of material more frequent than has been formerly supposed, thus bringing the bones more into line with other living tissues. That bone is an active living tissue with cells full of vitality has been shown in many ways, and is being realized more and more, especially by surgeons. The old idea, that bone is an inert mass and that material once deposited in it remained for many years or until that part of the bone was destroyed in growth processes is no longer wholly tenable.

This shows the importance of keeping up a normal calcium supply in the blood in children, and in those suffering from fractures and diseases of the bones; it bears out the clinical observations that foods and medicines rich in calcium and in phosphates aid in proper skeletal development in children, and also in the repair of fractures.

DIFFERENCES IN CALCIFICATION

The foregoing views imply a vital, specific action of the osteoblasts. There is no more reason to doubt this than to doubt the specific action of any other secretory cell. A further indirect proof of this activity may be obtained by attempting a comparison of ossification with calcification. Wells states that calcium salts are deposited in identical proportions in both cases, the salts in a calcified area being exactly the same as in a bone matrix. The difference lies in the matrix, in bone being a regular system of collagenous fibers formed by the osteoblasts, in calcified areas being either old and dense, white, fibrous tissue or areas of necrosis. In all cases, the matrix for the deposit is one of low grade activity, with a small carbon dioxid content, allowing the precipitation of the carbonophosphate which infiltrates the tissue.

This view is correct as far as it goes, but it does not reach far enough. I believe calcium salts are transported as the complex carbonophosphate and so reach the area of deposit in the exact proportion in which they are found. Here, however, differences occur. The bone shows no visible evidences of precipitation. Small pieces of fresh, unaltered bone, examined microscopically by Bast's method,[14] are transparent and homogeneous, and show no discrete particles and no visible structure apart from the bone cells. Areas of calcification show a characteristic deposit which is not homogeneous. Calcified areas in arteries have an appearance as though formed of incompletely fused

14. Bast, T. H.: Studies on the Structure and Multiplication of Bone Cells Facilitated by a New Technique, Am. J. Anat. **29**:139-157 (July) 1921.

masses of granules and sometimes show irregular crystalline masses, and in one calcified pineal gland undoubted calcium carbonate spherules were identified by me in considerable numbers. The bony matrix can be rarefied and its salts removed, but as far as I know there is no evidence of the absorption of calcified areas, but these, once formed, tend to persist. The main difference in the deposition of the salts in the two cases depends on the presence or absence of the osteoblasts.

The first appearance of a deposit of calcium salts in bone is in the form of very fine granules in or on the newly formed fibrous base. The granules quickly fuse to a homogeneous mass. Such a phenomenon may be interpreted either as a secretory or a precipitation process, according to the bias of the observer. In view of all the previously cited facts, I inclined to the view of a secretory origin, the bone cells being the active agent for putting these salts into the matrix.

On the other hand, in calcified areas, it follows, in view of the differences from bone mentioned previously, that Wells is correct in stating that in these cases the phenomenon is a precipitation. The soluble double salt infiltrating a necrotic area, or mass of old white fibrous tissue, enters an area low in carbon dioxid and precipitates. The fact that there are no osteoblasts here to cause removal by cellular activity and that the carbon dioxid content of these areas cannot be easily raised explains the permanence of the deposit, removal not being possible without increased solubility which requires increased carbon dioxid.

SUMMARY

1. Calcium phosphate and calcium carbonate show characteristic easily identified shapes of particles when precipitated in colloids.

2. The bone salts are not present as discrete particles in bone, and, even in rapidly growing parts, show no evidence of being deposited by simple precipitation.

3. Barillé has shown that calcium salts are transported to the bone in the form of a complex double salt, calcium carbonophosphate.

4. Evidence favors the view that the salts in bone are deposited by activity of the osteoblasts, as a secretory phenomenon.

5. The direction of travel of the calcium salts can be reversed. They can be taken from the bone to raise the blood content when it is low. There is evidence of the presence of a calcium balance between bone matrix, osteoblasts and blood similar to the carbohydrate balance between glycogen, liver cell and blood.

6. In calcification, the same salts are present as in ossification and in the same proportion. The difference is that osteoblasts are absent, and instead of a bony matrix there is an area either of fibrosis or necrosis.

7. There is evidence that calcification is a precipitation phenomenon, and in support of this view discrete characteristic spherules of calcium carbonate have been seen in a calcified pineal gland, as well as granules and irregular crystalline masses in calcified areas in the walls of arteries.

8. The presumption is that as its origin is by precipitation a calcified area is permanent and neither will it disappear nor will it show rarefying changes such as may be seen in bone.

Reprinted from the Archives of Surgery
May, 1925, Vol. 10, pp. 983-990

Copyright, 1925
American Medical Association
Five Hundred and Thirty-Five North Dearborn Street
CHICAGO

UNIVERSITY OF TORONTO STUDIES

ANATOMICAL SERIES

No. 1: The anatomy of the orang-outang, by Professor A. PRIMROSE ..... o.p.

No. 2: The skull of a human foetus of 40 mm., by CHARLES CLIFFORD MACKLIN 0.50

No. 3: Anatomy of a seven months' foetus exhibiting bilateral absence of the ulna accompanied by monodactyly, by J. C. WATT 0.50

No. 4: Symmetrical bilateral dystopia of the kidneys in a human subject, by J. C. WATT 0.25

No. 5: The terminals of the human bronchiole, by HERBERT G. WILLSON 0.50

No. 6: The behaviour of calcium phosphate and calcium carbonate (bone salts) precipitated in various media, with applications to bone formation, by JAMES CRAWFORD WATT 0.50

No. 7: The deposition of calcium phosphate and calcium carbonate in bone and in areas of calcification, by JAMES CRAWFORD WATT 0.50

UNIVERSITY OF TORONTO STUDIES

ANATOMICAL SERIES

UNIVERSITY OF CALIFORNIA
DEC 7 1939
LIBRARY

No. 8: A HUMAN EMBRYO OF THREE PAIRS OF SOMITES. By W. H. Piersol

THE UNIVERSITY OF TORONTO PRESS
1939

University of Toronto

PRINTING AND PUBLICATIONS COMMITTEE

Chairman:

THE HON. THE REV. H. J. CODY, M.A., D.D., LL.D.,
President of the University

PROFESSOR G. S. BRETT, M.A.

PROFESSOR M. A. BUCHANAN, PH.D.

PROFESSOR E. F. BURTON, PH.D.

W. J. DUNLOP, B.PAED.

C. E. HIGGINBOTTOM

PROFESSOR H. A. INNIS, PH.D.

PROFESSOR F. C. A. JEANNERET, B.A., D. ÈS L.

PROFESSOR M. W. WALLACE, PH.D., LL.D.

W. S. WALLACE, M.A., *Hon. Advisory Editor*

PROFESSOR C. R. YOUNG, C.E.

A. GORDON BURNS, B.A., *Manager of the University of Toronto Press and Secretary of the Committee.*

Sub-Committee on Studies:

W. S. WALLACE, M.A., *Chairman*

PROFESSOR E. F. BURTON, PH.D.

W. J. DUNLOP, B.PAED.

A. GORDON BURNS, B.A., *Secretary*

General Editor:

MISS ALISON EWART, M.A.

University of Toronto Studies
Anatomical Series, No. 8

A HUMAN EMBRYO OF THREE PAIRS OF SOMITES

By
W. H. PIERSOL

TORONTO
THE UNIVERSITY OF TORONTO PRESS
1939

LONDON:
HUMPHREY MILFORD
OXFORD UNIVERSITY PRESS

COPYRIGHT, CANADA, 1939
PRINTED IN CANADA

A HUMAN EMBRYO OF THREE PAIRS OF SOMITES

The Ovum and its Technical Preparation

This specimen was obtained at the post-mortem examination of a Chinese woman, aged 26 years, who had been admitted in a moribund condition to the Tung Wah Chinese Hospital, Hong Kong. Death was due to streptococcic pneumonia.

Because the uterus was congested and slightly enlarged it was placed in ten per cent formalin and some hours later was brought to the attention of Dr. A. V. Greaves, pathologist of the hospital. Opening the uterus a rounded swollen area of mucous membrane was evident and a block of tissue including this and the underlying muscular coat was removed. The block was then passed through Kaiserling's fluid I into ninety-five per cent alcohol and later into Kaiserling's fluid II in which it remained, until Dr. Greaves, passing through Toronto, donated it to this laboratory. At some stage after the initial preservation a portion of the block had been sliced away opening the chorionic cavity but not touching the body stalk or its attached vesicles.

Inspection of that surface of the block which included the window into the chorionic cavity showed considerable separation of the chorion and its villi from the decidua basalis and decidua capsularis. Firm attachment was chiefly to the decidua marginalis of one side. Sections show some portions of villi attached to the deciduae but torn away from the chorion by shrinkage. The interior of the chorion seemed void of magma and its inner surface was smooth and even except for some low, rounded irregularities of the basal chorionic wall. On sectioning, these proved to be the body stalk and yolk sac, the amnion with the contained embryonic shield lying between yolk sac and chorion. Evidently pressure from some source had flattened the vesicles. Sections show also that the base of the body stalk is partly torn away from the chorion and that the right side of the embryonic shield is slightly indented just posterior to its middle.

The block was sectioned in paraffin, the plane of the sections being parallel to the elevations noted in the chorionic cavity and perpendicular to the wall of the uterus. Fortunately this yielded almost truly sagittal sections. The majority of the sections were

alternately thicker and thinner than the eight microns at which the microtome was set. This difference in thickness was neglected in constructing the model, for the combined thickness of any two consecutive sections is sixteen microns. The sections involving the vesicles and parts adjacent were mounted serially, the remainder singly, for class use, but have been studied for points upon which

FIGURE 1.—The embryonic vesicle and the deciduae in situ upon the muscular coat of the uterus. Sagittal section of the embryonic shield and adnexa. X 5.

they might have a bearing. Most of the sections were stained with Ehrlich's haematoxylin and eosin, some by Mallory's triple stain with phosphotungstic acid.

A model was constructed by the wax-plate method at an enlargement of 125 diameters. The plates were assembled in four groups to permit examination of the interior, which was further facilitated by cutting loose, in three of the groups, the roof of the amnion and the adjacent wall of the chorion. To stiffen the model each of the seven parts so obtained was coated with shellac, allowed to become almost dry, then dusted with powdered graphite and heavily

electroplated with copper. So treated even the thinnest parts retain their form in summer heat. A second similar model was made to show the mesoderm and pericardial cavity of the right side.

FIGURE 2.—Paramedial section. In the embryonic disc three somites appear in the middle of the strip of mesoderm. The pericardial cavity is to be seen near the anterior end of the strip. X 60.

A Exocaelom
B Yolk sac, flattened
C Cavity of amnion
D Wall of chorion
E Intervillar spaces, villi, trophoblastic masses
F Body stalk

The history of this embryo furnishes no menstrual or other data from which an approximate age in days might be calculated. Ranked by the number of somites formed it stands as in table I. Ingalls estimated the age of his embryo at 18-21 days and Ludwig, his embryo, at about 21 days.

The studies listed here together with several others have

established the general picture of human development at the time the first few somites are forming. Only exceptionally fine preservation would justify an exhaustive description and discussion of another ovum of comparable development. However, for many developmental features the limits are not established within which variations may be considered as normal. This is particularly the

TABLE I

Embryo	Described by	Pairs of somites	Length: Straight line	Length: Along surface
Da I	Ludwig 1928	2	1.8 mm.	2.4 mm.
CC 1878	Ingalls 1920	2—3	1.38	1.77
H 3	Wilson 1914	2—3	1.64	
T 439	Piersol 1939	3	1.28	2.03
H 279	Bartelmez and Evans 1926	4	1.75	2.05
A	Sternberg 1927	4	2.3	
Cs	Llorca 1934	4	1.6	2.6

Ludwig describes a somite-like arrangement of cells in the mesoderm immediately anterior to the somites of his embryo but does not consider it a true somite. In this he follows the dictum of Rabl, "Der erste Urwirbel in der Reihe ist also der älteste, vorn und hinten scharf begrenzte" (Arch. f. mikr. Anat., vol. 88, S 452). Llorca questions the correctness of this conclusion and Arey quite rejects it. Similarly this embryo, T 439, was first reported (Anat. Rec., vol. 67, Suppl. 3, p. 38) as of two pairs of somites, but the writer now follows Arey in considering the proper number to be three. The surface measurements of Ingalls' and Llorca's embryos are calculated from their figures.

case as regards the stages of development attained simultaneously by the different parts of the ovum. To the solution of such problems cases in which a known abnormal factor has been operative may contribute valuable information. In the present case this factor is development for at least two or three days at the high temperatures accompanying pneumonia in a young and previously healthy adult. This description will pass over or touch but briefly the features of this embryo—to be known as T 439—which have no special points of interest.

DECIDUAE

Decidua basalis—The deeper and middle parts of the glands retain the form of their pregravid phase (O'Leary, 1929) but the parts in the compact layer are flattened with their long axes parallel

to the chorionic wall. In proportion as the ovum is approached the glandular cells increase in size with a fine vacuolation of the cytoplasm becoming more and more evident. Some of these cells fall into the lumina where they meet with secretion and in some cases with blood.

Near the muscular coat the tunica propria closely resembles that of the non-pregnant uterus but, moving toward the ovum, an increasing proportion of the connective-tissue cells begin to enlarge and within the compact layer attain the status of decidual cells. Concurrently the stroma becomes oedematous and leucocytes are more evident. Nearing the wall of the implantation cavity small groups of blood cells appear in the tissue spaces, to be succeeded by large extravasations close to the wall or even partly between its lamellae.

Near the wall syncytial formations occur which are derived from both Grosser's implantation syncytium and his resorption syncytium. The former, if small, occur as rounded masses but tend to be irregular when large and in any case show evidences of degeneration. Frequently their nuclei are very numerous, solid, irregular, and dark staining but in more advanced stages are distended permitting the nucleoli to become prominent. The cytoplasm is pale and contains vacuoles which vary within wide limits as regards both number and size. In general these masses of syncytium present the various stages of an increasing hydration. Leucocytes have invaded some of the masses. Resorption syncytium in the form of strands rather than of masses is seen insinuating itself among the elements of the tunica propria and in the act of invading glands and veins, but not arteries. Pycnotic nuclei are numerous in these strands but degeneration is much less advanced than in the masses of implantation syncytium. As to the effect of the ovum on the surrounding tissues, it may be said that the picture is one of mutual, but not violent, injury by maternal and embryonic elements.

The larger masses of less altered tunica propria contain arteries so elaborately coiled that to label them "spiral arteries" greatly understates the condition. Veins are numerous but mostly small. Areas of endothelium have been shed from the walls of the larger veins, but the walls of the capillaries are usually intact. As in Greenhill's (1927) specimen, contact between tunica propria or syncytium and blood does not as a rule cause clotting. Teacher

(1925), however, in his younger ovum, T-B I, found clotting in some cases.

Decidua marginalis—In obtaining the specimen much of the decidua marginalis was lost from that part toward which the anterior end of the embryonic shield is directed. This is not without compensating advantage for it released the opposite side from the tensions of shrinkage and preserved there the normal relations of villi, cell columns, and mucosa.

Comparing like parts, the glands resemble those of the basal decidua except that near the ovum their long axes curve concentrically with the wall of the implantation cavity, a condition which has frequently been described.

The largest vein in this specimen occurs in this region and may be the equivalent of Teacher's sinus. A somewhat marginal position for this sinus is seen also in Greenhill's specimen.

Decidua capsularis—Measurements made on the section which coincides with the median plane of the embryonic shield give the decidua capsularis a thickness of approximately 0.5 mm. The slight local variations in this and in other sections are without significance. No operculum or other indication of the point of penetration by the ovum could be found. A similar failure in an even younger specimen was noted by Latta and Tollman (1937).

A few small losses of uterine epithelium have occurred but the greater part of it is intact. In some regions the epithelial cells are cubical, in others they are flattened; a condition which has been noted in other specimens. While numerous remnants of glands are present in the peripheral parts of the decidua capsularis, only a few glandular fragments are contained in a central region with an average diameter of 5.0 mm. The flattening noted for the epithelium extends to the nearby elements of the tunica propria but is not shown by those further from the surface although the deeper elements must have been subjected to an almost equal tension by the expanding ovum. The opposite wall of the uterus may so press upon the projecting mound formed by the ovum and decidua capsularis as to be an important factor in flattening the more exposed parts of the latter.

In general, Greenhill's description of the capsular tunica propria applies to the present specimen. However, degeneration of the decidual cells is not here so far advanced nor, compared with the

stratum compactum elsewhere, are small blood vessels markedly less numerous. There are no large blood vessels.

The wall of the implantation cavity—The thickness of the concentric layers which form this wall is highly variable; moreover a thin area in one layer need not be compensated for by increased thickness in the others. The outermost layer is composed of fibrinoid (Nitabuscher Fibrinstreifen, Grosser, 1909) derived chiefly from degenerating maternal elements including the ground substance of the tunica propria. Some fibrinoid is usually considered to be derived from degenerated implantation syncytium but no such contribution can be recognized in this specimen for, under Mallory's stain, even the syncytium which is most advanced in degeneration does not approach the clear blue of the fibrinoid.

The succeeding layer (Rorscher Fibrinstreifen, Grosser, 1909) is true fibrin of maternal origin. It closely resembles fibrinoid in colour when stained by haematoxylin and eosin, but under Mallory's stain its strong red clearly distinguishes it from fibrinoid. It is also more regularly lamellar in structure and includes many red blood corpuscles. These, however, may be present in smaller numbers in the fibrinoid.

Resorption syncytium forms the third layer and is present in much the greater part of the wall. However, the separations resulting from shrinkage have damaged it in many places and, in addition, gaps in its continuity exist where no separation has occurred. Latta and Tollman (1937) note gaps in the resorption syncytium as it covers the cell columns. There is a strong tendency, perhaps due to the rapid growth of the implantation cavity, for the syncytium of this layer to become resolved into small cell-like bodies slightly, or not at all, connected with their neighbours. In such cases the deep staining of the layer is retained and clearly distinguishes these bodies from the pale cells of the cytotrophoblast, the only elements nearby with which it might be confused. Prolongations from this layer penetrate the two outer layers of the wall and extend deeply into the tunica propria where they frequently break into elongated cell-like bodies, probably the equivalent of the "syncytial wandering cells" of Ramsey (1938).

The innermost layer of the wall is cytotrophoblast continuous with the cytotrophoblast of the cell columns. As a layer it is even less complete than the third. It is not possible to detect which gaps are natural and which have arisen through shrinkage, although

in some cases there is an obvious "fit" between the gap and the end of the cell column opposite. Cytotrophoblast is lacking near the centre of the decidua capsularis. Here, over an irregular area about 1.8 mm. in diameter, it is replaced by a few layers of leucocytes that rest on five to fifteen lamellae of fibrin between which

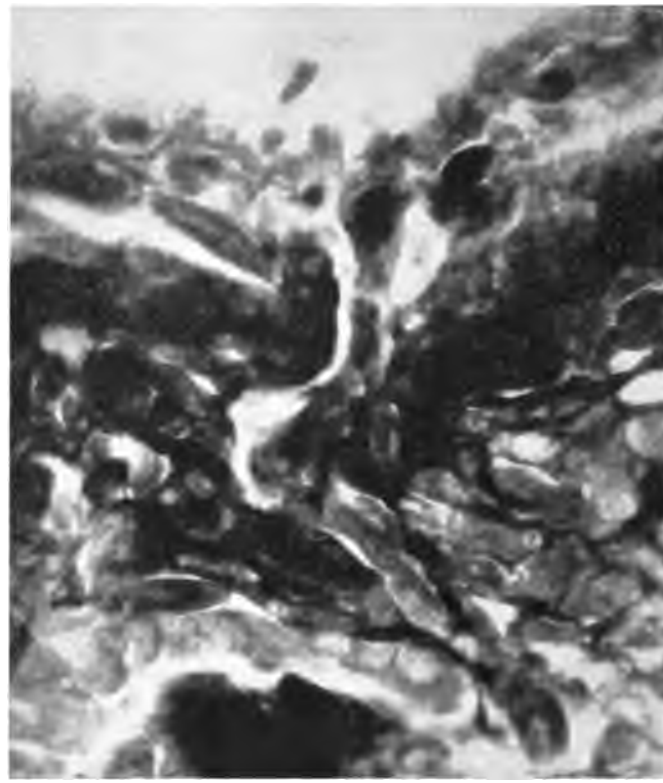

FIGURE 3.—A strand of resorption syncytium penetrating the fibrin (pale) and fibrinoid (black) layers of the wall of the implantation cavity and terminating in the adjacent tunica propria. X 800.

lie many other leucocytes. Between some of the deeper lamellae of this area are fragments of resorption syncytium. The impression given is that an exudate of maternal origin has broken up the syncytium and inserted itself between the syncytial remnants and

the cell columns. The latter, as masses of cytotrophoblast, are left clinging to the neighbouring villi which, in turn, have withdrawn from the decidua capsularis.

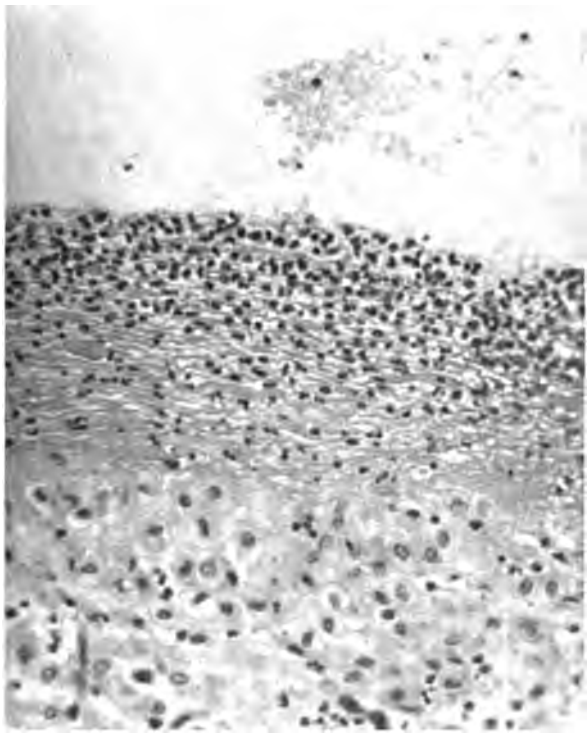

FIGURE 4.—Layers of fibrin and leucocytes replacing the usual constituents of the wall of the implantation cavity. Beneath is the tunica propria of the decidua capsularis. X 340.

CHORIONIC WALL AND VILLI

As may be seen from figure 1 no region of the chorionic wall is devoid of villi. They are shortest and least numerous under the central part of the decidua capsularis, longer and more numerous over the decidua basalis, and in the marginal region reach their maximal development in number, length, and branching. Figure 5

shows the longest and most branched of all the villi and comes from the uninjured marginal area. Many villi are unbranched.

Trophoblast—The combined thickness of resorption syncytium and cytotrophoblast varies from 0.008 to 0.015 mm. But few gaps exist in the resorption syncytium on the cell columns and villi. The typical brush border of the syncytium may usually be detected, most easily in Mallory-stained sections; but it may be lacking and

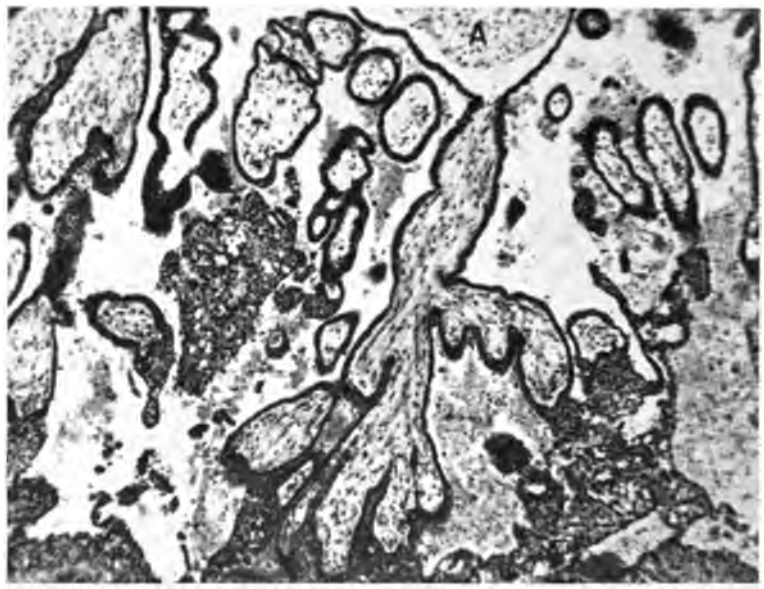

FIGURE 5.—The most highly developed villus of the specimen. Shrinkage has caused the mesoderm of the chorionic wall (A) to break away from that of the villus. Angioblastic cords are seen within the latter. Trophoblastic cell columns join the villus to the tunica propria just visible below. X 55.

in a few places on the cell columns the syncytium itself fails. Masses of syncytium with rounded outlines project from many villi and in some cases from masses of cytotrophoblast. That very little syncytium lies free in the intervillous spaces may be established by tracing suspected masses through consecutive sections. In this specimen all these syncytial masses, both loose and attached, show the evidences of degeneration that have been frequently described; their brush borders, where present at all, are coarser than on the syncytium of the villi.

The single layer of cells that forms the cytotrophoblast of the villi is usually distinct from the syncytial layer, for its cells contain larger nuclei and a scanty cytoplasm in the form of pale-staining strands that run between nucleus and a well-marked cell membrane. However, there are villi in which these distinctions fail; a condition which Greenhill found on the cell columns and interpreted as a stage in the conversion of cytotrophoblast into syncytium. The masses of cytotrophoblastic cells, whether merely attached to villi or in the form of cell columns, frequently contain cavities some of which open into the intervillous spaces and have thence received a content of maternal blood cells. Syncytium in small amounts may also penetrate into the cell masses. Degeneration of the central cells of a mass was noted by Greenhill and is quite clearly seen in this specimen. Some of the cavities so produced contain material that under Mallory's stain assumes the blue colour of fibrinoid.

It is perhaps due to the rapid expansion of the chorion that the growth of the trophoblast of its wall does not become exuberant and produce projections of cytotrophoblast and syncytium similar to those arising from the villi. Between the trophoblast of the chorionic wall and that of the villi there are no other significant differences.

Mesoderm—Shrinkage has slightly separated mesoderm and trophoblast throughout most of the chorionic wall. In thickness the mesoderm varies between 0.04 and 0.1 mm. but usually is very close to 0.06 mm. It presents its typical structure, Mallory's stain aiding greatly in distinguishing the slender processes of the cells from the delicate fibres of the intercellular spaces. Next to the trophoblast in both chorionic wall and villi these fibres form a basement membrane which is carried away from the trophoblast by shrinkage.

In a wide area surrounding the attachment of the body stalk to the chorion the mesoderm contains strands of connected cells that stain strongly—the angioblastic cords of Bremer (1914). Such pictures as his figures 9 and 10 and M'Intyre's (1926) figure 3, Plate 1 are frequent in both chorionic wall and villi. The nearer to the body stalk the more advanced is their development. Beginning distally from the body stalk the succession is solid strands, strands with a double row of nuclei, strands that show a lumen, and finally strands with blood cells in the lumen. The earlier of

these stages were found already in existence by Stieve (1926) in his embryo of 13½ days' development.

Between the amnion and the chorion and near the median plane there is a spherical body 0.075 mm. in diameter with a lumen 0.016 in diameter. The lumen is surrounded by a simple epithelium of large cubical cells. Outside the epithelium is a thin layer of delicate fibres and cells which resemble those of the chorionic mesoderm. At one side these fibres and cells form a short stalk which connects with the adjacent mesoderm of the chorionic wall. A few other projections from the chorionic mesoderm are found in the same region but none so large or so definitely formed as this small cyst. All are probably without significance.

BODY STALK, AMNION, AND YOLK SAC

The body stalk contains proportionately more cells than the chorionic mesoderm, an impression deepened by the presence of blood islands and of vessels containing numerous blood cells. The lower surface of the stalk is covered by a continuous layer of cubical mesothelial cells which, in a few situations, form funnels as described by Bremer. Most of the upper surface is covered by the cubical-celled ectoderm of the amnion, the wall of which is fused with the stalk. A small part of the upper surface near the base of the stalk is not so covered but is torn and compressed and the nature of the superficial layer is not clear. The stalk contains no trace of an amniotic duct, in this regard resembling Ludwig's embryo.

The network of blood vessels in the body stalk has meshes but little wider than are the vessels themselves. Injury and faulty preservation combine to render impossible an accurate and detailed account of the network. It may be noted, however, that longitudinal vessels of endothelium are the most conspicuous but transverse links can be detected along with slender branches extending in all directions from the base of the stalk into the wall of the chorion. Only a few villi receive branches from this network. Those which do may be known by the presence of blood cells within their vessels, while just beyond this area lie villi with empty endothelial tubes ready to be taken into the system. No vessels as yet enter the embryonic shield or communicate with the blood islands of the yolk sac.

Magma containing a few blood cells, evidently escaped from injured vessels, is seen in the tear at the base of the stalk and along its lower surface.

Amnion—Pressure from below has driven the roof of the amnion against the chorion. A consequent lengthening of the transverse and antero-posterior diameters of the amniotic cavity might be expected but cannot be more than slight for these diameters are but 0.03 mm. and 0.17 mm. respectively greater than those of the shield itself.

The structure of the wall of the amnion is most clear where the amnion is not in contact with the chorion. At such places the wall consists of an inner epithelium of cubical cells and an outer mesothelium the cells of which vary from flat to cubical. The flat cells predominate in all the more central parts of the membrane but with patches of cubical cells interspersed. Moving away from the centre the proportion of cubical cells increases until at last all are cubical. A few isolated mesodermal cells lie between these inner and outer layers and constitute the only equivalent of mesenchyme.

Anteriorly there is an abrupt transition from the cubical-celled mesothelium of the amnion to the flat-celled mesothelium of the yolk sac. Posteriorly where the amnion covers the body stalk the mesothelium along the line of fusion rapidly becomes irregular and breaks into groups of cells which put out processes and thus eventually blend with the mesenchyme of the stalk.

The *yolk sac* has been stretched and ruptured anteriorly, probably by the increased internal pressure when the sac was flattened. In the less injured parts of the wall of the sac inner endodermal and outer mesothelial layers, mostly of flat cells, are easily recognized and between them numerous blood islands with endothelial walls. Many islands have been broken into and their blood cells lie within the cavity of the yolk sac and, in smaller numbers, outside as well. Toward its posterior parts the wall becomes stouter, blood islands cease, and the flattened cells give way to cells of cubical form.

THE EMBRYONIC SHIELD

The following measurements were made from the sections or calculated from the model.

Length antero-posteriorly, in a straight line, 1.28 mm., following the curved surface, 2.03 mm.

Greatest transverse diameter, in a straight line, 0.64 mm. following the curved surface, 0.72 mm.

The greatest length of the amniotic cavity being only 1.45 mm. and its width 0.75 mm. it is obvious that much of the curvature of the embryo is natural, a conclusion quite in agreement with the form of many other embryos (cf. Ingalls, Fig. 1) of approximately the same stage of development. Measurements of the flattened yolk sac have no value. It is probable that some amount of flattening pressure was exerted on the neural plate for the neural groove, so deep in many embryos, is everywhere shallow.

FIGURE 6.—The model viewed from above. The chorion and part of the body stalk are shown in black. Stumps of villi appear on the model but do not show in the figure. The chorion and roof of the amnion have been cut away over the remainder of the model along with the left half of the body stalk. The neural plate (white) is bordered by the cut edge of the amnion (A). An indentation of the right side of the neural plate affects also the amnion between which and the chorion may be seen a small part of the yolk sac. A much larger area of yolk sac is seen at B. X 5/16.

Ectoderm—Neither the gross form of the neural plate nor its cellular detail are sufficiently well preserved to yield information as to the neuromeres or the grouping of cells within it. However, the three to five cell layers mentioned by Sternberg are clearly present in the more anterior parts of the plate; a smaller number, two or three layers, characterizes the posterior part. Nuclei larger than the average and containing one or two nucleoli are to be seen in the lower layers of the plate and indicate the positions of neuroblasts. The ectoderm which lies just beyond the margins of the plate consists of a single layer of columnar cells, while at the margins of the shield the cells are cubical in form.

The *endoderm* consists of a single layer of cells directly continuous with the sides of the notochordal plate. Beneath the

somites and in the regions posterior and lateral to them the endodermal cells are flattened. Anterior to the somites, and especially in the region where the foregut will soon take shape, the cells are cubical or even columnar. Sternberg notes a similar change as the endoderm enters this region. In the median plane at points just dorsal to the pericardial cavity there is in two sections a marked projection of endodermal cells forward toward the ectoderm which, however, is not quite reached. Sternberg describes an even closer approach at this spot and interprets it as the pharyngeal membrane.

In the median plane the anterior wall of the foregut is indicated by a vertical portion of the sheet of endoderm but folding has not as yet produced any part of the ventral wall; neither is there any indication of side folds. In contrast to this the posterior part of the gut is completed to a length of 0.18 mm. and contains on its posterior wall the primitive knot, the cloacal membrane, and the opening of the allantois.

NOTOCHORDAL PLATE, PRIMITIVE KNOT, AND ALLANTOIS

The *notochordal plate* is formed of a single and compact layer of columnar cells and has a breadth of 0.056 mm. narrowing to 0.048 mm. anteriorly and posteriorly. Its anterior quarter is bent slightly to the left—0.048 mm. at its extreme end—and its posterior fifteenth an equal amount, hence more sharply, also to the left. Its entire length measured along its curves is 1.6 mm. The plate is set in the sheet of endoderm which nowhere extends beneath its ventral surface except at its extreme anterior end. Here the tip of the plate is fused with the mesoderm of the prechordal plate as described by Hill and Florian (1931), but differs from their description in being also in continuity with the endoderm. Some cells of the endoderm extend backward beneath the plate for a distance of 0.05 mm. but in this situation they cannot be considered as part of the ventral wall of a notochordal canal.

Situated well dorsally on the posterior wall of the gut is a small area in which the ectoderm and endoderm meet and blend. As well as can be determined from sagittal sections the mesoderm also joins this group of indifferent cells and strengthens the impression that it is the *primitive knot.* Although the ectoderm is indented at this spot, and to a less extent the endoderm also, there is no lumen present to represent the notochordal canal.

The *cloacal membrane* lies somewhat ventral to the primitive knot and is larger in area. Minor contacts between the ectoderm of the amniotic wall and the endoderm of the allantois are described by Sternberg and Llorca and are interpreted by them as relics of

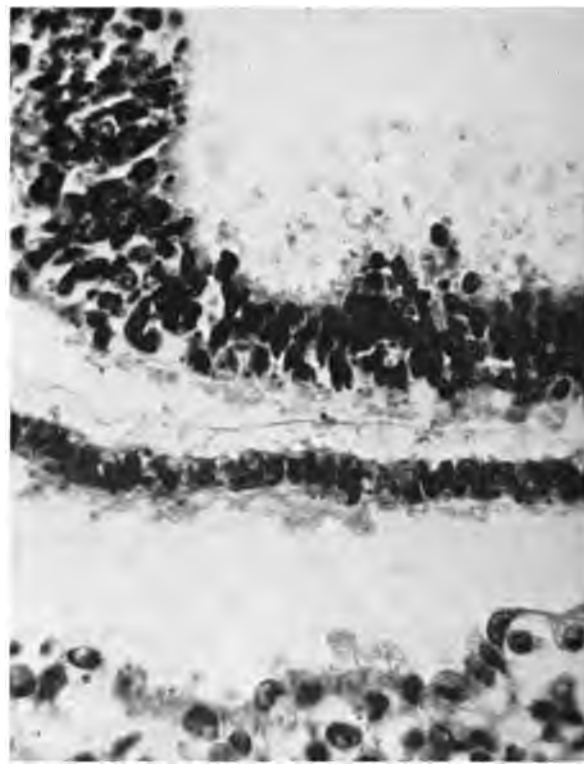

FIGURE 7.—A portion of the notochordal plate in sagittal section. The neural plate, bent at a right angle, lies above it. The lower wall of the yolk sac has been pressed upward so far as to appear at the bottom of the figure. X 750.

an originally more extended cloacal membrane. Such contacts do not occur in this specimen.

The primitive knot, the cloacal membrane, and still more ventrally, the opening of the allantois do not lie in the median plane of most of the embryonic shield. The first mentioned appears in the third and fourth sections to the left of the plane, the second in the fourth to eighth sections to the right of the plane, and the third

still farther to the right in the nineteenth and twentieth sections. Since the primitive knot lies in a horizontal plane 0.175 mm. above the allantoic opening and in a vertical plane 0.192 mm. to the left of it, the distance between the two structures is 0.26 mm., very nearly the same as may be calculated for Sternberg's embryo from his figure 29.

The *allantois* is divided into three parts, each containing a lumen. Including the gaps between the main part and the two vesicles

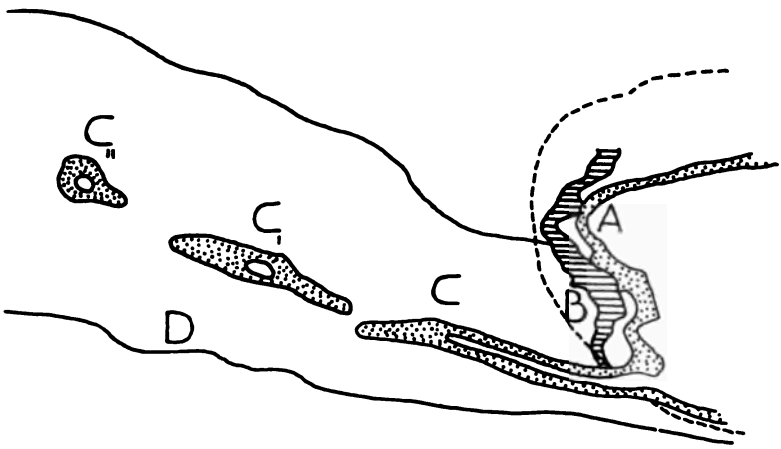

FIGURE 8.—Graphic reconstruction of the body stalk and the posterior end of the embryo as seen from above. The ectoderm (lined) is shown in contact with the endoderm (dotted) at the primitive knot (A) and the cloacal membrane (B). The broken line marks the margin of the shield; its distance from the ectoderm indicates the extent of the tail fold. Allantois (C) and its vesicles (C_I, C_{II}). Body stalk (D). X 120 (approximately).

which have obviously been abstricted from its distal end its total length is 0.75 mm. Sternberg notices the great variations in length of the allantois in embryos of approximately the stage of development of this specimen. The range is from the allantois—1.25 mm.—of Ingalls' embryo through that of Sternberg's own embryo, 0.875 mm. and the present case, to that of Ludwig, 0.27 mm. The latter, however, has a puckered outline and is much expanded at its distal end. Llorca's embryo, for which an allantoic length of 0.26 mm. may be calculated from his figure 3, is in the same class.

So many of the sections are almost tangential to the allantois

that it is impossible to speak for the structure of all parts of its epithelium but where the picture is clear the cells are columnar and are arranged in a single layer. Unlike the condition described by Sternberg there is no contact between the epithelium of the allantois and that of the amnion. In this T 439 resembles Ingalls' embryo but differs from the latter in being also without contact between the allantois and the mesothelium of the body stalk.

As noted by Martin (1937) in the Falkiner ovum and again by Ramsey in the Yale ovum the allantois may arise from the wall of the yolk sac previous to the delimitation of the body stalk in which is it finally incorporated. The movement suggests a process akin to the "regulation" of the experimental zoologist. This may account for the somewhat lateral position which the allantois may occupy during the course of its development. However, the relative position of primitive knot, cloacal membrane, and allantois in the present specimen suggests an artificial displacement toward the right and increasing ventrally. Artificial displacement is also suggested by Wilson's description and figures of the embryo H 3 and may play a part in other cases of unsymmetrical allantois. For instance, in the ovum described by Thompson and Brash (1924) the entire allantois along with the greater part of both yolk sac and body stalk lie to the right of the median plane of the embryonic shield. Displacement, however, has played no part in the separation of the vesicles from the main part of the allantois; for there is no evidence in the structure of either the epithelium of the vesicles or of the surrounding mesoderm that unnatural tensions have been operating.

Germ cells as described and figured by Politzer (1933) are seen in the endoderm which surrounds the opening of the allantois. Their larger size and more lightly stained cytoplasm identify them among the ordinary endodermal cells, but equally characteristic is their ability to compel the surrounding cells to make the necessary adjustments of form and leave the germ cells well rounded. Nine such cells are clearly recognizable. Defective preservation of cellular detail permits varying degrees of doubt regarding several others so that an accurate count is impossible.

MESODERM AND CAELOM

Toward the margins of the embryonic shield a bilaminar structure of the *mesoderm* obtains and includes small isolated spaces as

described by Ludwig. At no place is there open communication between the caelom and the exocaelom. Toward the median plane the bilaminar appearance is lost and the mesoderm thickens. To mark the line of the somite stalks a region of thinning might next be expected but cannot be found, perhaps because of the sagittal plane of the sections. Where best expressed the virtual somatic and splanchnic layers are each formed of a single layer of cells, but at the edge of the embryonic shield the distinction between the layers is lost and the mesoderm thickens. Within the shield the distinction made by Rosenbeck (1923) between compact gastral and looser primary mesoderm cannot be detected. Neither can boundaries be assigned to the mesoderm derived from the prechordal plate, nor can a contribution from the ectoderm be confirmed. Anteriorly the sheet of mesoderm is perforated to permit the approach of endoderm to ectoderm as already noted. Posteriorly there is a pair of perforations, one at the site of the primitive knot, the other at the cloacal membrane. The latter is the larger and has a definite edge while at the primitive knot the mesoderm is continuous with the group of cells in which all three germ layers blend.

Somites—Arey (1938) has summarized the most important features of the first pair of somites of this embryo, viz.: the somites are well differentiated; the left is equal in size to the second somite, the right is somewhat smaller; the left is broadly connected to the unsegmented mesoderm anterior to it, the right is partly separated by a shallow groove; the right contains a small central cavity but the left does not.

In addition it may be noted that the somites all show a few cells in their centres. The surrounding cells tend toward a radial arrangement which is most clearly expressed in the second pair. At their ventral edges the somites of the second pair connect anteriorly and posteriorly with the neighbouring somites by a short bridge of mesoderm one or two cells in thickness. The somites of the third pair are even more stoutly connected with the unsegmented mesoderm posterior to them.

The *caelom* extends no further posteriorly than the anterior part of the first somite and in consequence is to be considered as essentially the pleuro-pericardial cavity. It has the usual horseshoe form of its early condition but the transverse bar lies in a more anterior position than in other embryos of comparable stage of

development. There being as yet no ventral wall to the foregut the future posterior border of the cavity is now its most anterior part and extends into the pericardial plate of Wilson. This plate, however, is not yet bent under but extends anteriorly beyond the margin of the embryonic shield. This position might be considered

FIGURE 9.—Sagittal section of the anterior end of the embryonic shield near the median plane. X 250.

A Pericardial cavity
B Amniotic cavity
C Cavity of the yolk sac
D Wall of the chorion

as due to the same pressure which has driven the adjacent wall of the yolk sac even more anteriorly and upward. However, while the dislocation of the yolk sac is obvious, the appearance of the adjacent walls of the amnion and pericardial cavity does not convey the impression of much interference. A number of delicate cellular and protoplasmic strands cross between the two walls of the pericardial cavity; relics of the earlier contact of the walls they can hardly have survived much violence. The stage of development

reached by this region is much less advanced than that figured in Ingalls' Plate 2 or Ludwig's figure 1. It is plain that an attempt to force the parts in question as shown in these figures into the positions they occupy in this embryo would cause disturbances which are absent, such as folds in the walls of the amnion and the pericardial cavity. The pericardium as shown in Ludwig's figure 2 will almost represent also the pericardium of this embryo but it must be shifted anteriorly for the transverse part lies altogether in front of the notochord and is but slightly overlapped by the neural plate. The narrowing of the transverse part of the pleuro-pericardial cavity and the presence of small outlying cavities are alike in both embryos. As yet no indication exists of the future pericardial recesses.

The wall of the pleuro-pericardial cavity consists of a single layer of mesothelial cells except at its edges where it joins the general mesodermic sheet. In the present position of the pericardial portion of the cavity the somatic wall is uppermost and is formed of flat cells while the cells of the myoepicardial wall are cubical. Passing from the transverse part of the cavity backward along its lateral limbs the cells of the somatic wall first become cubical and then are arranged in more than one layer. Concurrently the splanchnic wall thickens into two or three layers of cells. Where the walls meet at the outer boundary of the caelom the mesoderm is rapidly reduced to the two single-celled layers already mentioned as forming the mesoderm near the margin of the embryonic shield.

VASCULAR ANLAGEN

Beneath the pleuro-peritoneal cavity lie the anlagen of the heart and the vitelline veins while the anlagen of the dorsal aortae lie nearer the median plane beneath the somites and their anterior continuation of mesoderm. The cells of these anlagen have formed very few vesicles and no long tubes. Here and there angioblastic cords have been produced similar to those of the chorion but the great majority of the cells lie in small flat groups between mesoderm and endoderm but not in contact with either except by cytoplasmic threads. The aortic and cardio-vitelline bands of cells as described and figured by Watson (1924) for the cat can be recognized but the intervening space is not entirely devoid of cells.

Organization of the aortic band of cells into angioblastic cords

is most advanced anteriorly. On both sides a short distance anterior to the first somite a vesicle with definite endothelial wall can be traced through two sections. In the cardio-vitelline vein band the organization is most advanced under the posterior parts of the pleuro-pericardial horseshoe where, on the right side, two of the cords show an expansion with lumen. The foregoing is clear and is in general agreement with Watson's description of early vasculogenesis in the shield of the cat. Unfortunately the cytoplasmic preservation of the angioblastic cells is so poor that no further definite statements should be made.

CONCLUSION

Regarding this embryo as a whole and comparing it with other embryos of approximately the same number of somites, in spite of any fault of preservation, sufficient evidence is clear to establish a comparative retardation of development in the more anterior parts of the embryonic shield, namely, the foregut, the pleuro-pericardial portion of the caelom, the heart and associated vessels. Whether this is within the range of normal development can scarcely be decided, descriptions of human embryos of comparable age being so few. Embryos, of corresponding age, from mammals in which fever had been artificially produced during the last few days of development might throw some light on the question.

SUMMARY

The embryo—T 439—was obtained at a routine post-mortem examination and is in a fair state of preservation.

Three pairs of somites are well developed indicating an age of approximately 20 days.

The deciduae accord in general with descriptions of deciduae given by other investigators.

No operculum was found in the decidua capsularis.

The embryonic membranes present no major variations.

Blood vessels with walls of endothelium only are present in the body stalk and adjoining chorion. They do not extend into the embryonic shield or connect with the blood islands of the yolk sac.

Development in the embryonic shield anterior to the somites is comparatively retarded, foregut, caelom, heart and blood vessels being seriously affected.

The question is raised as to the effect of a few days' development at the heightened temperature of a pneumonia.

LITERATURE CITED

AREY, L. B. 1938 The history of the first somite in human embryos. Carnegie Inst. Wash., Contr. Embr., vol. 27, pp. 235-270.

BARTELMEZ, G. W. and H. M. EVANS 1926 Development of the human embryo during the period of somite formation, including embryos with 2 to 16 pairs of somites. Carnegie Inst. Wash., Contr. Embr., vol. 17, pp. 1-67.

BREMER, J. L. 1914 The earliest blood vessels in man. Am. J. Anat., vol. 16, pp. 447-475.

GREENHILL, J. P. 1927 A young human ovum in situ. Am. J. Anat., vol. 40, pp. 315-354.

GROSSER, O. 1909 Vergleichende Anatomie und Entwicklungsgeschichte der Eihäute und der Placenta. Braumüller, Wien und Leipzig.

——— 1922 Zur Kenntnis der Trophoblastschale bei jungen menschlichen Eiern. Zeitschr. f. Anat. u. Entwickl., Bd. 66, S. 177-198.

HILL, J. P. and J. FLORIAN 1931 The development of head-process and prochordal plate in man. J. Anat., vol. 65, pp. 242-246.

INGALLS, N. W. 1920 A human embryo at the beginning of segmentation with special reference to the vascular system. Carnegie Inst. Wash., Contr. Embr., vol. 11, pp. 61-90.

LATTA, J. S. and J. P. TOLLMAN 1937 An early stage of human implantation. Anat. Rec., vol. 69, pp. 443-456.

LLORCA, F. O. 1934 Beschreibung eines menschlichen Embryo mit 4 Urwirbelpaaren. Zeitschr. f. Anat. u. Entwickl., Bd. 103, S. 765-792.

LUDWIG, E. 1928 Uber ein operative gewonnenen menschlichen Embryo mit einem Ursegmente. Morph. Jahrb., Bd. 59, S. 41-104.

MARTIN, C. P. 1937 The Falkiner ovum. Anat. Rec., vol. 67, Suppl. 3, p. 34.

M'INTYRE, D. 1926 The development of the vascular system in the human embryo prior to the establishment of the heart. Trans. Roy. Soc. Edinb., vol. 55, pp. 77-113.

O'LEARY, J. L. 1929 Form changes in the human uterine gland during the human menstrual cycle and in early pregnancy. Am. J. Anat., vol. 43, pp. 289-346.

POLITZER, G. 1933 Die Keimbahn des Menschen. Zeitschr. f. Anat. u. Entwickl., Bd. 100, S. 331-361.

RABL, C. 1915 Edouard van Beneden und der gegenwärtige Stand der wichtigste von ihm behandelten Probleme. Arch. f. mikr. Anat., Bd. 88.

RAMSEY, E. M. 1938 The Yale embryo. Carnegie Inst. Wash., Contr. Embr., vol. 27, pp. 67-85.

ROSENBECK, H. 1923 Ein junges menschliches Ei. Zeitschr. f. Anat. u. Entwickl., Bd. 68, S. 325-384.

STERNBERG, H. 1927 Beschreibung eines menschlichen Embryos mit vier Ursegmentenpaaren. Zeitschr. f. Anat. u. Entwickl., Bd. 82, S. 142-240.

STIEVE, H. 1926 Ein 13½ Tage altes, in der Gebärmutter erhaltenes und durch Eingriff gewonnenes menschliches Ei. Zeitschr. f. mikr. anat. Forsch., Bd. 7, S. 295-402.

TEACHER, J. H. On the implantation of the human ovum and the early development of the trophoblast. Zeitschr. f. Anat. u. Entwickl., Bd. 76, S. 360-385.

THOMPSON, P. and J. C. BRASH 1924 A human embryo with head-process and commencing archenteric canal. J. Anat., vol. 58, pp. 1-20.

WATSON, K. M. 1924 The origin of the heart and blood vessels in *Felis domestica*. J. Anat., vol. 58, pp. 105-133.

WILSON, J. T. 1914 Observations upon young human embryos. J. Anat., vol. 48, pp. 315-351.

UNIVERSITY OF TORONTO STUDIES

ANATOMICAL SERIES

No. 1: The anatomy of the orang-outang, by Professor A. PRIMROSE ..... o.p.

No. 2: The skull of a human foetus of 40 mm., by CHARLES CLIFFORD MACKLIN 0.50

No. 3: Anatomy of a seven months' foetus exhibiting bilateral absence of the ulna accompanied by monodactyly, by J. C. WATT 0.50

No. 4: Symmetrical bilateral dystopia of the kidneys in a human subject, by J. C. WATT 0.25

No. 5: The terminals of the human bronchiole, by HERBERT G. WILLSON 0.50

No. 6: The behaviour of salcium phosphate and calcium carbonate (bone salts) precipitated in various media, with applications to bone formation, by JAMES CRAWFORD WATT 0.50

No. 7: The deposition of calcium phosphate and calcium carbonate in bone and in areas of calcification, by JAMES CRAWFORD WATT 0.50

No. 8: A human embryo of three pairs of somites, by W. H. PIERSOL 0.75

RETURN TO → NATURAL RESOURCES LIBRARY
40 Gianinni Hall Tel. No. 642-4493

LOAN PERIOD 7 DAYS	1	2	3
4		5	6

ALL BOOKS MAY BE RECALLED AFTER 7 DAYS

DUE AS STAMPED BELOW

JAN 02 1992

UNIVERSITY OF CALIFORNIA, BERKELEY
FORM NO. DD0, 50m, 1/82 BERKELEY, CA 94720

UNIVERSITY OF CALIFORNIA, BERKELEY
FORM NO. DD4 BERKELEY, CA 94720

U.C. BERKELEY LIBRARIES
C020525782

M211330
QL801
T6
ucl 1-S
Biology
Library
THE UNIVERSITY OF CALIFORNIA LIBRARY